

Non Spontaneous Cerebrospinal Fluid Rhinorrhoea and Subsequent Bacterial Meningitis: A Case Report

G VAISHNADEVI¹, DAYANANDAN YOGANANDAN²

ABSTRACT

Cerebrospinal Fluid (CSF) protects brain and maintains intracranial pressure which is secreted by choroid plexus. After severe Craniomaxillofacial (CMF) trauma, disruption of meningeal structure leads to CSF leak. About 80-90% of CSF leak in adults is due to head injuries. CSF rhinorrhoea can be classified into spontaneous and non spontaneous. Meningitis is seen in 19% of persistent CSF leakage with 10% of mortality due to delayed and longer duration of the CSF leakage. Post-traumatic CSF leaks are commonly seen in 1-3% of adults among all head injuries. Traumatic CSF leak is reported to be approximately 10-30% of the skull base fractures in adults. Common pathogens of meningitis are *Haemophilus influenzae* (*H. influenzae*) and *Streptococcus pneumoniae* (*S. pneumoniae*). Present case was of non spontaneous CSF rhinorrhoea and subsequent bacterial meningitis in a 33-year-old male patient, with fever and chills, headache, vomiting, neck stiffness. Kernig sign's was present. Patient had past history of road traffic accident and found to have CMF injury. Neurosurgery opinion was sought and found to be persistent CSF rhinorrhoea. Haematological and chemical analysis of cerebrospinal fluid was abnormal. CSF and blood sample sent for culture and sensitivity. *H. influenzae* grown in both culture. *H. influenzae* is an uncommon cause of adult bacterial meningitis.

Keywords: Bacterial infections, Craniomaxillofacial trauma, *Haemophilus influenzae*

CASE REPORT

A 33-year-old male presented in Medicine Department with fever, headache, neck stiffness for one day. Fever was moderate grade (38.9°C), on and off with chills, headache confined to occipital region, throbbing type and continuous. History of vomiting present with one episode, non projectile, non bilious. No history of giddiness, blurring vision, seizures, loss of consciousness, chest pain, palpitation, cough with expectoration and breathlessness. Otorhinolaryngology opinion obtained for ethmoidal polyposis.

Past history of road traffic accident had face, scalp, head injury five years back, he was treated conservatively. One year after he underwent surgery for depressed compound frontal and skull base fracture (Elevation of frontal depressed communitated fracture with Open Reduction and Internal Fixation (ORIF) and duroplasty). Three years later, he had one episode of right nasal watery discharge following lifting heavy load on head. Conservative treatment was given such as bed rest with head end elevation and advice to avoid doing heavy work. After three months from the episode of right nasal watery discharge, he presented to Medicine Department.

On day of admission, neurosurgery opinion was sought and found to be persistent CSF rhinorrhoea. The patient was advised for a repeat surgical repair of persistent CSF leak but he refuse the surgical management. Lumbar puncture was done and CSF sent for culture and sensitivity. Blood sample was also sent for culture and antibiotic susceptibility testing. On examination the patient was conscious, oriented and febrile. Neck stiffness was present with no neurological deficit. Other systematic examination were normal. Blood reports revealed normal renal function test, liver function test, coagulation profile. Electrocardiogram (ECG) and X-ray study were normal. Computed Tomography (CT) brain revealed no evidence of haemorrhage. Urine culture and sensitivity, malarial antigen, dengue NS1/IgM test were negative. Microscopy of CSF from a lumbar puncture showed increased White Cell Count (WCC) of 14,900/mm³ with polymorphonuclear cell predominance (Neutrophils 86%), low glucose (7 mg/dL), high protein (550 mg/dL), suggestive of bacterial aetiology. *H. influenzae* grown in blood culture and the same isolated in CSF culture. Chocolate agar grew translucent colonies [Table/Fig-1]. Satellitism was demonstrated in blood agar

[Table/Fig-2]. X and V factor test was done on nutrient agar showed growth around X+V factor suggestive *H. influenzae* [Table/Fig-3].

Antibiotic susceptibility test was performed by Kirby-Bauer disk diffusion on blood culture showed organism sensitive to ciprofloxacin [1], azithromycin, ceftriaxone, levofloxacin, piperacillin/tazobactam and resistant to amoxicillin-clavulanic acid, ampicillin [Table/Fig-4,5]. Diagnosis of bacterial meningitis caused by *H. influenzae* was confirmed. He was started on IV inj. ceftriaxone for 14 days, IV inj. pantoprazole and tab levocetizine if needed. After three days diagnostic nasal endoscopy procedure was done and symptomatic, supportive management was advised for ethmoidal polyposis. On discharge patient was symptomatically better. Vitals were stable and laboratory reports were within normal values. Patient was advice to take tab paracetamol, tab levocetizine, tab pantoprazole,

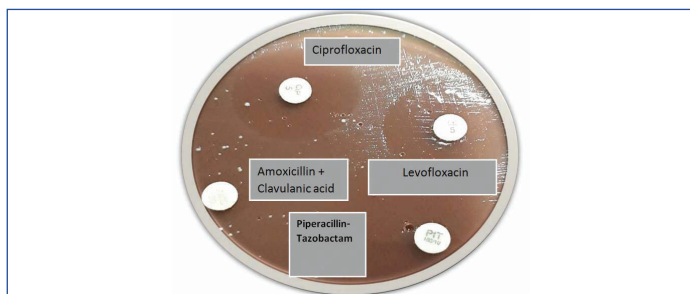


[Table/Fig-1]: Chocolate agar showing grey large, round, smooth, convex, opaque colonies. **[Table/Fig-2]:** Blood agar demonstrated "Satellitism". (Images from left to right)



[Table/Fig-3]: Nutrient agar showed *Haemophilus* has only grown around the paper disc impregnated with X and V factor. **[Table/Fig-4]:** Antimicrobial susceptibility testing- azithromycin (15 µg), ampicillin (10 µg), ceftriaxone (30 µg). (Images from left to right)

tab amoxycylav, tab azelastine+fluticasone following the recurrence of symptoms. Further follow-up was advised after one month but patient did not come for further follow-up yet.



[Table/Fig-5]: Antimicrobial susceptibility testing- ciprofloxacin (5 µg), amoxicillin-clavulanic acid (20/10 µg), levofloxacin (5 µg), piperacillin-tazobactam (100/10 µg).

DISCUSSION

The CSF is a physiologic fluid with total volume of 140 mL are turned over daily and actively circulated [2]. CSF rhinorrhoea can be classified into spontaneous (non traumatic) or non spontaneous (traumatic). Spontaneous causes include congenital anatomical defects to the temporal bone, skull base, or dura mater. Non spontaneous causes include surgical and accidental trauma, tumour, or exposure to radiation therapy involving the base of the skull [3]. CSF that surrounds the brain and spinal cord and it leak or escape from the cavities within the brain or central canal in the spinal cord. A CSF rhinorrhoea occurs when there is an opening between the dura and the skull base and leakage of CSF through the nose [4]. CSF leak from the nasal cavity is important because of the increased risk of infection which could lead to fulminant meningitis and other complications [5].

The CSF rhinorrhoea is associated with about a 10% risk of developing meningitis [6]. CSF leak is commonly seen in anterior skull base fractures. Skull base fractures increase the risk of meningitis because of the ascending infection of bacteria from the nasopharynx enter directly into the central nervous system. CSF rhinorrhoea is seen in up to 45% of patients with skull base fractures. CSF should be sent for culture in persistent CSF leak to guide antibiotic therapy and patients should be start on empirical antibiotic therapy until culture results are available [7]. In present case, patient had a depressed compound frontal and skull base fracture that was initially managed conservatively and one year later he underwent surgical repair. On day of admission he was treated with empirical antibiotic therapy. Traumatic CSF rhinorrhoea upto 85% resolved spontaneously with observation and conservative management. Persistent CSF leak later after trauma were managed surgically or placement of lumbar drain. Immediate surgical repair is advised to reduce the risk of infection by using advanced endoscopic procedures and high success rates are reported for traumatic CSF leaks [8]. About 51 patients were reviewed retrospectively with traumatic CSF rhinorrhoea and reported that 16% of them developed occult CSF leaks and finally presented with meningitis an average of 6.5 years after trauma [9]. In present case, patient presented with CSF rhinorrhoea five years after a traumatic head injury. He presented with complications such as meningitis associated with the injury and a recurrent CSF leak. In few studies,

the development of intracranial complications such as meningitis are not recognised in recurrent or persistent CSF rhinorrhoea [9-11].

The aetiology for delayed CSF leaks is not well understood. Small dural tear after trauma may heal spontaneously. It was found that persistent line of fracture along the base of skull may not heal because this fracture are rarely corrected by surgery. Meningitis or local inflammation helps to heal minor dural defect, but after many years weakening of the site and thus increase the risk for delayed leaks which occur due to scar atrophy and surrounding bone changes. A case report by Leung GK et al., showed that the patient had delayed CSF rhinorrhoea nine years after blunt head injury [12]. Increased risk for delayed CSF rhinorrhoea caused by previous skull base fracture associated with predisposing factors that elevate intracranial pressure which includes sneezing, coughing and straining [13].

CONCLUSION(S)

Post-traumatic CSF rhinorrhoea resolve spontaneously without intervention, but conservative management may lead to bacterial meningitis and other complications. Some fractures and/or leak sites may need to be surgically repaired to prevent ascending meningitis. A thorough history, clinical and endoscopic examination, other appropriate investigations, effective management are necessary to confirm the early diagnosis, treatment outcome and prevent the life-threatening complications. A less invasive transnasal endoscopic procedure has become the gold standard approach for CSF closure of less than 3 cm. Patients with previous history of traumatic skull base injury at present with symptoms consistent with a CSF rhinorrhoea should be thoroughly evaluated for this intracranial complications and a careful postoperative surveillance, follow-up is needed.

REFERENCES

- [1] Wayne PA. Clinical and Laboratory Standards Institute: Performance standards for antimicrobial susceptibility testing: 20th informational supplement. CLSI document M100-S20. 2010.
- [2] Oh JW, Kim SH, Whang K. Traumatic cerebrospinal fluid leak: Diagnosis and management. Korean Journal of Neurotrauma. 2017;13(2):63-67.
- [3] Boppana HK, Welch T, Calderon C. Spontaneous cerebrospinal fluid rhinorrhoea: A case report. Cureus. 2020;12(7):e9401.
- [4] Abuabara A. Cerebrospinal fluid rhinorrhoea: Diagnosis and management. Medicina Oral, Patología Oral y Cirugía Bucal (Internet). 2007;12(5):397-400.
- [5] Severson M, Strecker-McGraw MK. Cerebrospinal fluid leak. InStatPearls [Internet]. StatPearls Publishing; 2020.
- [6] Jones NS, Becker DG. Advances in the management of CSF leaks: New techniques will improve the management of unilateral clear nasal discharge. BMJ. 2001;322(7279):122-23.
- [7] Simon LV, Newton EJ. Basilar skull fractures. StatPearls [Internet]. StatPearls Publishing; 2022.
- [8] Guyer RA, Turner JH. Delayed presentation of traumatic cerebrospinal fluid rhinorrhoea: Case report and literature review. Allergy Rhinol (Providence). 2015;6(3):188-90.
- [9] Friedman JA, Ebersold MJ, Quast LM. Post-traumatic cerebrospinal fluid leakage. World J Surg. 2001;25:1062-66.
- [10] Amin MU, Ghaffar A. Delayed appearance of posttraumatic cerebrospinal fluid fistula. J Coll Physicians Surg Pak. 2006;16:378-80.
- [11] Gumussoy M, Ugur O, Cukurova I, Uluoyul S. Recurrent meningitis and frontal encephalocele as delayed complications of craniofacial trauma. J Craniofac Surg. 2014;25:529-30.
- [12] Leung GK, Chan KH, Hung KN. Growing skull fracture in an adult nine years after blunt head trauma. J Clin Neurosci. 2011;18:855-57.
- [13] Misiran FF. Endoscopic repair of spontaneous cerebro-spinal fluid rhinorrhoea: A report of 3 cases. Med J Malaysia. 2002;57(4):503.

PARTICULARS OF CONTRIBUTORS:

1. Assistant Professor, Department of Microbiology, Sri Lakshmi Narayana Institute of Medical Sciences, Puducherry, India.
2. Assistant Professor, Department of General Medicine, Saveetha Medical College and Hospitals, Chennai, Tamil Nadu, India.

NAME, ADDRESS, E-MAIL ID OF THE CORRESPONDING AUTHOR:

Dr. G Vaishnavadevi,
Assistant Professor, Department of Microbiology, Sri Lakshmi Narayana Institute of Medical Sciences, Puducherry-605502, India.
E-mail: vaishnavambbs@gmail.com

AUTHOR DECLARATION:

- Financial or Other Competing Interests: None
- Was informed consent obtained from the subjects involved in the study? No
- For any images presented appropriate consent has been obtained from the subjects. No

PLAGIARISM CHECKING METHODS: [Jan H et al.]

- Plagiarism X-checker: May 02, 2022
- Manual Googling: Jun 04, 2022
- iThenticate Software: Jun 15, 2022 (15%)

ETYMOLOGY: Author Origin

Date of Submission: **Apr 27, 2022**
Date of Peer Review: **May 19, 2022**
Date of Acceptance: **Jun 15, 2022**
Date of Publishing: **Aug 01, 2022**