


The Importance of Estrogen Receptors in Aetiopathogenesis of Carpal Tunnel Syndrome in Postmenopausal Women

AYSE NUR DEGER¹, HAKKI DEGER², MAHIR TAYFUR³, OZLEM ARIK⁴, MEHMET FATIH EKICI⁵, MECDI GURHAN BALCI⁶



ABSTRACT

Introduction: Carpal Tunnel Syndrome (CTS) is a common peripheral neuropathy in postmenopausal women which is caused by compression of the median nerve in the carpal tunnel. Although mostly idiopathic, the aetiopathogenesis of CTS was not quite clear.

Aim: To verify the possible role of the estrogen surges and the presence of Estrogen Receptor (ER) in tenosynovial tissue on postmenopausal period, in the pathogenesis of idiopathic CTS.

Materials and Methods: This retrospective study was conducted on 16 patients with CTS in premenopausal group (group 1) and 18 patients with CTS in postmenopausal group (group 2). In this study, tenosynovial tissue samples of patients who had surgery due to CTS were used. Biopsy samples of 34 patients who were operated in the Neurosurgery Department of KSBU Medical Faculty Evliya Celebi Training and Research Hospital between

January 2011 and January 2012 were included in the study. An examination was made by Haematoxylin and Eosin (H&E) in the tenosynovial tissue. ER was performed by immunohistochemistry on tissue samples. The non inflammatory fibrosis, vascular proliferation and oedema were observed. A nuclear staining for ER was observed in synovial lining cells and fibroblasts in the tenosynovial tissue.

Results: The number of positive cells for ER in the tenosynovial tissue in postmenopausal patients with CTS was found higher according to premenopausal patients with CTS (p-value <0.01). A high association was found among patient age, severe EMG findings and ER positivity.

Conclusion: ER surges in postmenopausal period and increased ER positivity in the tenosynovial tissue in the aetiopathogenesis of CTS.

Keywords: Compression neuropathy, Histomorphology, Hormone receptor, Immunohistochemistry, Menopausal period

INTRODUCTION

Carpal Tunnel Syndrome (CTS) is the most common peripheral compression neuropathy resulting from compression of the median nerve in the carpal tunnel. The underlying mechanism includes increased carpal tunnel pressure due to either a reduction in the size of space in the carpal tunnel or an elevation in the volume of tunnel content [1-4]. In addition CTS occur with mechanical damage to the median nerve. The aetiology of CTS is unknown [1].

The most cases of CTS are idiopathic [4]. Some systemic diseases and conditions may be effective in the development of the syndrome. Diabetes, hypothyroidism, rheumatoid arthritis, alcoholism and renal dialysis are some of these predisposing factors [5-8]. CTS is more common in women. Male/female ratio is defined as 1/3 [4]. The epidemiological studies showed that estrogen surges during pregnancy, oophorectomy, postmenopausal case in women are associated with idiopathic CTS [5]. Hence, the present study aimed to verify the possible role of the estrogen surges and the presence of Estrogen Receptor (ER) in tenosynovial tissue on postmenopausal period, in the pathogenesis of idiopathic CTS.

MATERIALS AND METHODS

This retrospective study was conducted on 16 patients with idiopathic CTS in premenopausal period (group 1) and 18 patients with idiopathic CTS in postmenopausal period (group 2) were evaluated. In this study, tenosynovial tissue samples of patients who had surgery due to CTS were used. Ethics committee approval was received for this study. KSBU University (KSBU 14.06.2017, 2017-8/9) and informed consent form for this surgical procedure was obtained from all of the patients included in the study. The patients were operated in the Neurosurgery Department of KSBU Medical Faculty Evliya Celebi Training and Research Hospital between January 2011 to January 2012. The analysis of the data was done from January 2018 to July 2018.

Inclusion criteria: Idiopathic CTS patients were included in the study.

Exclusion criteria: Patients with diabetes, rheumatoid arthritis, thyroid dysfunction were excluded from the study.

To confirm the diagnosis of CTS in both groups of patients (group 1 and group 2) paresthesia along with median nerve trace, hand pain during the day or night were taken into consideration. In addition, positive findings including sensibility and provocative tests during the physical examination were used to confirm CTS [2,4].

Study Procedure

All those patients with clinical complaints and examination findings in support of CTS, underwent Electromyography (EMG), to further confirm the diagnosis.

After confirmation, they were divided into 2 groups:

- Group-1: Premenopausal group consisted of patients between the age group 20 to 35 years.
- Group-2: Postmenopausal group consisted of patients between the age group 50 to 75 years age group.

Patients in the postmenopausal group (group 2) were selected from individuals who have been in menopause for five years or more. The majority of patients, who were diagnosed with CTS as a result of physical examination mentioned above and laboratory findings, had received splints, Non Steroidal Anti-inflammatory Drugs, vitamin B12 treatment. Patients with unresolved complaints, despite drug therapy, were operated. About 0.5 mm³ tenosynovial tissue was excised from each case. About 1 cc saline solution was given to perineurium to decrease the hydrostatic pressure. Thus carpal tunnel was decompressed.

Connective tissue samples within 10% buffered formalin were immediately sent to histopathology laboratory. Paraffin-embedded

blocks were prepared from tissue samples and 4 micron-thick sections were taken. H&E staining was performed to evaluate the histomorphological changes caused by CTS in the subsynovial tissue. The procedure was performed at room temperature. Immunohistochemical examinations with ER to subsynovial connective tissue samples were made in both premenopausal (group 1) and postmenopausal (group 2) groups to evaluate ER of the fibroblasts and synovial lining cells (Clone SP 1 Thermo scientific).

In immunohistochemical procedure, micro polymer system kit was used. Mature breast tissue was used for positive external control and mesenchymal cells were used for internal control. Negative control for immunohistochemistry was processed without the primary antibody. Olympus CX41 light microscope was used in the assessment of H&E stained preparations and immunohistochemical studies and to get an image of the preparations. H&E stained sections were evaluated histomorphologically in both patient groups.

Positively stained fibroblasts (the cells with collagenous stroma and spindle, stellate nuclei) and synovial lining cells (the cells located in the periphery of tissue samples with oval nuclei) were counted in eight randomly selected areas per slide at X400 objective for ER assessment [4]. Complete nuclear immunostaining was considered to be positive. Percentages of immunoreactive cells among all cells counted per field were calculated.

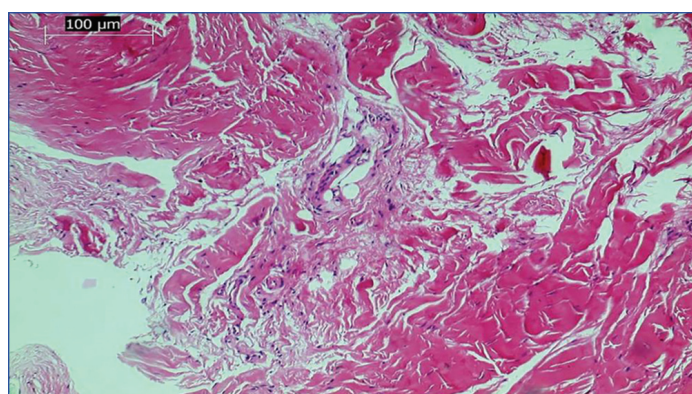
STATISTICAL ANALYSIS

Mann-Whitney U test was used for statistical analysis to compare cell staining in fibroblasts and synovial lining cells between both of patient groups. The association between patient age and ER positivity in fibroblasts and synovial lining cells in both of patient groups were evaluated. Along with the evaluation of association between EMG finding and ER positivity in fibroblasts and synovial lining cells.

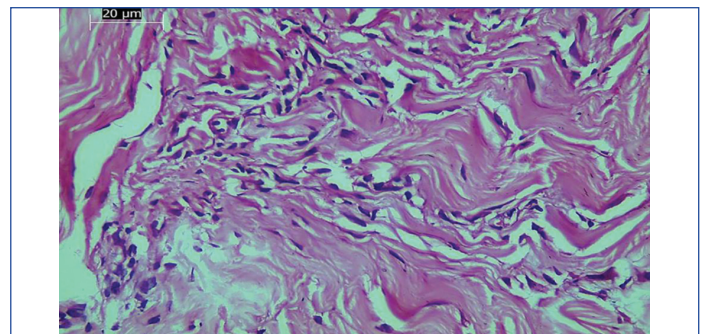
RESULTS

Tissue samples of both patient groups exhibited non inflammatory fibrosis in tenosynovial tissue. With H&E staining, tissue oedema, vascular proliferation, vascular hypertrophy in varying degrees were seen [Table/Fig-1,2]. In the immunohistochemical analysis performed with ER, the staining for ER in tenosynovial tissue was seen to be in intranuclear attributes [Table/Fig-3,4]. Intranuclear staining was seen in vascular endothelial cells, in fibroblasts and synovial lining cells in both of patient groups [Table/Fig-5,6].

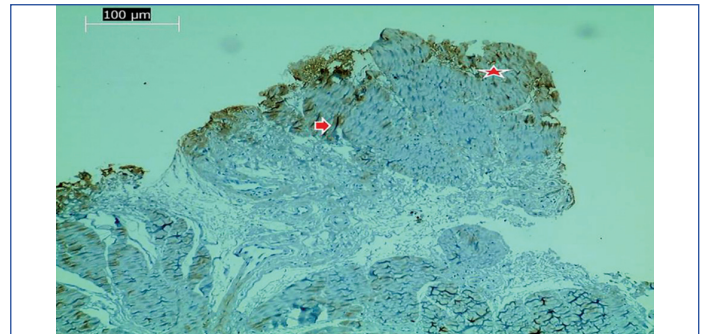
On comparing the number of fibroblasts and number of synovial lining cells giving positivity for ER in premenopausal and postmenopausal patient groups, it was observed that increased number of fibroblasts and synovial lining cells gave positivity for ER in postmenopausal patient and the difference of both cell types (fibroblast and synovial lining cell) amongst both groups was statistically significant (p -value < 0.01) [Table/Fig-7,8].




[Table/Fig-1]: Histological examination showed non inflammatory fibrosis and vascular proliferation in the tenosynovial tissue from the both patient groups (H&E, 10X).



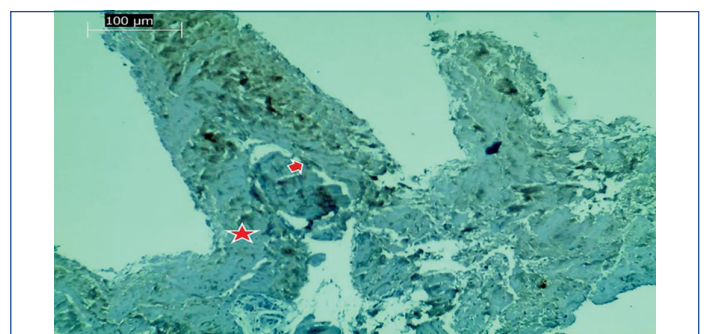
[Table/Fig-2]: Histological examination showed non inflammatory fibrosis and vascular proliferation in the tenosynovial tissue from the both patient groups (H&E,40X).




[Table/Fig-3]: Increased number of fibroblasts (arrow) and synovial lining cells (asterisk) positivity for ER in postmenopausal patients (ER,10X).



[Table/Fig-4]: Increased number of fibroblasts (arrow) and synovial lining cells (asterisk) positivity for ER in postmenopausal patients (ER,40X).



[Table/Fig-5]: A few number ER positive fibroblasts (arrow) and synovial lining cells (asterisk) are seen in premenopausal patients (ER, 10X).



[Table/Fig-6]: A few number ER positive fibroblasts (arrow) and synovial lining cells (asterisk) are seen in premenopausal patients (ER,40X).

Case number	Age (years)	EMG findings	Fibroblast		Premenopausal patients	
			Positive N (%)	Total	Synovial lining cells	
					Positive N (%)	Total
1	34	Severe	8 (6.5)	123	3 (5.08)	59
2	34	Moderate	0	58	4 (9.52)	42
3	34	Moderate	9 (9.78)	92	11 (17.74)	62
4	35	Mild	92 (55.75)	165	14 (18.67)	75
5	33	Mild	74 (57.81)	128	15 (26.78)	56
6	30	Moderate	0	0	0	0
7	30	Mild	38 (36.89)	103	19 (29.69)	64
8	33	Mild	50 (52.63)	95	14 (22.95)	61
9	32	Moderate	48 (42.85)	112	34 (36.95)	92
10	31	Mild	14 (16.86)	83	3 (5.77)	52
11	30	Mild	52 (40.62)	128	20 (58.82)	34
12	30	Mild	0	0	0	0
13	22	Severe	8 (9.75)	82	17 (24.28)	70
14	23	Moderate	12 (11.11)	108	7 (12.50)	56
15	27	Mild	0	0	0	0
16	29	Moderate	10 (16.13)	62	6 (10.00)	60

[Table/Fig-7]: Showing data of premenopausal patients.

Case number	Age (years)	EMG findings	Fibroblast		Synovial lining cells	
			Positive N (%)	Total	Positive N (%)	Total
2	53	Mild	54 (58.69)	92	58 (87.87)	66
3	62	Moderate	85 (63.43)	134	26 (30.58)	85
4	51	Severe	160 (80.00)	200	58 (60.41)	96
5	50	Moderate	43 (48.86)	88	32 (47.05)	68
6	52	Mild	0	0	0	0
7	52	Moderate	136 (87.17)	156	45 (48.91)	92
8	51	Mild	68 (71.57)	95	14 (25.45)	55
9	61	Moderate	75 (89.28)	84	15 (62.50)	24
10	51	Moderate	0	0	0	0
11	74	Mild	113 (89.68)	126	32 (57.14)	56
12	75	Mild	0	0	0	0
13	59	Mild	12 (15.38)	78	3 (6.66)	45
14	53	Moderate	148 (84.09)	176	35 (35.71)	98
15	50	Mild	69 (79.31)	87	28 (90.32)	31
16	51	Severe	88 (78.57)	112	36 (64.28)	56
17	62	Mild	0	0	0	0
18	64	Moderate	13 (15.47)	84	44 (78.57)	56

[Table/Fig-8]: Showing data of postmenopausal patients.

The relationship between patient age and EMG findings with ER positivity was evaluated with Eta coefficient. On evaluation in both groups, showed strong relationship of 94% between EMG changes with positivity for ER in fibroblasts and of 95% between EMG changes with positivity for ER in synovial lining cells was observed. There was strong relationship of 87% between patient age with positivity for ER in fibroblasts and of 89% between patient age with positivity for ER in synovial lining cells.

DISCUSSION

Carpal Tunnel Syndrome (CTS) is caused by compression of median nerve of wrist, hence impacts the functioning of hand and an important cause of morbidity [9]. It is important to know the aetiology of CTS firstly for effective treatment of CTS. The increased pressure within carpal tunnel causes median nerve neuropathy. Although there are numerous studies about the CTS, it is not known exactly the reason

of increase in pressure in the carpal tunnel and aetiology of CTS [10,11]. Increased pressure in the carpal tunnel and the median nerve damage can occur the result of mechanical factors. Another reason is that ischaemia reperfusion injury causes CTS [3,12]. It recently focuses on the histomorphologic changes in tenosynovial tissues in carpal tunnel in the aetiopathogenesis of CTS. Increase in the size of the collagen fibrils, fibroblast proliferation, vascular proliferation, Ventricular hypertrophy, intimal thickening are histomorphological changes seen in the tenosynovial tissue in CTS [2].

Some cytokines and growth factors are responsible for changes seen in the tenosynovial tissue in patients with CTS, whereas they are not seen in non CTS individuals. The non inflammatory fibrosis is seen in the tenosynovial tissue in CTS. Transforming growth factor β (TGF- β) is one of basic mediators responsible from fibrosis in tissues. The increase in TGF- β expression in the tenosynovial tissue is seen in CTS. The inhibition of TGF- β expression is seen as a treatment target in CTS [13-16]. Hirata H et al., specified that Matrix Metallo Proteinase (MMP)-2 is produced in the tenosynovial tissue in early period in CTS. MMP-2 may be responsible for narrowing of the arteries and pain resulting in CTS [17]. In another study, Hirata H et al., showed that there was increased Vascular Endothelial Growth Factor (VEGF) and prostoglandin E2 expression in intermediate phase in CTS. These two molecules may be responsible for increasing vascular permeability and the formation of oedema in CTS [18].

Although the majority of patients with CTS are idiopathic, some systemic diseases and conditions were to ease occurrence of the disease. The diabetes, obesity, thyroid diseases, renal dialysis are some of these diseases. CTS is more common in women. The incidence is increased in pregnancy and menopausal period. The hormone replacement treatment, oophorectomy are systemic factors that facilitate the development of the disease [5,19,20].

It is known that estrogen has anti-inflammatory properties. The amount of some inflammatory cytokines such as Interleukin 1 (IL-1), Interleukin 6 (IL-6) and tumour necrosis factor alpha increases due to estrogen fluctuations in menopause. The estrogen shows its anti-inflammatory affect by repressing genes which regulate inflammation. The surges in estrogen level in menopausal period eliminate anti-inflammatory feature of estrogen. This condition result with cellular proliferation, angiogenesis, increased capillary permeability, oedematous changes in tissues [4]. The appearance of these changes in carpal tunnel contributes to the development of CTS. It is believed that hormonal affects and oestrogen surges have a role in CTS that frequently seen in women. It is believed that oestrogen surges cause histomorphological changes in tissues by causing it to lose its anti-inflammatory properties [4,21].

It is shown that estrogen shows anti-inflammatory affect by suppressing proinflammatory cytokines in a study by Amelia T et al., and Anneleen L and Neven P, [5,22]. Anneleen L and Neven P showed that estrogen has an affect preventing from arthritis by this way. It is specified that aromatase inhibitors, used in ER positive breast cancer, increase AI Induced Musculoskeletal Syndrome (AIMSS) (arthralgia, carpal tunnel syndrome, start pains, stiffness, etc) in same study [22].

Histomorphological studies on the impact of hormonal factors on the CTS is very few number in the literature. The presence of estrogen in target tissue is a prerequisite for acting via ER. Amelia T et al., investigated the ER and PR positive cells in transverse carpal ligament biopsies and showed that positive cell numbers for ER and PR receptors in patients seen CTS findings are higher than non CTS individuals [5]. Kim JK et al., evaluated ER receptors in tenosynovial tissue in postmenopausal women. They determined higher ER positivity, cells in tenosynovial tissue in postmenopausal women with idiopathic CTS according to postmenopausal individuals, not seen in clinical CTS findings [4].

Present study examined ER in the tenosynovial tissue in patients with idiopathic CTS in premenopausal group (between 20-35 years) and patients with idiopathic CTS in postmenopausal group (between 50-75 years). ER expression was observed in the tenosynovial tissue in patients with CTS in both groups. This study showed that positive cell number in both fibroblasts and synovial lining cells in postmenopausal CTS cases is higher according to premenopausal CTS cases. A strong relationship was seen between ER positivity and patient age in fibroblasts and synovial lining cells. A strong relationship was seen between ER positivity and EMG findings in fibroblasts and synovial lining cells also.

Limitation(s)

Due to the insufficient number of patients, a small number of tissue samples were studied. Further studies with larger patient samples are recommended in future for better contributions to literature.

CONCLUSION(S)

The increased ER in tenosynovial tissue cells in postmenopausal period with increased incidence of CTS is to support role of hormones in aetiopathogenesis of CTS. It is believed that the surges of estrogen level in postmenopausal period eliminate anti-inflammatory feature of estrogen. It is possible that the loss of anti-inflammatory feature increases the incidence of CTS. Even so, the role of estrogen in the aetiopathogenesis of CTS is not understood exactly. Further studies are needed about the role of estrogen in the occurrence of symptoms and in the aetiopathogenesis of CTS.

REFERENCES

- [1] Donato G, Galosso O, Valentino P, Conforti F, Zuccalà V, Russo E, et al. Pathological findings in subsynovial connective tissue in idiopathic carpal tunnel syndrome. *Clin Neuropathol*. 2009;28(2):129-35.
- [2] Ettema AM, Amadio P, Zhao C, Wold LE, An KN. A histological and immunohistochemical study of the subsynovial connective tissue in idiopathic carpal tunnel syndrome. *J Bone Joint Surg Am*. 2004;86-A(7):1458-66.
- [3] Jinrok O, Zao C, Amadio PC, An KN, Zobitz ME, Wold LE, et al. Vascular pathologic changes in the flexor tenosynovium (subsynovial connective tissue) in idiopathic carpal tunnel syndrome. *J Orthop Res*. 2004;22(6):1310-15.
- [4] Kim JK, Han HJ, Kim MJ, Kim JS. The expression of estrogen receptors in the tenosynovium of postmenopausal women with idiopathic carpal tunnel syndrome. *J Orthop Res*. 2010;28(11):1469-74.
- [5] Amelia T, Pagnotta A, Antonella Z, Raffaella S. Estrogen and progesterone receptors in carpal tunnel syndrome. *Cell Biol Int*. 2008;32(1):75-79.
- [6] Deger AN, Deger H, Taser F. The role of neoangiogenesis and vascular endothelial growth factor in the development of carpal tunnel syndrome in patients with diabetes. *Niger J Clin Pract*. 2016;19(2):189-95.
- [7] Deger AN, Deger H, Tayfur M, Balci MG, Aksoy A, Ekici MF, et al. Comparison of transforming growth factor- β (TGF- β) expression between diabetes mellitus associated carpal tunnel syndrome and idiopathic carpal tunnel syndrome. *Int J Clin Exp Med*. 2016;9(2):1218-26.
- [8] Taser F, Deger A, Deger H. Comparative histopathological evaluation of patients with diabetes, hypothyroidism and idiopathic carpal tunnel syndrome. *Turk Neurosurg*. 2017;27(6):991-97.
- [9] Galasso O, Massimo M, Donato G, Di Mizio G, Padua L, Brando A, et al. Histopathological, clinical, and electrophysiological features influencing postoperative outcomes in carpal tunnel syndrome. *J Orthop Res*. 2011;29(8):1298-04.
- [10] Werthel JD, Zhao C, An KN, Amadio PC. Carpal tunnel syndrome pathophysiology: Role of subsynovial connective tissue. *J Wrist Surg*. 2014;3(4):220-26.
- [11] Schmid AB, Bland JDP, Bhat MA, Bennett DLH. The relationship of nerve fibre pathology to sensory function in entrapment neuropathy. *Brain*. 2014;137(Pt 12):3186-99.
- [12] Kim JK, Koh Y, Kim JS, Hann HJ, Kim MJ. Oxidative stress in subsynovial connective tissue of idiopathic carpal tunnel syndrome. *J Orthop Res*. 2010;28(11):1463-68.
- [13] Chikenji T, Gingery A, Zhao C, Passe SM, Ozasa Y, Larson D, et al. Transforming growth factor- β (TGF- β) expression is increased in the subsynovial connective tissues of patients with idiopathic carpal tunnel syndrome. *J Orthop Res*. 2014;32(1):116-22.
- [14] Gingery A, Yang T, Passe SM, An KN, Zhao C, Amadio PC, et al. TGF- β signaling regulates fibrotic expression and activity in carpal tunnel syndrome. *J Orthop Res*. 2014;32(11):1444-50.
- [15] Yang TH, Thoreson AR, Gingery A, An KN, Larson DR, Zhao C, et al. Collagen gel contraction as a measure of fibroblast function in carpal tunnel syndrome. *J Biomed Mater Res A*. 2015;103(2):574-80.
- [16] Chikenji T, Gingery A, Zhao C, Vanhees M, Moriya T, Reisdorf R, et al. Transforming Growth Factor- β (TGF- β) expression is increased in the subsynovial connective tissue in a rabbit model of carpal tunnel syndrome. *PLoS One*. 2014;9(9):e108312.
- [17] Hirata H, Tsujii M, Yoshida T, Imanaka-Yoshida K, Morita A, Okuyama N, et al. MMP-2 expression is associated with rapidly proliferative arteriosclerosis in the flexor tenosynovium and pain severity in carpal tunnel syndrome. *J Pathol*. 2005;205(4):443-50.
- [18] Hirata H, Nagakura T, Tsujii M, Morita A, Fujisawa K, Uchida A, et al. The relationship of VEGF and PGE2 expression to extracellular matrix remodelling of the tenosynovium in the carpal tunnel syndrome. *J Pathol*. 2004;204(5):605-12.
- [19] Lewańska M, Walusiak SJ. Etiological factors of carpal tunnel syndrome in subjects occupationally exposed to monotype wrist movements. *Med Pr*. 2014;65(2):261-70.
- [20] Padua L, Di Pasquale A, Pazzaglia C, Liotta GA, Librante A, Mondelli M, et al. Systematic review of pregnancy-related carpal tunnel syndrome. *Muscle Nerve*. 2010;42(5):697-02.
- [21] Longo UG, Mazzola A, Carotti S, Francesconi M, Catapano S, Magri F, et al. The role of estrogen and progesterone receptors in the rotator cuff disease: A retrospective cohort study. *BMC Musculoskelet Disord*. 2021;22(1):891.
- [22] Anneleen L, Neven P. Pharmacology of arthralgia with estrogen deprivation. *Steroids*. 2011;76(8):781-85.

PARTICULARS OF CONTRIBUTORS:

1. Associate Professor, Department of Pathology, Kutahya Health Sciences University, Faculty of Medicine, Kutahya, Turkey.
2. Operating Doctor, Department of Neurosurgery, TC SB KSBÜ Kutahya Evliya Celebi Training and Research Hospital, Kutahya, Turkey.
3. Associate Professor, Department of Pathology, Erzincan University, Faculty of Medicine, Erzincan/Turkey, Erzincan, Turkey.
4. Assistant Professor, Department of Biostatistics, Kutahya Health Sciences University, Faculty of Medicine, Kutahya, Turkey.
5. Assistant Professor, Department of General Surgery, Kutahya Health Sciences University, Faculty of Medicine, Kutahya, Turkey.
6. Associate Professor, Department of Pathology, Erzincan University, Faculty of Medicine, Kutahya, Turkey.

NAME, ADDRESS, E-MAIL ID OF THE CORRESPONDING AUTHOR:

Dr. Ayse Nur Deger,
Associate Professor, Department of Pathology, Kutahya Health Sciences University,
Faculty of Medicine, Kutahya, Turkey.
E-mail: ayhade@yahoo.com

PLAGIARISM CHECKING METHODS: [Jain H et al.]

- Plagiarism X-checker: Jan 17, 2022
- Manual Googling: May 29, 2022
- iThenticate Software: Aug 16, 2022 (22%)

ETYMOLOGY: Author Origin

AUTHOR DECLARATION:

- Financial or Other Competing Interests: This research hereby is supported through the DPU University (DPU BAP 2012/17)
- Was Ethics Committee Approval obtained for this study? Yes
- Was informed consent obtained from the subjects involved in the study? Yes
- For any images presented appropriate consent has been obtained from the subjects. Yes

Date of Submission: **Jan 15, 2022**

Date of Peer Review: **Feb 17, 2022**

Date of Acceptance: **Jun 03, 2022**

Date of Publishing: **Sep 01, 2022**