

# Invisalign Therapy in a Case of Mandibular Incisor Extraction

SERGIO LUIZ MOTA-JÚNIOR<sup>1</sup>, ROBERT WILLER FARINAZZO VITRAL<sup>2</sup>, MATHEUS MELO PITHON<sup>3</sup>, GIL GUILHERME GASPARELLO<sup>4</sup>, ORLANDO MOTOHIRO TANAKA<sup>5</sup>



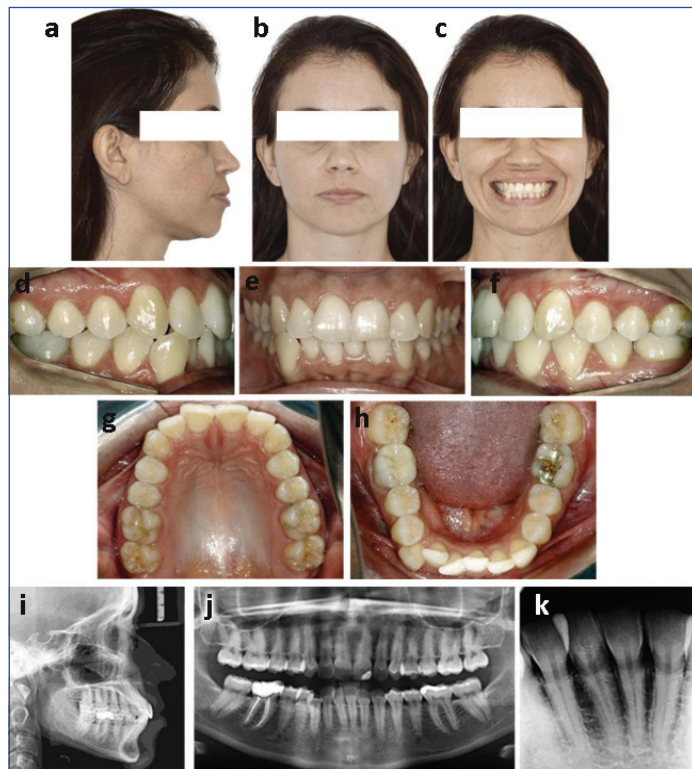
## ABSTRACT

Clear aligners have been sought by patients as an aesthetic alternative to conventional orthodontic treatment. Despite the limitation that the aligner system offers, its use has improved over time. Hereby, authors discuss case of a 35-year-old female with Angle's Class I malocclusion patient with severe mandibular crowding who was treated with mandibular incisor extraction using the Invisalign system. Clinical and radiographic examination revealed skeletal Class I malocclusion, severe crowding of the lower incisors, light crowding of the upper incisors, crossbite of the mandibular right canine, a convex profile, prominent lower lip, and a Bolton discrepancy in the lower anterior region. Fourteen trays were used in the maxillary arch and 28 in the mandibular arch. Two additional refinements, one with 13 and the other with 10 trays were delivered. After 2 years and 2 months of active treatment, good posterior occlusion and alignment of the teeth with adequate occlusion function and a balanced smile were achieved. The maxillary retainer was used continuously for 1 year, and at night until now. Successful tooth alignment and space closure were maintained, and the patient was satisfied with the results on the 2 year follow-up.

**Keywords:** Alignment, Aligner incisor extraction, Midline

## CASE REPORT

A 35-year-old female came to the Private Orthodontic Clinic with the chief complaint of lower incisor crowding. Clinical examination revealed lip competence convex profile with a prominent lower lip [Table/Fig-1a-c]. On the intraoral examination, molars and canines were in Angle's Class I relationship, a mandibular right canine with crossbite in the buccal position, severe crowding of the lower incisors, and light crowding of the upper incisors [Table/Fig-1d-h]. An excess of 5 mm in the lower anterior region in the Bolton analysis. The mandibular midline deviated 2.0 mm to the right side. The panoramic radiograph showed a full permanent adult dentition, except for the third molars [Table/Fig-1i-k]. The



**[Table/Fig-1]:** Pretreatment photographs and radiographs.

cephalometric measurements presented skeletal Class I (ANB=2°), biprotrusion of the incisors (1.NA=27.5°, 1-NA=8 mm, IMPA=96°), as shown in the [Table/Fig-2].

Cephalometric measurements	Measurement	Normal	Pretreatment	Post-treatment	at 2 year follow-up
Skeletal pattern	SNA (°)	82	83	83	83
	SNB (°)	80	81	80.5	80.5
	ANB (°)	2	2	2.5	2.5
	Y-Axis (°)	59.9	66.5	67	67
	SN-GoGn (°)	32	32.5	34	34
	FMA (°)	25	22	24	24
Dental pattern	IMPA (°)	90	96	93.5	94.5
	1.NA (°)	22	27.5	23.5	24
	1-NA (mm)	4	8	6.5	7
	1.1 (°)	131	118.5	126	124
Profile	LS-S (mm)	0	1	0.5	0.5
	LI-S (mm)	0	5	3	3
	Z Angle (°)	75	69	73	72.5

**[Table/Fig-2]:** Cephalometric measurements.

SNA: Sella, nasion, A point; SNB: Sella, nasion, B point; ANB: A point, nasion, and B point; SN-GoGn: Angle formed by lines S-N and Go-Gn; FMA: angle formed by the mandibular plane and the Frankfurt plane; IMPA: angle formed by the long axis of the mandibular incisors with the mandibular plane; LS-S: Labrale superior to midpoint of sella; Labrale Inferius (LI), Mentolabial sulcus (Lis); Z-angle The angle between soft tissue labralesuperior, pogonion (profile line) and Frankfort horizontal plane. Measures the amount of lip protrusion

## Treatment Objectives

The objectives of this treatment were to improve the lower lip protrusion, correct the lower right canine crossbite, align and level the anterior teeth, and maintain good posterior occlusion.

## Treatment Alternatives

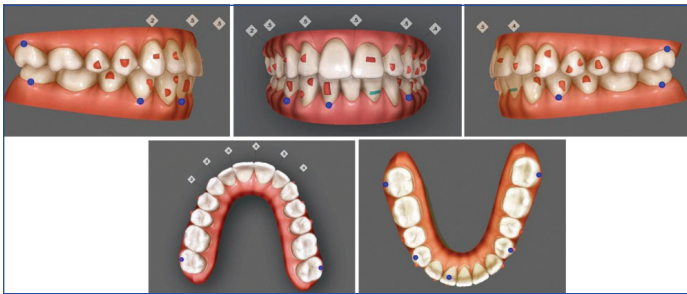The patient did not want to use braces. To fulfill the patient's demands, the following treatment alternatives were considered:

- 1) Interproximal Reduction (IPR) of the anterior upper and lower teeth;
- 2) IPR of the anterior upper incisors and extraction of one lower incisor;

- 3) Extraction of the first four premolars and one lower incisor;
- 4) No intervention. The alternatives were discussed, and the patient chose to reduce the mesiodistal maxillary incisor length and extract one mandibular incisor.

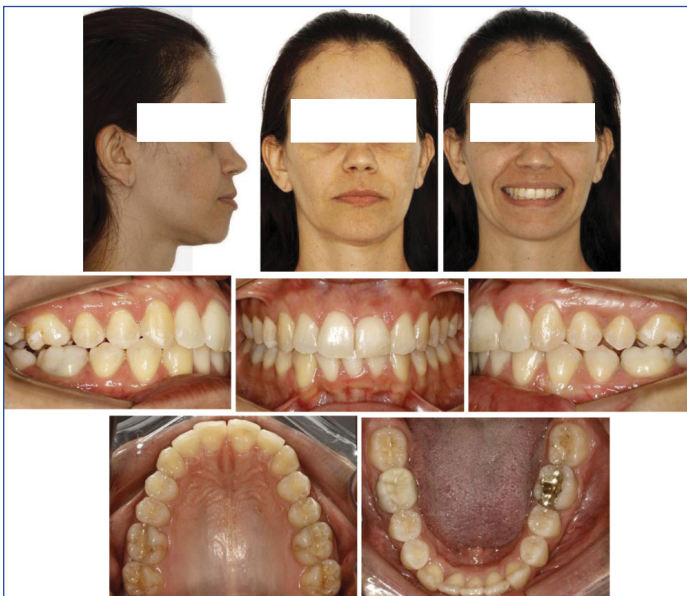### Treatment Process

The results after orthodontist adjustments were predicted by ClinCheck and shown to the patient [Table/Fig-3]. The patient approved the treatment with mandibular right lateral incisor extraction. The treatment included 14 trays for the upper arch and 28 for the lower arch. The patient was instructed to change the trays every 14 days when she visited the office. Passive trays were used for the upper arch until the lower arch treatment was finished.



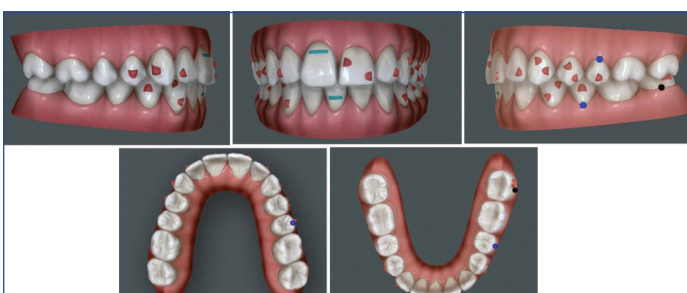
[Table/Fig-3]: First ClinCheck.

After the first set of trays was used (14 and 28 trays for upper and lower arches, respectively), extraction space closure, posterior open bite, distally upper incisor inclination, and poor alignment of the upper and lower incisors were observed; therefore, refinement was required [Table/Fig-4].



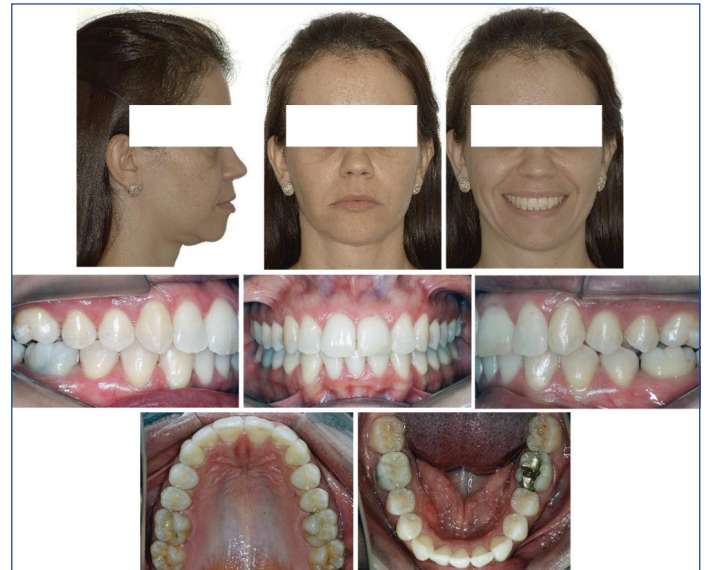[Table/Fig-4]: Progress before the first refinement.

A new ClinCheck was required after professional adjustments [Table/Fig-5], which was shown to the patient and approved. The refinement included 13 trays for the upper and lower arches, which were changed every 14 days.



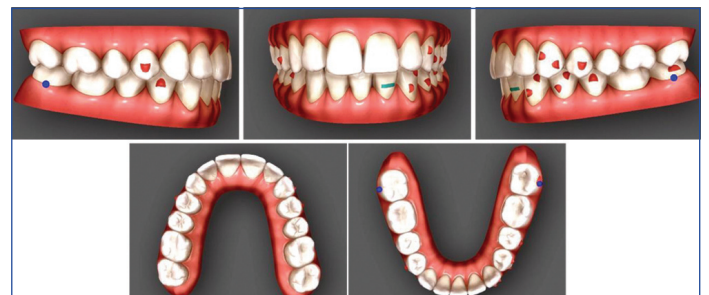[Table/Fig-5]: Refinement ClinCheck.

After this phase, posterior occlusion improvement was observed, but the upper central incisors were distally inclined, and the lower incisors were not well aligned [Table/Fig-6].



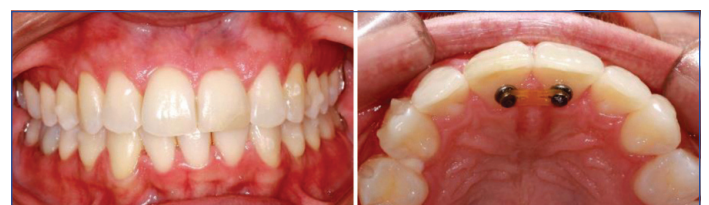[Table/Fig-6]: Progress before the second refinement.

A second refinement was required after professional adjustments [Table/Fig-7], which was shown to the patient and approved. This refinement included 10 trays for upper and lower arches, which were changed every 14 days.



[Table/Fig-7]: Second refinement ClinCheck.

A small diastema between the upper central incisors was observed during this phase. Two bottoms were bonded on the palatal surface of these teeth, and an elastic chain was used to close the space [Table/Fig-8].



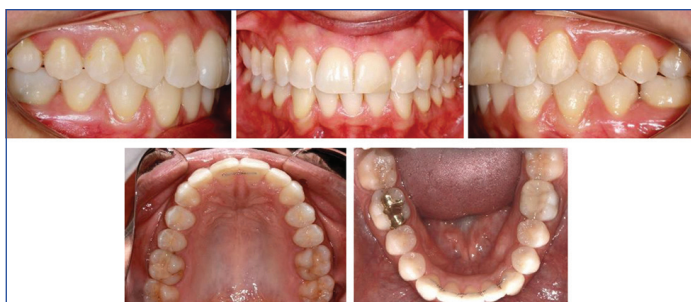[Table/Fig-8]: Bonded bottoms used to close maxillary central incisor diastema.

### Treatment Results

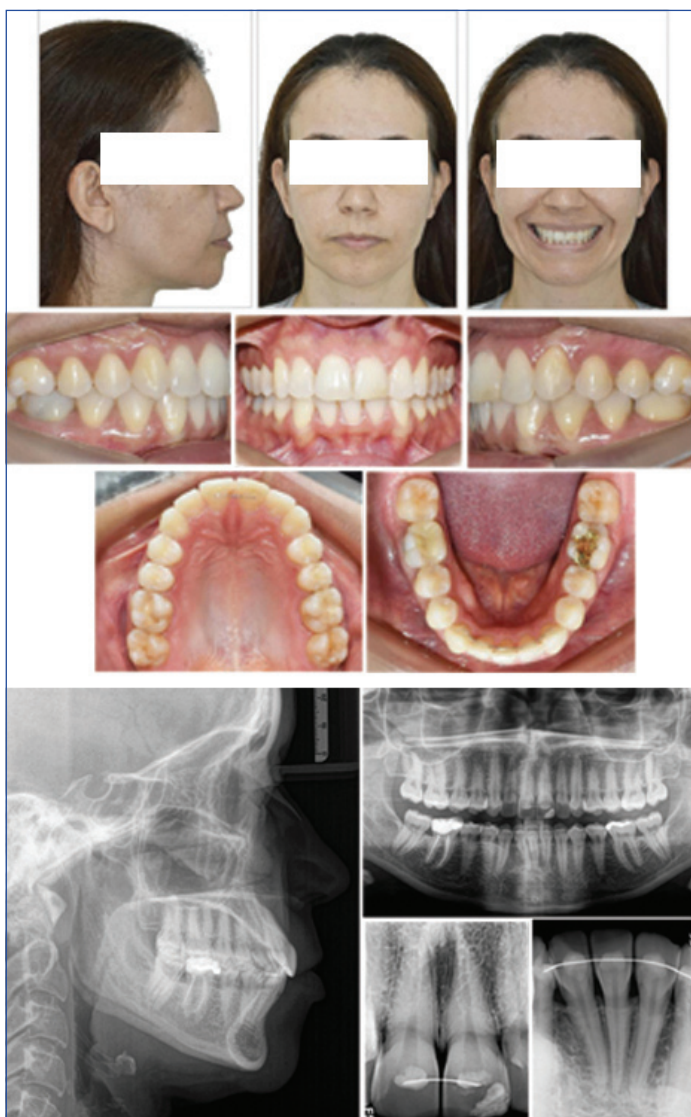After 2 years and 2 months of active treatment good posterior occlusion and alignment of the teeth with good occlusion function and harmonic smile were achieved [Table/Fig-9]. Maxillary midline coincident with the face and with the center of left mandibular central incisor. A fixed retainer with 0.018 inches stainless steel wire was bonded on all mandibular anterior teeth and palatal surface of the maxillary central incisors. A vacuum-formed retainer was used continuously for the maxillary arch for 1 year and at night for 1 additional year.

[Table/Fig-10] displays the 2 years follow-up, showing good treatment stability. The cephalometric superimposition tracings show upper and lower incisors upright with the maintenance of vertical position in the follow-up period [Table/Fig-11].

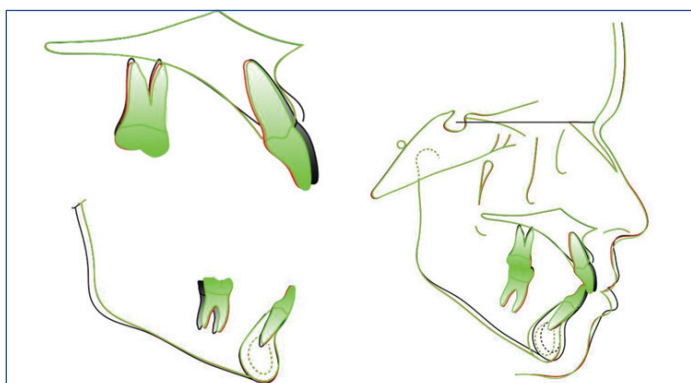



[Table/Fig-9]: Post-treatment intraoral photographs.



[Table/Fig-10]: At 2 year follow-up.



[Table/Fig-11]: Cephalometric superimposition tracing.

## DISCUSSION

The Angle's Class I malocclusion treatment with anterior crowding can be successfully conducted with clear aligners [1,2], although

overjet increasing may be observed [3]. In the present case report, the patient was treated with Invisalign System and due to the Bolton discrepancy of excess of 5 mm in the lower anterior region, the overjet was satisfactory at the end of the treatment, even with the extraction of a lower incisor.

The improvement in this patient was achieved with satisfactory orthodontic planning and correct use of Invisalign aligners; the patient changed the aligner every 14 days, although the time interval for changing the aligners is unclear [4,5].

Although ClinCheck is a tool that allows the orthodontist to visualise the entire treatment from the beginning to the end in the three planes of space [2], ClinCheck tends to overestimate the movement of the teeth and thus does not reflect reality [6,7]. Therefore, two refinements were needed to achieve satisfactory functional and aesthetic occlusion in the present case report.

Extraction is a widely-known and crucial tool for missing space in orthodontic treatment [8,9]. The patient in the present case report had a mesiodistal Bolton discrepancy of 5 mm of excess of the mandibular anterior teeth. The IPR of mandibular anterior teeth was one treatment alternative, but 5 mm mesiodistal reduction would be a large enamel reduction and sensitivity would be started. Thus, the incisor extraction alternative was the chosen one.

Even though the extraction of the lower incisor could have detrimental effects, such as an increase in overjet and overbite or a reduction in intercanine length [10], it was a suitable choice [1] for the present case because of good alignment with a satisfactory overjet was observed.

The choice of which incisor to extract is always important. Some characteristics need to be considered, such as the presence of gingival recession or periodontal defect, large restoration, the location of the incisor relative to the crowding, and the mesiodistal width of the incisor. Usually, the lateral incisor is the preferred tooth, however, the incisor that is outside the natural arch and closest to the crowding is frequently the candidate for extraction [9,10], as in the present case report with the most poorly aligned and closest to the crossbite. The main movement observed for space closure was by inclination of the mandibular incisor extraction, which is a reasonably accurate movement [11-13]. For refinement, a controlled tipping and rotation of the incisors and canines considered inaccurate movements in agreement with Charalampakis O et al., [11,14].

There are various elements that differentiate adult orthodontic treatment from that of children or adolescents [15], but adequate results were achieved after the refinement stage and the patient was satisfied with her smile and self-esteem was improved without the discomfort, oral hygiene problems, and lack of aesthetics associated with conventional fixed appliances.

## CONCLUSION(S)

The Invisalign system delivered a good leveling and alignment with an improved profile and good intercuspation with the extraction of one mandibular incisor and the patient was satisfied with the stable after 2 years follow-up results.

## REFERENCES

- [1] Al-Nadawi M, Kravitz ND, Hansa I, Makki L, Ferguson DJ, Vaid NR. Effect of clear aligner wear protocol on the efficacy of tooth movement. *Angle Orthod.* 2021;91(2):157-63.
- [2] Tanaka OM, Mota Junior SL, Reyes AA, de Moraes Alves da Cunha T. Has biology changed with clear aligners? *Am J Orthod Dentofacial Orthop.* 2021;160(5):643-44.
- [3] Miller RJ, Duong TT, Derakhshan M. Lower incisor extraction treatment with the Invisalign system. *J Clin Orthod.* 2002;36(2):95-102.
- [4] Buschang PH, Ross M, Shaw SG, Crosby D, Campbell PM. Predicted and actual end-of-treatment occlusion produced with aligner therapy. *Angle Orthod.* 2015;85(5):723-27.
- [5] Krieger E, Seiferth J, Saric I, Jung BA, Wehrbein H. Accuracy of Invisalign® treatments in the anterior tooth region. First results. *J Orofac Orthop.* 2011;72(2):141-49.

- [6] Bahreman AA. Lower incisor extraction in orthodontic treatment. *Am J Orthod.* 1977;72(5):560-67.
- [7] Tweed CH. Indications for the extraction of teeth in orthodontic procedure. *Am J Orthod Oral Surg.* 1944;42:22-45.
- [8] Travess H, Roberts-Harry D, Sandy J. Orthodontics. Part 8: Extractions in orthodontics. *Br Dent J.* 2004;196(4):195-203.
- [9] Antelo OM, Meira TM, Miyoshi CS, Allahham A, Tanaka OM. Single lower incisor extractions in adult Invisalign patients. *J Clin Orthod.* 2018;52(8):419-26.
- [10] Zawawi KH. Orthodontic treatment of a mandibular incisor extraction case with invisalign. *Case Rep Dent.* 2014;2014:657657.
- [11] Charalampakis O, Iliadi A, Ueno H, Oliver DR, Kim KB. Accuracy of clear aligners: A retrospective study of patients who needed refinement. *Am J Orthod Dentofacial Orthop.* 2018;154(1):47-54.
- [12] Zhang XJ, He L, Guo HM, Tian J, Bai YX, Li S. Integrated three-dimensional digital assessment of accuracy of anterior tooth movement using clear aligners. *Korean J Orthod.* 2015;45(6):275-81.
- [13] Brezniak N. The clear plastic appliance: A biomechanical point of view. *Angle Orthod.* 2008;78(2):381-82.
- [14] Kravitz ND, Kusnoto B, Agran B, Viana G. Influence of attachments and interproximal reduction on the accuracy of canine rotation with Invisalign. A prospective clinical study. *Angle Orthod.* 2008;78(4):682-87.
- [15] Subi S, Mona P, Nindra J, Sidhu MS, Ahlawat S. Orthodontic limitations in adults: A review. *J Clin Diagn Res.* 2022;16(2):ZE01-ZE05.

#### PARTICULARS OF CONTRIBUTORS:

1. Faculty, Department of Orthodontics, Juiz de Fora Federal University, Juiz de Fora, Minas Gerais, Brazil.
2. Faculty, Department of Orthodontics, Juiz de Fora Federal University, Juiz de Fora, Minas Gerais, Brazil.
3. Faculty, Department of Health, Southwest Bahia State University, UESB, Jequié, Bahia, Brazil. .
4. PhD Student, Department of Orthodontics, Pontifícia Universidade Católica do Paraná, Curitiba, Brazil.
5. Faculty, Department of Orthodontics, Pontifícia Universidade Católica do Paraná, Curitiba, Paraná, Brazil.

#### NAME, ADDRESS, E-MAIL ID OF THE CORRESPONDING AUTHOR:

Orlando Motohiro Tanaka,  
R Imaculada Conceição, 1155, Curitiba, Paraná, Brazil.  
E-mail: tanakaom@gmail.com

#### PLAGIARISM CHECKING METHODS: [\[Jain H et al.\]](#)

- Plagiarism X-checker: Jun 30, 2022
- Manual Googling: Aug 01, 2022
- iThenticate Software: Aug 03, 2022 (6%)

#### ETYMOLOGY: Author Origin

#### AUTHOR DECLARATION:

- Financial or Other Competing Interests: None
- Was informed consent obtained from the subjects involved in the study? Yes
- For any images presented appropriate consent has been obtained from the subjects. Yes

Date of Submission: **Jun 28, 2022**

Date of Peer Review: **Jul 25, 2022**

Date of Acceptance: **Aug 05, 2022**

Date of Publishing: **Sep 01, 2022**