

# Incidental Diagnosis of Swyer-James-MacLeod Syndrome: A Case Report and Review of Literature

SHWETA RAMNARAYAN BORKAR<sup>1</sup>, AJAY VASANT LANJEWAR<sup>2</sup>,  
ANIL INAMDAR<sup>3</sup>, ANSHU AGARWAL<sup>4</sup>, ATUL SUDHAKAR MADHIKAR<sup>5</sup>



## ABSTRACT

Swyer-James-MacLeod Syndrome (SJMS) appears as unilateral hyperlucency on chest imaging and is documented as a rare sequela of frequent paediatric respiratory infections. Due to its rarity, various causes of haemithoracic radio-opacity and radiolucency were studied while evaluating this case. In individuals with bronchiolitis obliterans, SJMS has been observed in about 4% of cases. The left lung is preferentially involved in most cases for unknown reasons. The syndrome usually develops following viral respiratory infection in infancy or early childhood, such as adenoviruses or *Mycoplasma pneumoniae*. It is predicted to have a prevalence of 0.01%. This case study focuses on an incidental finding of abnormal radiography identified during assessing a 54-year-old male with low back pain in Chronic Kidney Disease (CKD). Patient and relative should be explained about the Chest X-ray finding and the reason for SJMS to avoid unscrupulous investigations in the future as index patient had no respiratory symptoms.

**Keywords:** Bronchiolitis obliterans, Diminished vascularity, Unilateral hyperlucent lung, Viral respiratory infection

## CASE REPORT

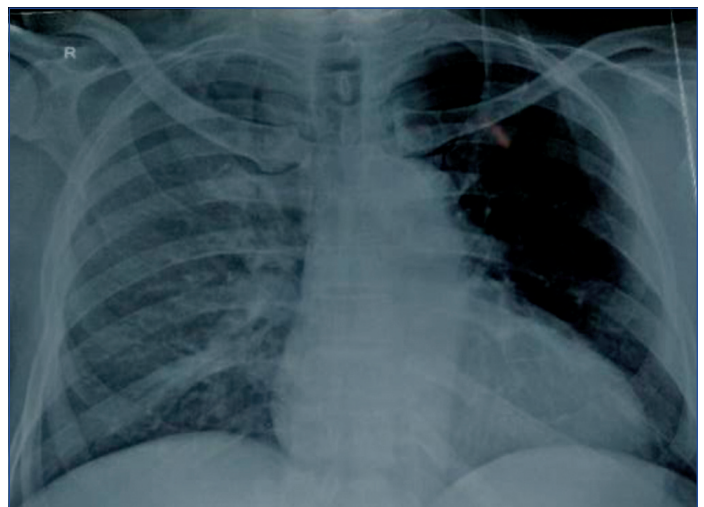
A 54-year-old male, averagely built, a retired cotton textile industry worker, presented to the Outpatient Department with low back pain and radicular left lower limb pain [on a pain scale of 0-10, 0 being no pain and 10 as worst possible pain; he scored his current pain as 4/10] for one month. He was never on any treatment for the same. He did not give any history of cough, breathlessness, or haemoptysis. He was recently diagnosed with CKD (Serum creatinine: 2.32 mg/dL, urea: 45.79 mg/dL) with secondary hypertension and was not on any treatment.

On general examination, he had a pulse rate of 90 beats/min, regular, peripheral pulses were well felt and were synchronous, blood pressure of 150/90 mmHg, and BMI of 23 kg/m<sup>2</sup>. He had mild pallor (Haemoglobin: 11 gm%). There was absence of cyanosis, clubbing, icterus, oedema, lymphadenopathy, and Jugular Venous Pulse (JVP) was not raised. On systemic examination, his respiratory system findings revealed reduced chest expansion (3 cm), normal Transverse: Anteroposterior ratio, chest movements were decreased on the left side compared to the right, hyper-resonant note on percussion, and decreased breath sounds on the left side. There were no adventitious breath sounds.

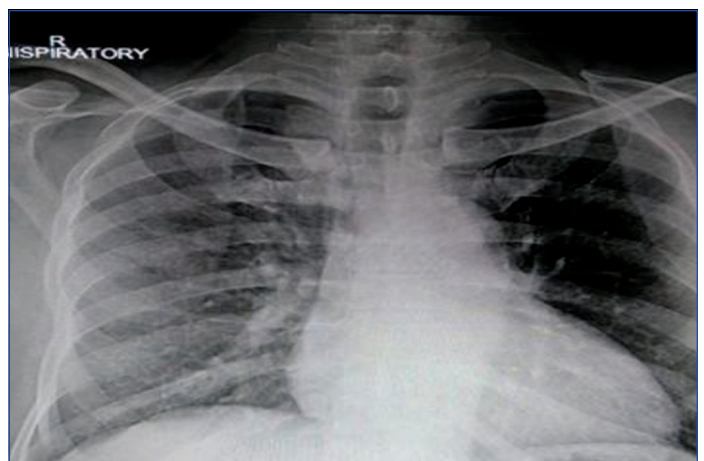
Initial evaluation showed an abnormal chest radiograph (expiratory film) with unilateral generalised lucency on the left side compared to the right side [Table/Fig-1]. His inspiratory Chest X-ray (unrotated) was done [Table/Fig-2] which showed enhanced hyperlucency on the left side compared to earlier expiratory film. As he had no respiratory symptoms like shortness of breath, cough, pedal oedema and raised JVP. Due to financial constraints, Computed Tomography (CT) pulmonary angiography could not be done and was emphasised on regular follow-up and to visit the hospital if he experienced symptoms like acute shortness of breath, cough and haemoptysis. Bedside lung functions like single breath count and breath-holding capacity were within normal range. His Peak Expiratory Flow Rate (PEFR) was 450 litre/min. His Electrocardiogram was suggestive of the Left Bundle branch block and left ventricular hypertrophy [Table/Fig-3] and was a coincidental finding. His 2-Dimensional echocardiography was suggestive of concentric left ventricular hypertrophy, degenerative (calcific and sclerosed)

aortic valve, and mild aortic regurgitation with normal left ventricular ejection fraction.

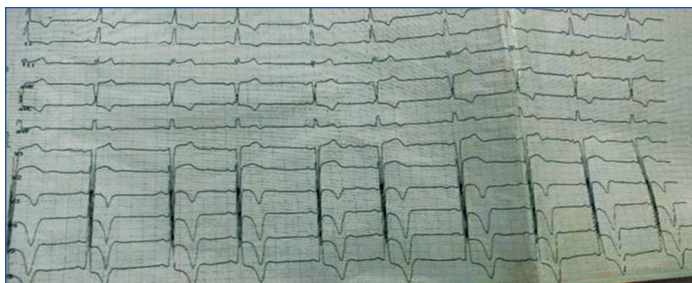
The patient had no respiratory symptoms and was incidentally diagnosed with SJMS, based on a chest radiograph. He was not



[Table/Fig-1]: Expiratory film showing left-sided radiolucency.



[Table/Fig-2]: Inspiratory film showing enhanced radiolucency on the left side.



**[Table/Fig-3]:** ECG on admission showing left bundle branch block and left ventricular hypertrophy.

further investigated for the syndrome and medically managed for the CKD and hypertension.

**DISCUSSION**

The SJMS is challenging to diagnose routinely because of its rarity. It happens because of an inflammatory reaction to a viral or bacterial infection in childhood which causes the affected lung area to develop abnormally, resulting in radiographic asymmetry. SJMS isn't known to progress and isn't linked to any systemic illnesses. In the present case, a middle-aged man whose chest radiograph was certainly abnormal at the time of admission had no prior respiratory complaints. Tuberculosis, pertussis (whooping cough), mycoplasma, and viral infections like a respiratory syncytial virus, adenovirus type 3, 7, 21, influenza A, measles, paramyxovirus morbillivirus, radiation therapy, and breathing in a foreign body have all been reported to cause SJMS in children [1,2]. Research suggests that a hyperimmune reaction in the lung (producing antibodies) may result in sustained airway damage following initial infection. A pre-existing lung defect may make people vulnerable to developing the disease. Even though bronchial injury during childhood is thought to be an important inciting factor, many affected do not have documented history of respiratory tract infection. Certain unknown variables present at birth probably have a role in SJMS development [3].

On radiographs, SJMS is known to cause a small lung with hyperlucency unilaterally and air trapping on expiration. The affected lung is hyperlucent and has decreased vascularity on CT scan and angiogram. The entire lung can be damaged, but there can also be lobar, segmental, and subsegmental involvement with a patchy distribution. The majority of the affected lobes are smaller, while they might rarely be normal size. In most cases, there is no anteroposterior attenuation of the gradient. Bronchiectasis may or may not be present [4]. A tiny pulmonary artery with decreased vascularity in the periphery may be seen on Magnetic Resonance Angiography (MRA). A photopenic region is visible in the affected aspect of a quantitative ventilation/perfusion lung scan [1].

**Differential diagnosis:** Both congenital and acquired lung illnesses are included in the differential diagnosis [Table/Fig-4] [5-7].

S. No.	Differential diagnosis	Differentiating feature
1	Pleural thickening	Generally seen peripherally with or without obliteration of costophrenic angles, with or without calcification, history of pleural effusion most likely with or without aspiration.
2	Pulmonary embolism	Westermarck's sign.
		Hampton's hump.
		Enlarged hilum due to large embolus.
		Clinically patient will be in severe respiratory distress.
3	Post mastectomy	Pulmonary vascularity will be symmetrical on both lung fields, with no change in the inspiratory and expiratory film.
4	Gross rotation	Uniform disparity in radiolucency and radio-opacity in both lung fields.

5	Unilateral minimal (<500 mL) collection of pleural fluid in Supine AP film	Increased homogeneous density superimposed over the lungs with loss of hemidiaphragm silhouette.
6	Foreign body obstruction in the paediatric age group, particularly in large airway	A mediastinal shift happens to the normal side in the expiratory film.
7	Tumour in principal bronchus [Benign or Malignant]	Because of partial or near-total obstruction leading to the ball-valve mechanism.
8	Post pneumonectomy	History of major surgery, the ipsilateral raised dome of the diaphragm, resected ribs
9	Poland's syndrome	Underdeveloped muscles affect the shoulder, arm, hand, and chest wall on one side of the body.
10	Unilateral pulmonary artery agenesis	Hypoplasia of unilateral lung, elevated haemidiaphragm, the shift of the mediastinum to the left, and prominent right pulmonary artery shadow.
11	Congenital lobar emphysema/unilateral emphysematous bullae	Alveolar overdistension in one or more pulmonary lobes, unilateral large emphysematous bulla will have a thin wall like a hairline.

**[Table/Fig-4]:** Differential diagnosis (both congenital and acquired lung illnesses are included in the differential diagnosis) [5-7].

One of the following is required as a diagnostic criterion for this syndrome [7]:

1. Chest X-ray reveals a unilateral reduction of lung capacity with hyperlucency.
2. A computed tomography of the chest reveals a decrease in vascularity unilaterally.
3. There is a unilateral decrease of perfusion on a technetium Tc 99m lung scan.

To confirm the diagnosis, pulmonary angiography can be done to demonstrate decreased unilateral pulmonary vascularity, but in index case, because of lack of facility for pulmonary angiography, the patient was not advised the same and was advised for regular follow-up after explaining in detail about the condition and related risk including the development of recurrent respiratory tract infections and pneumothorax.

**Treatment and prognosis:** As the patient was asymptomatic, particularly for respiratory symptoms, and was incidentally diagnosed with SJMS, no further investigation was done for the incidental diagnosis of SJMS and medically managed his CKD and hypertension and advised for regular follow-up of every six months. The usual treatment is conservative and preventive to prevent lung infections. Inhaled corticosteroids could play a little role in therapy [1]. Cases that present with complications are treated accordingly, those presenting with haemoptysis have been treated with pneumonectomy or lobectomy, or segmentectomy. Cases with Bronchiectasis are more vulnerable to respiratory infections. Bullae increase the risk of spontaneous pneumothorax. As a result of SJMS, a pulmonary abscess has also been recorded as a consequence [7].

Though the patient was a professional cotton mill industry worker, he was not heavily exposed to dust and so he never had any respiratory symptoms. On clinical examination, there was absence of clubbing, cyanosis, adventitious breath sounds which would have suggested Pneumoconiosis. Though he was diagnosed with CKD with secondary hypertension, pulmonary oedema was least likely as radiological changes were unilateral, there were absence of respiratory complaints, normal pulse oximetry, absence of oedema and adventitious breath sounds which led to the diagnosis of SJMS based on the radiological finding. Very few cases of adults with SJMS have been documented worldwide [Table/Fig-5] [8-15].

S. No.	Author name	Case description	Case finding
1.	Chehade AE and Bhardwaj H [8]	A 24-year-old patient was diagnosed with colour vision deficit as well as Adult Polycystic Kidney Disease (positive family history and hypertension).	A chest radiograph indicated a left mediastinal shift and a hyperinflated right lung and a left lung volume decrease with opacities and reticulations. A CT scan of his chest revealed basilar reticulations, pulmonary fibrosis, and cystic airspace disease with a hypoplastic left pulmonary artery.
2.	Mechineni A et al., [9]	A 67-year-old male patient with hypercapnic respiratory failure needed invasive mechanical ventilation.	His chest radiograph was suggestive of SJMS. He was successfully extubated, discharged home, and remained stable at 90 days follow-up.
3.	Chlapoutakis S et al., [10]	A 63-year-old man with frequent hospitalisations due to COPD exacerbations and no history of major lung infection as a child. Nebulised salbutamol/ipratropium, intravenous prednisolone, and empirical antibiotic therapy were used to treat the patient.	A chest CT revealed bronchiectasis in the left lower lobe. In the same location, there was also a decrease in density. PFTs showed a moderate obstructive pattern that was not reversible.
4.	Sharma N et al., [11]	A 63-year-old woman came in with a one-month history of productive cough, intermittent haemoptysis, and developing dyspnoea with exertion. Her medical history revealed a history of repeated lung infections as a child. She had no medical follow-up or treatment for it.	An X-ray of her chest revealed a hyperlucent left hemithorax. A CT scan of her chest revealed mosaic right lung perfusion, hyperlucent left lung with bronchiectasis alterations, and a hypoplastic left pulmonary artery. She also had a CT pulmonary angiography, which revealed a hypoplastic left pulmonary artery and its branches, as well as differential attenuation in both lungs, all of which are symptoms of SJMS. Spirometry revealed a mixed defect (moderate blockage and restriction).
5.	Al-Bakri O et al., [12]	A pulmonologist detected SJMS in a 29-year-old pregnant lady at the age of 22. She was diagnosed with asthma after being brought to the hospital with acute pneumonia in her first year of life.	Her chest imaging at the age of 22 revealed patchy areas of mosaic attenuation in the left lung, consistent with SJMS. FEV1 1.94 litre (63% expected) and FEV1/FVC ratio of 65% were found on baseline first-trimester PFT.
6.	Machado D et al., [13]	A 41-year-old Caucasian man with exertional dyspnoea and a productive cough was referred. He was a former smoker with no notable lower respiratory tract illness in childhood and was overweight (BMI of 27 kg/m <sup>2</sup> ).	The left lung was hyperlucent on the chest X-ray, and the CT scan revealed cystic bronchiectasis and reduced density in the same location. His echocardiography was normal, and PFT revealed a reversible moderate obstructive pattern.
7.	Machado D et al., [13]	A 53-year-old Caucasian male was referred to further study a chest X-ray finding. He was obese (BMI of 31 kg/m <sup>2</sup> ), non smoker, and had a history of childhood left pneumonia. Even without infection, the patient complained of exertional dyspnoea, and pulmonary auscultation revealed crackles in the lower left hemithorax.	The left lung field was hyperlucent on X-ray, and the CT scan revealed a reduction in density in the left lung, as well as cystic bronchiectasis on the left lower lobe and lingula. A reversible mild airflow blockage was discovered on PFT.
8.	Machado D et al., [13]	A 70-year-old Caucasian non smoker female, with obesity (35kg/m <sup>2</sup> ), obstructive sleep apnoea treated with continuous positive airway pressure, and a recently diagnosed asthma was referred due to recurrent pulmonary infections requiring hospital admission.	The left lung was hyperlucent on chest X-ray, and the CT scan revealed volume loss in the left lung, with a reduction in density more pronounced on the left lower lobe, a tiny left pulmonary artery, cylindrical bronchiectasis, and a mosaic perfusion defect in the right lung. Her CT angiography revealed no signs of pulmonary embolism, and she had a routine bronchoscopy. PFTs revealed a non reversible moderately severe mixed airflow pattern, and the echocardiography revealed indirect symptoms of pulmonary hypertension.
9.	Kaplanoglu H et al., [14]	A 58-year-old woman with hearing loss was admitted to the hospital. The right ear was found to have conductive hearing loss. She was found to have diminished chest expansion, breath sounds, and respiratory movements on the right hemithorax on physical examination prior to ear surgery.	The volume of the right hemithorax was reduced, and the hemidiaphragm was elevated on chest radiography. On CT scans of the thorax and CT angiography, the right lung's tiny fissure was not visible. There was hypoplasia and lack of ventilation in the right lung's middle lobe and hypoplasia of the right intermediate and middle lobe bronchus. Diffuse hypoplasia was found in the upper and lower branches of the right major pulmonary artery. AVM (Arterio-venous malformation) was identified feeding from bronchial arteries and draining to the right pulmonary vein on a 3D CT scan.
10.	Vyas S et al., [15]	A 17-year-old female patient complained of gradual onset exertional breathlessness, as well as right-sided chest pain, cough, and mucopurulent expectoration for the past six months. The pain was diffuse, affecting the right anterior and posterior chest walls, and it was triggered by coughing and effort. On respiratory examination, the trachea was shifted to the right side with right-sided sternocleidomastoid prominence. The apex beat was located in the right fifth intercostal region, 5 cm lateral to the sternum, with diminished breath, sounds on the right side.	Her chest X-ray revealed a displaced trachea to the right side, as well as volume loss and hyperinflation of the left lung. Her CT thorax revealed right pulmonary agenesis, left lung hyperinflation, and right side herniation. The major pulmonary artery was normal in size, while the right pulmonary artery was hypoplastic. A fibre-optic bronchoscopy indicated that the right major bronchus was completely stenosed.

**Table/Fig-5:** Cases of adults with SJMS reported worldwide with varied presentation [8-15].

CT: Computed tomography; SJMS: Swyer-James-Macleod syndrome; COPD: Chronic obstructive pulmonary disease; PFT: Pulmonary function test; FEV: Forced expiratory volume

**Patient counselling:** Patient and the family should be explained about the chest X-ray finding along with the reason for SJMS to avoid unscrupulous investigations in further medical visits. Instructions should be given on recognising the early symptoms of respiratory infections. In case of acute respiratory distress, the patient should seek immediate medical attention to confirm the diagnosis of pneumothorax and any other complications.

## CONCLUSION(S)

The SJMS is a rare entity that should have a high degree of suspicion if the patient is asymptomatic and with obvious chest X-ray and CT scan findings. The diagnosis is easily made using chest radiography (inspiratory and expiratory films) and CT, which shows a hyperlucent hemithorax on one side with decreased bronchovascular markings in the affected area of the lung. The main purpose of reporting this case was to avoid further unscrupulous and unwarranted investigations and treatment in such cases.

## REFERENCES

- Macleod WM. Abnormal transradiancy of one lung. *Thorax*. 1954;9(2):147-53.
- Ohri SK, Rutty G, Fountain SW. Acquired segmental emphysema: The enlarging spectrum of Swyer-James/Macleod's syndrome. *Ann Thoracic Sur*. 1993;56(1):120-24.
- Adelina AN, Sinziana GI, Angela OG, Valentina IE, Gabriela IM, Radu BA. Challenges in multidisciplinary medical rehabilitation-Swyer-James-Macleod syndrome: Case presentation and short literature review. *Balear Res J*. 2019;10(10):457-61.
- Shi HS, Yang F, Han P, Zheng JL, Feng GS, Liu YH, et al. Findings of chest radiograph and spiral computed tomography in Swyer-James syndrome. *Chinese Medical Sciences Journal=Chung-kuo i Hsueh k'o Hsueh tsa Chih*. 2006;21(1):53-56.
- Soni R, Branes D. Macleod's syndrome presenting with spontaneous pneumothorax. *Respirology*. 1999;4(3):275-77.
- Hajsadeghi SH, Chitsazan M, Pouraliakbar HR, Kerman SJ. Swyer-James-Macleod syndrome presenting with pulmonary hypertension. *Int Cardiovas Res J*. 2010;4(3):134-38.
- Chaucer B, Chevenon M, Toro C, Lemma T, Grageda M. Swyer-James-Macleod syndrome: A rare finding and important differential in the ED setting. *Am J Emerg Med*. 2016;34(7):1329-e30.
- Chehade AE, Bhardwaj H. Swyer-James syndrome: A cause of adult-onset dyspnea in a patient with adult polycystic kidney disease. *Respir Med Case Rep*. 2022;36:101569.
- Mechineni A, Singh B, Manickam R. A rare presentation of a rare case: Acute respiratory failure in Swyer-James-Macleod syndrome. *Cureus*. 2021;13(2):e13347.
- Chlapoutakis S, Garmpi A, Trakas N, Damaskos C, Georgakopoulou VE. Recurrent exacerbations of chronic obstructive pulmonary disease reveal Swyer-James-Macleod syndrome in a 63-year-old Patient. *Cureus*. 2021;13(1):e12601.



- [11] Sharma N, Gupta P, Yadav A. Swyer-James-Macleod syndrome: A rare finding in a case of haemoptysis. *The Journal of Association of Chest Physicians*. 2021;9(1):41-44.
- [12] Al-Bakri O, Malebranche M, Shetty N, Miller A, McCoy K, Nash CM. Swyer-James-MacLeod syndrome in pregnancy: A case report. *Obstetric Medicine*. 2022;0(0). Doi:10.1177/1753495X221092601.
- [13] Machado D, Lima F, Marques C, Monteiro R. Swyer-James-Macleod syndrome as a rare cause of unilateral hyperlucent lung: Three case reports. *Medicine*. 2019;98(6):e14269.
- [14] Kaplanoglu H, Kaplanoglu V, Toprak U, Dilli A, Hekimoglu B. A case of Swyer-James-Macleod syndrome associated with middle lobe hypoplasia and arteriovenous malformation. *Case Rep Med*. 2012;2012:959153.
- [15] Vyas S, Mathew T, Advani M, Meena D. Pulmonary agenesis: A rare entity. *Lung India*. 2018;35(3):275-76.

**PARTICULARS OF CONTRIBUTORS:**

1. Assistant Professor, Department of Internal Medicine, Datta Meghe Institute of Medical Sciences, Nagpur, Maharashtra, India.
2. Associate Professor, Department of Respiratory Medicine, Datta Meghe Institute of Medical Sciences, Nagpur, Maharashtra, India.
3. Professor, Department of Internal Medicine, Datta Meghe Institute of Medical Sciences, Nagpur, Maharashtra, India.
4. Junior Resident, Department of Internal Medicine, Datta Meghe Institute of Medical Sciences, Nagpur, Maharashtra, India.
5. Junior Resident, Department of Internal Medicine, Datta Meghe Institute of Medical Sciences, Nagpur, Maharashtra, India.

**NAME, ADDRESS, E-MAIL ID OF THE CORRESPONDING AUTHOR:**

Dr. Shweta Ramnarayan Borkar,  
Unit No. A 603, Block 8, Yashoda, Vrindavan, Near NCI, Behind VCA Stadium, Jamtha,  
Nagpur-441122, Maharashtra, India.  
E-mail: drshwetaborkar@gmail.com

**PLAGIARISM CHECKING METHODS:** [\[Jain H et al.\]](#)

- Plagiarism X-checker: Apr 28, 2022
- Manual Googling: Jul 16, 2022
- iThenticate Software: Aug 03, 2022 (8%)

**ETYMOLOGY:** Author Origin**AUTHOR DECLARATION:**

- Financial or Other Competing Interests: None
- Was informed consent obtained from the subjects involved in the study? Yes
- For any images presented appropriate consent has been obtained from the subjects. Yes

Date of Submission: **Apr 20, 2022**  
Date of Peer Review: **May 18, 2022**  
Date of Acceptance: **Aug 05, 2022**  
Date of Publishing: **Sep 01, 2022**