

Urinary Bladder Calculus as a Rare Cause of Obstructed Labour: A Series of Three Rare Cases

PUNYA PRATAP SINGH¹, JAGRATI KIRAN NAGAR², KAVITA GAHLOT³, OMKAR THAKUR⁴, BHEEKAM PATEL⁵



ABSTRACT

Obstructed labour by large urinary bladder stones is one of the rare complications. Very small number of cases have been described in available literature. The diagnosis is generally based on the history of patient, their clinical evaluation and ultrasonography scans during pregnancy. Majority of antenatal cases in rural areas come first time in Primary Healthcare Centre (PHC) with labour pain and usually without any previous ultrasound scans. These cases are referred to higher centres due to prolonged obstructed labour. Although rare, but one should consider a large urinary bladder calculus as a cause of obstructed labour as early diagnosis and timely management of urinary bladder stones can prevent various complications like mechanical dystocia and Vesico-vaginal Fistula (VVF). Here, authors reported three cases of a large urinary bladder calculus causing obstructed labour. Caesarean section was done for obstructed labour and cystolithotomy was performed simultaneously in all three cases.

Keywords: Caesarean section, Cystolithotomy, Dystocia, Pregnant women, Ultrasound

INTRODUCTION

Out of the various causes of obstructed labour, vesical calculus is a very rare cause [1]. The incidence being 1 in 2000-3300 pregnancies [2]. Urinary bladder stones in women accounts approximately 5% of all bladder stones [3]. A large calculus weighing more than 100 gm, causing obstructed labour which is a very rare type of clinical entity case [4]. Urinary bladder without any symptom can attain a big size. In rare cases, such large urinary bladder calculus may be diagnosed first time during labour as in the presented cases. Timely intervention of these types of cases can prevent various serious complication [5]. The diagnosis is based on the history of patients, their clinical evaluation and Ultrasonography (USG). Most part of the population having deficient healthcare system and prolonged non progressive labour or dystocia which is an intrapartum emergency [6]. Due to lack of USG facility and lack of awareness in rural areas, diagnosis of obstructed labour by large urinary bladder calculus cannot be made and therefore referred to higher centre with labour pain due to obstructive features of labour or no progression of labour. This indicates importance of prenatal USG for better outcome of pregnancy. In doubtful cases or USG is inconclusive, non contrast enhanced Magnetic Resonance Imaging (MRI) is also helpful. After confirmation of diagnosis of urinary bladder calculus as a cause of mechanically obstructed labour, urgent emergency Lower (Uterine) Segment Caesarean Section (LSCS) followed by cystolithotomy should be performed to avoid various complications. Here, authors have reported three cases of a large urinary bladder calculus causing obstructed labour.

CASE SERIES

Case 1

A 20-year-old, primigravida patient with history of amenorrhoea of nine months and non localisation of foetal heart sound with obstructed labour was referred from district hospital and admitted in labour room of the medical college. On general examination, her general condition was average. Patient was ill looking, dehydrated, exhausted and afebrile to touch, pulse rate was 88/minute, Blood Pressure (BP) was 140/100 mmHg, pallor and oedema was present.

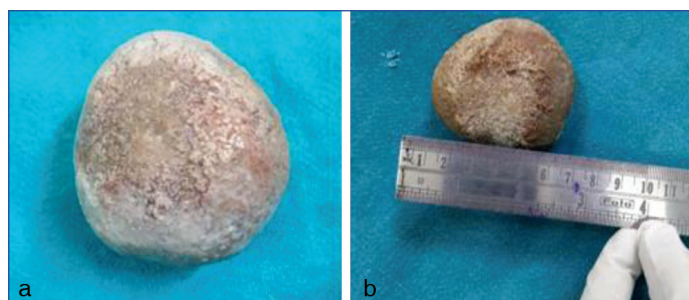
On per abdomen examination: Uterus was full term, longitudinal lie, and no scar marks or dilated veins were seen.

On palpation: Uterus full term, longitudinal lie, cephalic presentation, vertex down, fixed and contraction was present.

On auscultation: Foetal heart sound was not localised.

On Pervaginal examination (P/V): Cervix was fully dilated, fully effaced, vertex presentation at +1 station, membrane was absent, meconium stained liquor and primary caput were present. A firm stony hard, smooth globular mass of about 5x6 cm was felt through anterior fornix.

USG obstetrics showed single Intrauterine Foetal Demise (IUFD) with large echogenic foci with distal acoustic shadow of maximum length 6.2 cm likely to have large urinary bladder calculus. Diagnosis was confirmed by USG of whole abdomen and pelvic x-ray as baby was IUFD. Risk of Pregnancy Induced Hypertension (PIH), non localisation of Foetal Heart Rate (FHR), severe anaemia and bladder stone was explained to the attender. After taking well informed written consent, patient was taken for LSCS with cystolithotomy. During caesarean section, thinned out lower uterine segment (as a feature of obstructed labour) was noted. Patient delivered a still birth baby of 2.5 kg weight on same day of admission by vertex followed by complete delivery. Cystolithotomy was performed by surgery on call consultant. Large calcified urinary bladder stone of about 6x6.5 cm [Table/Fig-1] was removed. Urinary bladder catheter was kept for 21 days. Haematuria was disappeared on 2nd day. Postoperative days were uneventful. One unit of blood was given in postoperative period and three doses of iron sucrose also given. Stitches were removed on 8th day and stitch line was healthy. Patient was discharge on 8th day and advised to present in Outpatient Department (OPD) for follow-up after seven days.



[Table/Fig-1]: Case 1 Large urinary bladder calculus removed by cystolithotomy performed just after cesarean section for full term obstructed labour.

Case 2

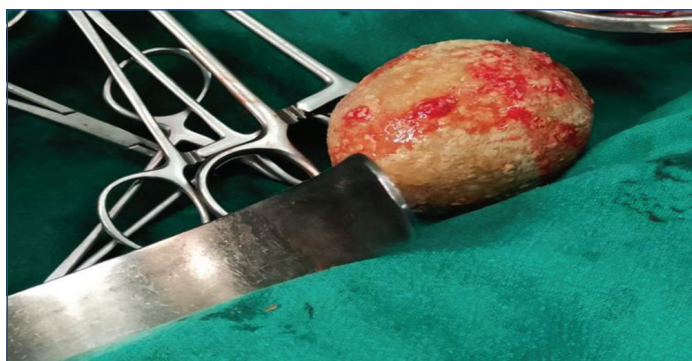A 23-year-old primigravida, postdated pregnant patient with breech presentation with large calculus in bladder was admitted in the

medical college labour room, her bladder stone was detected in antenatal period at 28 weeks of gestation in USG by radiologist. So, she was planned for elective caesarean section. On general examination, her condition was good, afebrile to touch, pulse rate was 70/minute, BP was 110/80 mmHg; pallor, oedema and icterus was absent.

On per abdomen examination: Uterus was 36 to 40 weeks, relaxed, soft, foetal heart rate was present and regular (140 beats per minute), lie longitudinal and breech presentation.

On Pervaginal (P/V) examination: Cervical -os was closed, presenting part high up, no show and no leaking. A firm, stony hard smooth, globular, non tender immovable mass of about 5x6 cm was felt through anterior fornix.

Patient was taken for LSCS with cystolithotomy after taking well informed written consent. Patient delivered a male live baby of 2.4 kg weight on same day of admission. Baby cried immediately after birth attended by Paediatrician and Appearance, Pulse, Grimace, Activity, and Respiration (APGAR) after five minutes was 10. Cystolithotomy was performed by surgery on call consultant and removed a large stone of about 6x5.6 cm [Table/Fig-2]. Haematuria was disappeared on 2nd day and catheter kept for 21 days. Her caesarean stitches wound got infected and resuturing was done. Stitches removed on 8th day of resuturing. Patient was discharged on 22nd day after removal of catheter. Postoperative period was uneventful.



[Table/Fig-2]: Case 2 Large urinary bladder calculus removed by cystolithotomy performed just after planned caesarean section for full term obstructed labour due to antenatal diagnosed case of large urinary bladder calculus.

Case 3

A 20-year-old, primigravida patient registered at a PHC, three prenatal visits were done. Once this patient was seen by a private practitioner. Stone was missed in USG obstetrics, then patient came to the author, with history of eight months nine days amenorrhoea and pain in abdomen. She had history of recurrent urine infection. She has history of dyspareunia also.

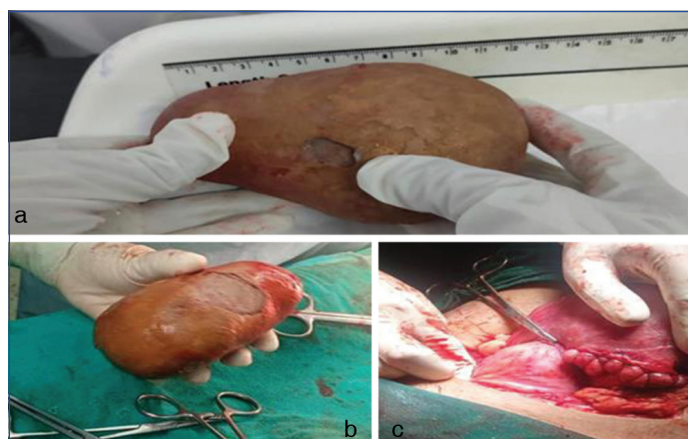On general examination, patient was thin, general condition was fair, afebrile to touch, pulse rate was 82/minutes, BP was 110/70 mmHg, Urine albumin 2+, oedema was absent.

On per abdomen examination: Fundal height was 32 to 34 weeks size {Uterus was not corresponding to gestational age may be due to Intrauterine Growth Retardation (IUGR)}, vertex down, fixed, major poles were above brim, contraction present, longitudinal lie and cephalic presentation was noted.

On auscultation: FHR was regular (144 beats per minute).

On P/V examination: A hard fixed, smooth, globular, immobile, non tender mass was felt anteriorly. As pelvic mass was big, its margins cannot be felt and cervix shifted backwards by mass. Cervix was dilated by 42 to 50 percent, effaced, cervix could not be felt easily, very posteriorly placed, felt by examining with finger only. Cervix was 1 to 2 cm in dilatation and membrane was present.

Steroid was given. Urinary bladder stone cannot be visualised in next day USG (may be due to foetal head shadowing, pelvic bone shadowing and calculus deeply impacted in pelvis). Next day, on P/V examination same findings were noted. Good uterine contraction was also noted and hard fixed mass felt anteriorly. Caesarean section was done. Patient delivered a preterm, 1.7 kg weight, male baby on 3rd day of admission. Uterus was not corresponding to gestational age because baby had IUGR. After that, cystolithotomy was performed by on call surgeon. Large urinary bladder calculus of about 10 to 12 cm of maximum dimension [Table/Fig-3] and 500 gm weight was removed by cystolithotomy. Postoperative period was uneventful. Mother and baby were healthy at time of discharge on 8th day. Features of all three cases are shown in [Table/Fig-4].



[Table/Fig-3]: Case 3 Large urinary bladder calculus was removed by cystolithotomy performed just after emergency, caesarean section for full term obstructed labour with intrauterine growth retardation.

Variables	Case 1	Case 2	Case 3
Age (years)	20	23	20
Parity	P - 0	P - 0	P - 0
Gravida	G -1, Primigravida	G -1, Primigravida	G -1, Primigravida
Mode of delivery and outcome	Caesarean section - Full term Intrauterine Foetal Demise (IUFD) of 2.5 kg weight by vertex.	Caesarean section - Full term male alive baby of 2.4 kg by breech.	Caesarean section - Post-term with Intrauterine Growth Retardation (IUGR) male baby of 1.7 kg weight by vertex
Antenatal USG	IUFD with bladder stone	Single live intrauterine foetus with urinary bladder calculus	Single live intrauterine foetus
Additional investigation done	Complete Blood Count (CBC), Renal Function Test (RFT), Liver Function Test (LFT), and X-ray pelvis (as diagnosed case of IUFD)	CBC, RFT, LFT	CBP, RFT, LFT and Stone analysis
APGAR (Appearance, Pulse, Grimace, Activity, and Respiration) score of foetus after 10 minutes	00	10	10
Operative method for urinary bladder calculus	Cystolithotomy performed simultaneously	Cystolithotomy performed simultaneously	Cystolithotomy performed simultaneously
Postoperative complication	None	Wound gaping - Resuturing done	None

[Table/Fig-4]: Features of all three cases of large urinary bladder calculus with obstructed labour.

DISCUSSION

Urinary bladder stones are uncommon in female population and even rarer in pregnancy period. Urinary bladder stones in women accounts approximately 5% of all bladder stones [3]. Nephrolithiasis incidence during pregnancy ranges in between 1/200-1/2500. Generally urinary bladder stones are diagnosed in prenatal ultrasounds, urinary bladder calculus situated posterior to symphysis pubis and anterior to cervix, cannot be detected by USG due to foetal skull bone and pelvic bone shadowing [4]. Urinary bladder calculus can cause various complication in which few are common like- Urinary Tract Infection (UTI), haematuria, preterm delivery, few are uncommon although serious like Vesico-vaginal Fistula (VVF) and rupture of uterus. Generally, serious type of complications is not common due to early diagnosis in antenatal period and their proper management. Urinary bladder stone management changes as per gestational age of foetus.

In antenatal period, a large urinary bladder stone is best managed by Supra-pubic cystotomy with minimal complication. This procedure is done in later stage of pregnancy to prevent preterm labour; [7] vaginal cystotomy cannot be done due to chances of severe complication like permanent fistula [7]. But if patient presented with labour pain or in labour second stage. In these, caesarean section should be done followed by cystolithotomy in same sitting [7]. There are several differentials for obstructed second stage of labour due to mechanical obstruction like retroperitoneal masses (sarcomas [8], ganglio-neuroma [9]), pelvic space occupying lesions (hydatid/echinococcus cysts) [10]. The best management of obstructed labour due to urinary bladder calculus is caesarean section followed by cystolithotomy in same sitting. Urinary bladder calculus may be clinically silent and not showing any symptoms. However, these stones can be presented with haematuria, pelvic pain, dysuria and recurrent UTI [11]. In case 3 recurrent urinary problems and history of dyspareuria was noted. Other two cases did not had any complaint related to urinary bladder stone. Large urinary bladder calculus causing mechanical dystocia can be easily diagnosed when it is palpable by pervaginal examination [11]. As in case 1 and case 3, urinary bladder stone was suspected on P/V examination.

Due to no radiation related hazards, cystoscopy and USG are two best diagnostic method/procedure to diagnose urinary bladder calculus in pregnant women [11,12]. MRI can be used as problem solving method due to absence of radiation hazards, absence of teratogenic potential and inherent contrast by using different sequences. Some previous studies showed 100% sensitivity [13]. In case 1- USG was done in last trimester to search for cause obstructed labour and findings suggestive of single IUID foetus with suspected large urinary bladder stone which was confirmed by X-ray pelvis, case 2 Large urinary bladder stone detected on antenatal USG on 28 weeks of gestational age and case 3 USG was done two times but could not pick up large urinary bladder stone. In neglected cases of obstructed labour due to large urinary bladder calculus, rupture of urinary bladder and vaginal wall can occur and large stone might be expelled out via rupture site [14]. In present series all three cases, caesarean section was done for obstructed labour and cystolithotomy performed simultaneously. Really interesting,

case 2- planned elective surgery got infected (caesarean wounds get infected and resuturing was done) and other two cases done in emergency were healthy (postoperative period was uneventful).

CONCLUSION(S)

Out of the various causes of obstructed labour, urinary bladder calculus is one of the very rare cause. Patient's past and present history, pathological tests, clinical and prenatal USG scans are main tools to reach proper diagnosis. Size of calculus and gestational age of foetus are main factors taken into consideration to decide management of such cases. In doubtful cases, non contrast MRI is also helpful. The size of the urinary bladder calculus is also a main factor with other factors to deciding route of delivery. Complications can be avoided by early, timely diagnosis followed by proper management of case. When LSCS is indicated, intraoperative cystolithotomy with extraction of the calculus is best method to deal with urinary bladder calculus, however it may increase the occurrence of urinary fistula. In all three cases, after diagnosis of large urinary bladder calculus causing labour dystocia, LSCS was performed which was followed by cystolithotomy to minimise or prevent maternal and foetus morbidity and mortality.

REFERENCES

- [1] Seth S, Malik S, Salhan S. Vesical calculus causing dystocia. *Eur J Obstet Gynecol Reprod Biol.* 2002;101:199. Doi: [https://doi.org/10.1016/S0301-2115\(01\)00542-5](https://doi.org/10.1016/S0301-2115(01)00542-5).
- [2] Cunningham FG, Leveno KJ, Bloom SL, Hauth JC, Gilstrap L, Wenstrom KD, editors. *Williams Obstetrics.* 22nd ed. Newyork: McGraw-Hill; 2005.
- [3] Stav K, Dwyer PL. Urinary bladder stones in women. *Obstet Gynecol Surv.* 2012;67(11):715. Doi: <https://doi.org/10.1097/OGX.0b013e3182735720>. PMID: 23151755.
- [4] Chakraborty B, Mondal PC, Sahana R, Barman SC. A giant vesical stone causing impending rupture of bladder during labor. *J Obstet Gynaecol India.* 2015;65(4):267-70. Doi: <https://doi.org/10.1007/s13224-014-0543-2>. PMID: 26243995.
- [5] Joshi K, Kawade V. Obstructed labor due to bladder stone: Case report. *Indian J Obstet Gynecol Res.* 2020;7(3):430-32. Doi: <https://doi.org/10.18231/ijog.2020.090>.
- [6] Abubakar BM, Abdulkadir A, Atterwahmie AA, Panti AA, Maina AI. Prolonged obstructed labor is an uncommon presentation of a giant bladder calculus: A case report and literature review. *Open J Urol.* 2019;9(4):77-83. Doi: <https://doi.org/10.4236/oju.2019.94009>.
- [7] Armon PJ. Obstructed labor due to a vesical calculus. *BMJ.* 1977;2(6085):498. Doi: <https://doi.org/10.1136/bmj.2.6085.498>. PMID: 890366.
- [8] Foruhan B. Retroperitoneal sarcomas obstructing delivery: Two case reports. *Intl J Obste Gynaecol.* 1979;86(9):747-48. Doi: 10.1111/j.1471-0528.1979.tb11280.x. PMID: 497148.
- [9] Kamin G, Theissig F, Löffler F, Lückert G. Retroperitoneal ganglioneuroma as a cause of obstructed labor. *Enthalbl Gynakol.* 1986;108(16):1003-05.
- [10] Biale Y, Potashnik G, Ben-Adereth N. Obstructed labor due to pelvic echinococcal cysts. *Isr J Med Sci.* 1975;11(8):845-47.
- [11] Saussine C, Lechevallier E, Traxer O. Lithiase et grossesse. *Prog Urol.* 2008;18(12):1000-04. Doi: <https://doi.org/10.1016/j.purol.2008.09.008>. PMID: 19033071.
- [12] Benkaddour YA, Aboufalal A, Abbassi H. Bladder stone: Uncommon cause of mechanical dystocia. *Arch Gynecol Obstet.* 2006;274(5):323-24. Doi: <https://doi.org/10.1007/s00404-006-0163-x>. PMID: 16649039.
- [13] Dave A, Mathur P, Mathuriya G. Vesical calculus: An uncommon cause of obstructed labor. *J Obstet Gynaecol India.* 2012;62(6):687-88. Doi: <https://doi.org/10.1007/s13224-012-0145-9>. PMID: 24293848.
- [14] Sharma V, Chir B. Vesical calculus as a cause of labour dystocia. Report of a case. *Postgrad Med J.* 1960;36:626-28. Doi: 10.1136/pgmj.36.420.626. PMID: 13746552.

PARTICULARS OF CONTRIBUTORS:

1. Associate Professor and Head, Department of Radiodiagnosis, Bundelkhand Medical College, Sagar, Madhya Pradesh, India.
2. Associate Professor, Department of Obstetrics and Gynaecology, Bundelkhand Medical College, Sagar, Madhya Pradesh, India.
3. Obstetrician and Gynecologist, Department of Obstetrics and Gynaecology, Ayushman Hospital, Sagar, Madhya Pradesh, India.
4. Assistant Professor, Department of Surgery, Bundelkhand Medical College, Sagar, Madhya Pradesh, India.
5. Demonstrator, Department of Paediatrics, Bundelkhand Medical College, Sagar, Madhya Pradesh, India.

NAME, ADDRESS, E-MAIL ID OF THE CORRESPONDING AUTHOR:

Dr. Punya Pratap Singh,
Flat No 9, Type - 4 Quaters, BMC Residential Complex, Sagar-470002,
Madhya Pradesh, India.
E-mail: drpunya@gmail.com

AUTHOR DECLARATION:

- Financial or Other Competing Interests: None
- Was informed consent obtained from the subjects involved in the study? Yes
- For any images presented appropriate consent has been obtained from the subjects. Yes

PLAGIARISM CHECKING METHODS: [Jain H et al.]

- Plagiarism X-checker: May 14, 2022
- Manual Googling: Aug 08, 2022
- iThenticate Software: Sep 03, 2022 (25%)

ETYMOLOGY: Author Origin

Date of Submission: **May 13, 2022**

Date of Peer Review: **Jun 20, 2022**

Date of Acceptance: **Sep 05, 2022**

Date of Publishing: **Oct 01, 2022**