

# Clinical Evaluation of Intradermal Platelet Rich Plasma Administration along with Oral Biotin Supplement for the Management of Androgenetic Alopecia in Adult Males: A Randomised Clinical Trial

NEHA GUPTA



## ABSTRACT

**Introduction:** Androgenetic Alopecia (AA) is characterised by progressive-patterned hair loss from the scalp affecting males and females alike. Miniaturisation of the hair follicle with associated hereditary tendency is one of the major primary causal factors for the pathogenesis of AA. Various treatment modalities have been proposed for the management of AA including minoxidil, finasteride, etc.; however, they are associated with known side-effects.

**Aim:** To evaluate the effect of intradermal Platelet Rich Plasma (PRP) administration, along with oral biotin supplement for the management of AA in males.

**Materials and Methods:** The present randomised clinical study was conducted at Department of Dermatology, B.J. Medical College and Hospital, Ahmedabad, Gujarat, India from January 2012 to May 2013. A total of 40 healthy adult males of Indian origin, with a history of hair loss, completed the 12 month trial. They were equally randomised into two groups. Subjects

enrolled in group A (n=20) received intradermal administration of autologous PRP, every 15 days for three months along with oral biotin tablets, once daily for three months, while those in group B (n=20) received oral biotin tablets, once daily for three months. Hair regrowth was evaluated using a standardised 7-point rating scale at 3, 6, 9 and 12 months intervals, by the same investigator. Chi-square test was used to statistically assess the data. The p-value for significance was established at <0.05.

**Results:** Individuals in group A had mean age of 32.3±6.1 years and showed statistically significant (p-value <0.05) increase in hair regrowth at 6 months, 9 and 12 months; compared to Group B with mean age of 30.7±5.2 years.

**Conclusion:** Intradermal administration of PRP along with oral biotin tablet supplementation resulted in a statistically significant increase in hair regrowth, without any remarkable side-effects. PRP is a safe and effective treatment modality in adult males, with AA.

**Keywords:** Blood products, Hair, Hair growth, Hair loss, Hair regrowth

## INTRODUCTION

The AA is typically characterised by progressive patterned hair loss from the scalp. Researchers have tried to understand its pathogenesis and underlying genetic basis [1]. It has been established that the miniaturisation of the hair follicle with associated hereditary tendency are the major primary causal factors for the pathogenesis of AA [2]. Although the transition of some terminal hairs into vellus hair is a secondary sexual characteristic, it becomes a medical condition when the hair loss is extreme, untimely and distressing [3]. This progressive loss of hair also has psychosocial implications for affected individuals, which may lead them develop a negative image of themselves and thereby a reduced quality of life [4].

The polysomal inheritance genetic pattern and the related presence of androgens have been known to be causal agents for male AA [5]. AA characteristically presents as patterned hair loss, beginning in the bitemporal region accompanied by a recession of frontal hair, which is followed by reduction over the vertex. The bald patch, so formed enlarges and joins the receding frontal hair line, leaving an island of hair on the frontal scalp. Subsequently this island of hair disappears and only a thin area remains over the parietal and temporal region. The amount of hair loss is not uniform, affected individuals often experience phases of increased hair loss [6]. Studies show that, AA usually does not start till puberty and the rate of hair loss is extremely variable. It is also observed that by the age of 30 years, about 30% of men suffer from AA, which may increase to 50% upon completing 50 years of age [6,7]. Also, dark skinned males experience AA lesser than fairer skinned men [7].

Several treatment options have been advocated for the management of AA, ranging from usage of hair wigs to scalp surgery. Of these, the most accepted treatment protocols involve the use of topical minoxidil application and/ or oral finasteride medication [8]. Both, minoxidil and finasteride are fraught with their respective side-effects such as palpitations, dizziness, allergic reactions and sexual dysfunction, respectively [8,9].

Hair supplements are a vast and growing industry. Patients often turn to oral supplements to address hair concerns as they are easily accessible over the counter. Nutritional supplements are regulated by the Food Drug Administration (FDA) as foods instead of drugs, meaning, they do not have to prove their efficacy and safety before becoming available to consumers. While, some oral supplements have strong evidence supporting their use for hair growth, many ingredients have not been tested in clinical trials, have only in-vitro evidence for hair growth, or have only been tested in animals [10].

The PRP is proven to be a rich source of growth factors [7]. PRP promotes significant changes in monocyte mediated proinflammatory cytokine/chemokine release. The injections should be limited to the region of the superficial papillary dermis (1.5-2 mm) [11]. PRP is known to contain Platelet derived Growth Factor (PDGF)-AB, PDGF-BB, transforming growth factor  $\beta$ -1, Insulin-like growth factor-1 (IGF-1), fibroblast growth factor basic, Epidermal Growth Factor (EGF), Vascular Endothelial Growth Factor (VEGF), interleukin -12, etc. [11] These factors have been proven to increase blood circulation to the Dermal Papilla (DP) cells and also aid in their survival, thereby, leading to hair regrowth.

The present study was conducted to evaluate whether it is advantageous to administer autologous PRP through intradermal injection along with biotin supplementation for the management of AA in males. Also the effect of oral biotin alone on hair regrowth could be assessed. The null hypothesis established was that, there is no significant improvement in the management of AA with intradermal injection of PRP along with oral biotin supplementation as compared to administration of oral biotin also. Although PRP and biotin have been individually investigated for their role in hair regrowth in individuals with AA, the author after a literature search did not find any published data on a combination therapy employing intradermal administration of PRP and oral biotin supplements for the same. Hence, it can be stated that, the present study is a clinical evaluation of a new approach for management of AA.

## MATERIALS AND METHODS

This randomised clinical trial was conducted at Department of Dermatology, BJ Medical College and Hospital, Ahmedabad, Gujarat, India. The duration of the present study was one year four months (January 2012 to May 2013). Ethical clearance was obtained from the Institutional Review Board (IRB) (IEC Number BJMC/IEC/2011/245). Informed consent was obtained before patients before being enrolled in the study.

**Inclusion criteria:** Healthy adult males between the ages of 21-40 years of age, who consecutively presented with mild to moderate vertex male pattern hair loss according to a modified Norwood/Hamilton classification scale (III vertex, IV, V and VI) [12]. All individuals were of Indian ethnicity.

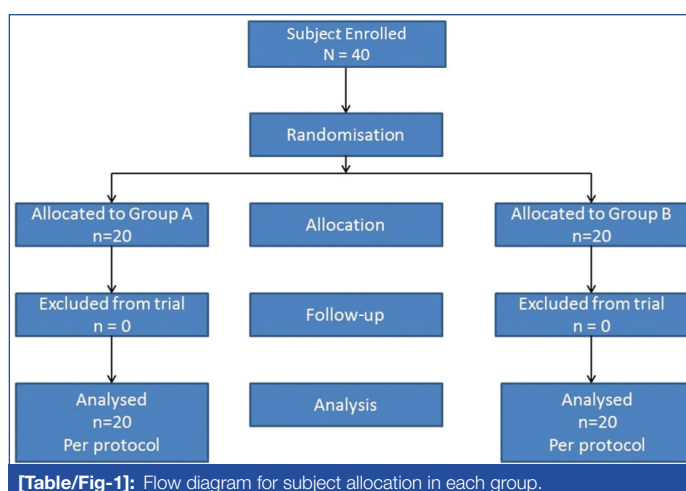
**Exclusion criteria:** History of surgical correction of scalp hair, topical minoxidil use in the past one year, use of medication with androgenic or antiandrogenic properties, use of finasteride, known systemic illnesses (such as endocrine imbalances, hepatic failure, renal failure, amyloidosis, sarcoidosis, hepatitis C, leukaemia, histiocytosis X, etc.), were excluded from the study.

A total of 40 individuals were enrolled in the present clinical trial. Sample size was calculated a priori with adequate power (0.80) to detect a defined difference in hair growth between the two treatment groups. The subjects were also advised to avoid hair dyes or change their hairstyle during the course of the present study. The study participants were selected and enrolled, as per a similar study by Dhurat R et al., [12].

The subjects were randomised into two equally distributed groups using "tossing a coin" method (heads=Group A, tails=Group B). The subjects' hair regrowth was evaluated qualitatively over a period of 12 months at intervals of 3, 6, 9 and 12 months calculated from the date of first PRP injection. Group A (n=20) consisted of subjects who received intradermal administration of autologous PRP every 15 days for three months along with oral biotin tablets (Tablet BTN Ultra, Zydus Liva, India; Manufactured by: Aurochem Pharmaceuticals, Palghar, India) once daily for three months, while those in group B (n=20) received oral biotin tablets (Tablet BTN Ultra, Zydus Liva, India; Manufactured by: Aurochem Pharmaceuticals, Palghar, India) once daily for three months. The flowchart of the study is depicted in [Table/Fig-1]. All study participants were informed about the process and its potential side-effects.

### Preparation of PRP

Platelet Rich Plasma (PRP) was prepared, as per the method described by Singhal P et al., [13]. Twenty mL of fresh blood was collected from the median cubital vein into sodium citrate vacutainers under sterile conditions. The tubes were rotated in a centrifuge machine at 1500 revolutions per minute (rpm) for six minutes. The first centrifugation referred to as "soft spin" separates the blood into three layers, lowermost Red Blood Cell (RBC) layer (55% of total volume), top most acellular plasma layer called Platelet



Poor Plasma (PPP, 40% of total volume), and an intermediate PRP layer (5% of total volume) called the "buffy coat." Buffy coat with PPP is collected with the help of a Finn pipette in another test tube. This tube is again centrifuged at 2500 rpm for 15 minutes called "hard spin." This allows the platelets (PRP) to settle at the bottom of the tube. The upper layer containing PPP is discarded and the lower layer of PRP is collected in another clean tube. The platelet concentrate is loaded in 1 mL insulin syringes, containing calcium chloride (nine parts of PRP and one part calcium chloride) as an activator and made ready for injections into the regions of interest.

### Administration of PRP

Areas where PRP was to be injected were cleaned with surgical spirit and povidone-iodine solution. PRP was injected by the same investigator. PRP was injected using insulin syringes in a linear fashion about 1 cm apart in an aseptic environment. PRP was injected in the frontal, temporal and parietal areas of the scalp. PRP was injected on selected areas of the scalp at the amount of 0.1 mL/cm<sup>2</sup>, as per a study by Cervelli V et al., [14]. About, 3-5 mL of PRP was injected. PRP was injected in a similar manner every 15 days for three months.

### Data Collection

Patients (N=40) were randomly assigned to the two treatment groups, group A and group B. Patients were asked to report to the department at 3, 6, 9 and 12 months (hair regrowth was assessed at three month intervals because the hair cycle takes about 90-100 days for new growth and shedding) for standardised photographs using a DSLR Camera of scalp hair for assessment of hair growth. This method was adapted from the investigation by Olsen EA et al., [15] and Canfield D [16]. The assessment of hair regrowth was done by the primary investigator at every time point by counting the hairs on the photographs. The assessment was qualitative in nature. Hair regrowth was assessed using a 7-point rating scale compared with baseline (-3 = greatly decreased, -2= moderately decreased, -1= slightly decreased, 0= no change, +1= slightly increased, +2= moderately increased, +3= greatly increased). With -3 being the lowest score accorded, while, +3 was the highest score possible. This scale was adopted, from previously published reports [12,17].

## STATISTICAL ANALYSIS

All statistical analyses were performed using Statistical Package for the Social Sciences for Windows (version 10.0; SPSS, Chicago, Illinois, USA). Comparisons between the groups (intergroup) were made using Chi-square test. In the present study, the level of significance was determined as  $p < 0.05$ .

## RESULTS

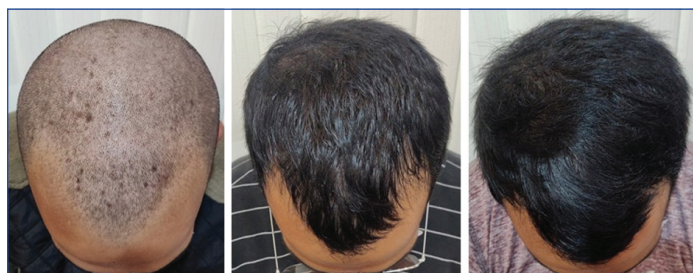Of the 40 patients enrolled in the study, all 40 patients reported for periodic visits, till the end of study period. No patients were lost to follow-up.

| Groups    | Baseline |          |          |          |         |         |         | Total N (%) | Chi-square value | p-value |
|-----------|----------|----------|----------|----------|---------|---------|---------|-------------|------------------|---------|
|           | -3 N (%) | -2 N (%) | -1 N (%) | 0 N (%)  | 1 N (%) | 2 N (%) | 3 N (%) |             |                  |         |
| Group A   | 0        | 0        | 0        | 20 (100) | 0       | 0       | 0       | 20 (100)    | -                | -       |
| Group B   | 0        | 0        | 0        | 20 (100) | 0       | 0       | 0       | 20 (100)    |                  |         |
| Total     | 0        | 0        | 0        | 40       | 0       | 0       | 0       | 40          |                  |         |
| 3 months  |          |          |          |          |         |         |         |             |                  |         |
| Groups    | -3 N (%) | -2 N (%) | -1 N (%) | 0 N (%)  | 1 N (%) | 2 N (%) | 3 N (%) | Total N (%) | 2.090            | 0.078   |
| Group A   | 0        | 0        | 0        | 11 (55)  | 9 (45)  | 0       | 0       | 20 (100)    |                  |         |
| Group B   | 0        | 0        | 3 (15)   | 13 (65)  | 4 (20)  | 0       | 0       | 20 (100)    |                  |         |
| Total     | 0        | 0        | 3        | 24       | 13      | 0       | 0       | 40          |                  |         |
| 6 months  |          |          |          |          |         |         |         |             |                  |         |
| Groups    | -3 N (%) | -2 N (%) | -1 N (%) | 0 N (%)  | 1 N (%) | 2 N (%) | 3 N (%) | Total N (%) | 7.621*           | 0.001   |
| Group A   | 0        | 0        | 0        | 3 (15)   | 8 (40)  | 9 (45)  | 0       | 20 (100)    |                  |         |
| Group B   | 0        | 0        | 5 (25)   | 11 (55)  | 4 (20)  | 0       | 0       | 20 (100)    |                  |         |
| Total     | 0        | 0        | 5        | 14       | 12      | 9       | 0       | 40          |                  |         |
| 9 months  |          |          |          |          |         |         |         |             |                  |         |
| Groups    | -3 N (%) | -2 N (%) | -1 N (%) | 0 N (%)  | 1 N (%) | 2 N (%) | 3 N (%) | Total N (%) | 21.397**         | 0.001   |
| Group A   | 0        | 0        | 0        | 1 (5)    | 4 (20)  | 15 (75) | 0       | 20 (100)    |                  |         |
| Group B   | 0        | 4 (20)   | 7 (35)   | 8 (40)   | 1 (5)   | 0       | 0       | 20 (100)    |                  |         |
| Total     | 0        | 4        | 7        | 9        | 5       | 15      | 0       | 40          |                  |         |
| 12 months |          |          |          |          |         |         |         |             |                  |         |
| Groups    | -3 N (%) | -2 N (%) | -1 N (%) | 0 N (%)  | 1 N (%) | 2 N (%) | 3 N (%) | Total N (%) | 23.025**         | 0.001   |
| Group A   | 0        | 0        | 0        | 0        | 3 (15)  | 5 (25)  | 12 (60) | 20 (100)    |                  |         |
| Group B   | 2 (10)   | 3 (15)   | 10 (50)  | 5 (25)   | 0       | 0       | 0       | 20 (100)    |                  |         |
| Total     | 2        | 3        | 10       | 5        | 3       | 5       | 12      | 40          |                  |         |

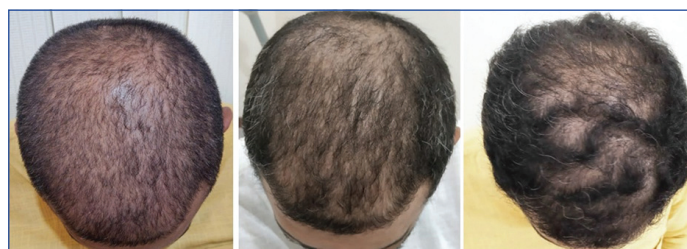[Table/Fig-2]: Intergroup analysis to assess hair regrowth.

Chi-square test; \*Significant difference ( $p < 0.05$ ); \*\*Highly significant difference ( $p < 0.001$ ) (fisher exact test was applied when more than 20% of cells had expected frequencies  $< 5$ )

The mean age of the population was  $31.2 \pm 5.39$  years of age. Group A had mean  $\pm$ SD of  $32.3 \pm 6.1$  years, group B had mean  $\pm$ SD of  $30.7 \pm 5.2$  years. Patients had hair loss for a mean average of 5.3 years (4-8 years). In the present study, it was observed that there was no statistically significant difference in hair regrowth at three months between groups A and B [Table/Fig-2]. However, at six months there was a statistically significant increase in hair growth ( $p < 0.05$ ) in individuals in group A [Table/Fig-2] as compared to group B; this change was progressive at both nine and 12 months. At both 9 and 12 months, there was a highly significant ( $p < 0.001$ ) difference between group A and group B [Table/Fig-2]. In the present study, it was observed that upon intradermal administration of PRP and oral supplementation with biotin (group A) there was statistically significant increase in hair regrowth as compared to hair growth after only oral biotin administration. The null hypothesis established at the beginning of the present study, was thus, rejected. Subjects of group A and B at different time intervals, can be seen in [Table/Fig-3,4].



[Table/Fig-3]: Standardised pictures of a subject in group A at different time intervals.



[Table/Fig-4]: Standardised pictures of a subject in group B at different time intervals.

factor has specific functions, which are as follows, regulation of cell proliferation, differentiation and survival by EGF; key regulator of cell metabolism and growth by IGF; PDGF promotes the synthesis of collagen and proteins and is a major mitogen for connective tissue cells, TGF regulates cell proliferation, differentiation, apoptosis, induction of intimal thickness, and, VEGF regulates angiogenesis [12]. These growth factors are vital for the growth and development of the hair follicle in all its stages, from anagen to catagen to telogen. The growth factors contained within the alpha granules of platelets act on stem cells in the bulge area of the hair follicles and stimulate the development of new follicles along with neovascularisation [18]. An understanding of the role of the aforementioned growth factors is critical to the successful management of AA. It is the miniaturisation of this hair follicle due to Dihydrotestosterone (DHT) [19], that results in AA.

Apart, from PRP administration and surgical procedures to address Androgenetic Alopecia (AGA), other therapeutic options, include topical minoxidil application and oral finasteride. However, potential side-effects have been documented with both [8,9]. Oral finasteride is not indicated for females.

## DISCUSSION

The PRP contains a variety of growth factors. These are, EGF, IGF, PDGF, Transforming Growth Factors ( $\alpha$  &  $\beta$ ) {TGF}, VEGF. Each



The therapeutic effects of PRP in the management of AA can be specifically attributed to the various PDGF aiding in significant improvement in the function of hair follicle and promotion of hair growth. Being autologous in nature, it is potentially free of any adverse effects and is inexpensive and easy to manufacture. In the present study, none of the patients reported with any adverse events, during the study period of 12 months. In the present study, hair regrowth was assessed at three month intervals because the hair cycle takes about 90-100 days for new growth and shedding [20]. This was in line with a similar methodology adopted by Schiavone G et al., [21].

Clinical study by Uebel CO et al., where they pretreated follicular units with platelet plasma growth factors before implantation in male patients, observed that there was significant improvement in hair density and hair growth [22]. Investigation by Schiavone G et al., demonstrated clinical improvement in males and females with AGA after administration of leucocyte PRP injected three months apart and evaluation was done over a period of 12 months [21]. Similar results were reported by Khatu SS et al., wherein they observed significant reduction in hair loss after injection of PRP at the end of an observation period of three months [23]. A meta-analysis published by Gupta AK and Carviel JL, showed that PRP injections have a promising role in the treatment of AA [24]. Gkini MA et al., evaluated the efficacy of PRP injections over a year and reported a significant reduction in hair loss after three months, and improved over a period of one year [25]. A study by Gentile P et al., suggested that PRP may lead to increase in keratinocyte proliferation and perifollicular angiogenesis [26]. However, a study by Ayatollahi A et al., using PRP in AGA patients did not find any difference in hair count or density [27].

It can be concluded from this study that PRP injection leads to a statistically progressive increase in hair regrowth. Future studies with greater number of participants and well-designed clinical trials could yield more evidence into application of intradermal PRP injections in the successful management of AA. Also, long-term studies on the survival rate of the hair regrowth obtained after PRP administration should be conducted to analyse the cost to benefit ratio of this modality. Clinically, the administration of PRP and oral biotin supplementation could be a viable treatment approach for males. Similar investigations can be planned for female population with alopecia, also.

### Limitation(s)

The small sample size was one of the limitation of the study. The study did not record survival rate of the hair regrowth after a period of 12 months. Also, the present study, was conducted on male population, and the findings cannot be extrapolated to females in a direct manner. PRP injection and oral biotin supplementation is an inexpensive and safe alternative, compared to other modalities of treatment for AGA.

### CONCLUSION(S)

The intradermal administration PRP with oral biotin supplementation yields statistically significant increase in hair regrowth compared to only oral biotin supplementation at 6, 9 and 12 months. This is a safe, non allergenic, relatively inexpensive and reliable treatment modality for individuals, who don't respond to other modes of treatment or are contraindicated for them.

### REFERENCES

- Rebora A. Pathogenesis of androgenetic alopecia. *J Am Acad Dermatol.* 2004;50(5):777-79.
- Sinclair R. Male pattern androgenetic alopecia. *Brit Med J.* 1998;317:865-69.
- Randall VA. Androgens and human hair growth. *Clin Endocrinol.* 1994;40:439-57.
- Cash TF. The psychological effects of androgenetic alopecia in men. *J Am Acad Dermatol.* 1992;26:926-31.
- Hamilton JB. Male hormone stimulation is a prerequisite and an incitant in common baldness. *Am J Anat.* 1942;71:451-80.
- Ellis JA, Sinclair R, Harrap S. Androgenetic alopecia: Pathogenesis and potential for therapy. *Expert Reviews Mol Med.* 2002;4:01-11
- Hamilton JB. Male pattern hair loss in man: Types and incidence. *Ann N Y Acad Sci.* 1951;53:708-28.
- Aktas H, Alan S, Torkoglu EB, Sevik O. Could topical minoxidil cause non-arteritic anterior ischemic optic neuropathy? *J Clin Diagn Res.* 2016;10(8):WD01-WD02.
- Mella JM, Perret MC, Manzotti M, Catalano HM, Guyatt G. Efficacy and safety of Finastiride therapy for androgenetic alopecia: a systematic review. *Arch Dermatol.* 2010;146:1141-50.
- Adelman M, Bedford L, Potss G. Clinical efficacy of popular oral hair growth supplement ingredients. *Int J Dermatol.* 2021;60(10):1199-10. Doi: 10.1111/ijd.15344. Epub 2020 Dec 9.
- Li ZJ, Choi HI, Choi DK, Sohn KC, Im M, Seo YJ, et al. Autologous platelet rich plasma: A potential therapeutic tool for promoting hair growth. *Dermatol Surg.* 2012;38:1040-46.
- Dhurat R, Sukesh MS, Avhad G, Dandale A, Pal A, Pund P, et al. A randomised evaluator blinded study of effect of microneedling in androgenetic alopecia: A pilot study. *Int J Trichol.* 2013;5:06-11.
- Singhal P, Agarwal S, Dhot PS, Sayal SK. Efficacy of platelet-rich plasma in treatment of androgenic alopecia. *Asian J Transfus Sci.* 2015;9(2):159-62.
- Cervelli V, Garcovich S, Bielli A, Cervelli G, Curcio BC, Scioli MG, et al. The effect of Autologous Activated Platelet Rich Plasma (AA-PRP) injection on pattern hair loss: Clinical and histomorphometric evaluation. *Bio Med Research International.* 2014;9:1-9.
- Olsen EA, Whiting DA, Savin R, Rodgers A, Johnson-Levonos A, Round E. Global photographic assessment of men aged 18 to 60 years with male pattern hair loss receiving finasteride 1mg or placebo. *J Am Acad Dermatol.* 2012;67(3):379-86.
- Canfield D. Photographic documentation of hair growth in androgenetic alopecia. *Clin Dermatol.* 1996;14:713-21.
- Kauffman KD, Olsen EA, Whiting D, Savin R, DeVillez R, Bergfeld W, et al. Finastiride in the treatment of men with androgenetic alopecia. *J Am Acad Dermatol.* 1998;39:578-89.
- Leo MS, Kumar AS, Kirit R, Konathan R, Sivamani RK. Systematic review of the use of platelet-rich plasma in aesthetic dermatology. *J Cosmetic Dermatol.* 2015;14(4):315-23.
- Crabtree JS, Kilbourne EJ, Peano BJ, Chippari S, Kenney T, McNally C, et al. A mouse model of androgenetic alopecia. *Endocrinology.* 2010;151:2373-80.
- Hoover E, Alhaji M, Flores JL. Physiology, Hair. [Updated 2021 Jul 26]. In: StatPearls. Treasure Island (FL): StatPearls Publishing; 2022.2022.
- Schiavone G, Raskovic D, Greco J, Abeni D. Platelet-rich plasma for androgenetic alopecia: A pilot study. *Dermatol Surg.* 2014;40:1010-19.
- Uebel CO, da Silva JB, Cantarelli D, Martins P. The role of platelet plasma growth factors in male pattern baldness surgery. *Plast Reconstr Surg.* 2006;118:1458-66.
- Khatu SS, More YE, Gokhale NR, Chavhan DC, Bendsure N. Platelet rich plasma in androgenic alopecia: Myth or an effective tool. *J Cutan Aesthet Surg.* 2014;7(2):107-10.
- Gupta AK, Carviel JL. Meta-analysis of efficacy of platelet-rich plasma therapy for androgenetic alopecia. *J Dermatol Treatment.* 2017;28(1):55-58.
- Gkini MA, Kouskoukis AE, Tripsianis G, Rigopoulos G, Kouskoukis K. Study of platelet-rich plasma injections in the treatment of androgenetic alopecia through an one-year period. *J Cutan Aesthet Surg.* 2014;7(4):213-19.
- Gentile P, Garcovich S, Bielli A, Scioli MG, Orlandi A, Cervelli V, et al. The effect of platelet-rich plasma in hair regrowth: A randomised placebo-controlled trial. *Stem Cell Translational Med.* 2015;4:1317-23.
- Ayatollahi A, Hosseini H, Shahdi M, AhmadNasrollahi S, NassiriKashani M, Yadangi S, et al. Platelet-rich plasma by single spin process in male pattern androgenetic alopecia: Is it an effective treatment? *Indian Dermatol Online J.* 2017;8:460-64.

#### PARTICULARS OF CONTRIBUTORS:

- Associate Professor, Department of Dermatology, Venereology and Leprology, NSCB Government Medical College, Jabalpur, Madhya Pradesh, India.

#### NAME, ADDRESS, E-MAIL ID OF THE CORRESPONDING AUTHOR:

Dr. Neha Gupta,  
HIG 13, JDA Colony, Katanga, Jabalpur-482001, Madhya Pradesh, India.  
E-mail: dr.neha33@gmail.com

#### AUTHOR DECLARATION:

- Financial or Other Competing Interests: None
- Was Ethics Committee Approval obtained for this study? Yes
- Was informed consent obtained from the subjects involved in the study? Yes
- For any images presented appropriate consent has been obtained from the subjects. Yes

#### PLAGIARISM CHECKING METHODS: [Jan H et al.]

- Plagiarism X-checker: Jun 16, 2022
- Manual Googling: Sep 24, 2022
- iThenticate Software: Oct 01, 2022 (23%)

#### ETYMOLOGY: Author Origin

Date of Submission: **May 24, 2022**

Date of Peer Review: **Jul 09, 2022**

Date of Acceptance: **Oct 05, 2022**

Date of Publishing: **Nov 01, 2022**