

Measurement of Filum Terminale in the Foetuses of Third Trimester Gestational Age: An Observational Study

NAND KISHOR GUPTA¹, HETAL VAISHNANI², PREETI GUPTA³, ACHLESWAR GANDOTRA⁴



ABSTRACT

Introduction: The covering of spinal cord is same as that of brain. The pia mater, arachnoid and dura mater covers the spinal cord from inside out. The pia mater extends from cephalic end of spinal cord upto terminal portion i.e., conus medullaris. Beyond the conus, the pia mater extends in the form of filum terminale. The filum terminale extends beyond the conus medullaris and attaches upto dorsal aspects of coccyx to stabilise the spinal cord in its position.

Aim: To study the length of filum terminale in the foetuses of third trimester gestational age.

Materials and Methods: The present cross-sectional observational study was carried out in 30 foetuses collected from museum of Department of Anatomy and Department of Obstetrics and Gynaecology. The permission and approval from University Ethical Committee was taken before starting the study. The foetuses were divided into three groups taking into consideration their gestational age (four foetuses in 1st group 28-31 weeks, 12 foetuses in 2nd group 32-35 weeks and 14 foetuses were in 3rd group

36-40 weeks gestational age). Also, the gender-wise variation (11 male and 19 female foetuses) was taken into account. All the data were recorded in Microsoft excel sheet and Statistical Package for the Social Sciences (SPSS) 23.0 software was used for statistical analysis. Numerical values were reported as the mean±standard deviation.

Results: In this study, the mean length of filum terminale was 4.35±1.04 cm with range minimum 2.31 cm to maximum 5.90 cm. The length of spinal cord and length of filum terminale measurements significantly increased with increasing gestational age ($p < 0.001$). The length of spinal cord, length of filum terminale measurement and ratio of length of filum terminale to length of spinal cord (FT/SC) were significantly higher in male foetuses ($p < 0.05$).

Conclusion: The association between gestational age (weeks), length of filum terminale, and length of spinal cord among all foetuses, and male and female separately were statistically significant.

Keywords: Conus medullaris, Pia mater, Spinal cord

INTRODUCTION

The covering of spinal cord is same as that of brain i.e. from inside out it is pia mater, arachnoid and dura mater. Initially the development of length of vertebral column and spinal cord are same which later on undergoes alterations. The growth of vertebral column is faster than that of spinal cord due to which the spinal cord terminates early within the vertebral canal. The pia mater, after covering the lowermost level of spinal cord i.e. conus medullaris, extend beyond the spinal cord and get adhere to the dorsal aspects of coccyx. That is called the filum terminale. The primary function of filum terminale is to fix the spinal cord into the vertebral canal during various movements of individual. The proximal part of filum terminale is covered by dura mater externally and called as filum terminale interna and remaining distal portion uncovered by dura is called filum terminale externa. The filum terminale interna is 15 cm long and externa is 5 cm long in adult [1]. Initially during the development of foetus, the length of spinal cord and vertebral canal is corresponding and filum terminale is very little or minimal in length. As the growth advances, the length of vertebral canal overtakes the length of spinal cord and hence the length of filum terminale increases to keep the terminal portion of spinal cord in its position [2]. The functions of filum terminale is to fix, stabilise, and buffer the distal spinal cord from normal and abnormal cephalic and caudal traction. The filum terminale is composed largely of loose collagen fibres, small blood vessels, and occasional small nerve fascicles, and contains an extension of the central canal that is lined with ciliated ependymal cells [3].

The parameters of filum terminale are important to neurosurgeons. Moreover, the variations in termination of conus and dural sac termination are of a particular importance to anaesthetists during spinal and sacral anaesthesia [4]. Anatomical studies of the filum terminale are rare. Yandt KD et al., used surgical images of the filum

terminale of children under dorsal rhizotomy to evaluate the thickness of filum terminale [5]. Hansasuta A et al., evaluated the vertebral levels of the fusion of the intradural portion of the filum terminale in 27 cadavers [6]. Some of these studies are based on data obtained by using radiological methods such as Ultrasonography (USG), Computed Tomography (CT) and Magnetic Resonance Imaging (MRI) [4]. So this study aims to measure the length of filum terminale and its adherens to the dorsal aspects of either sacrum or coccyx.

MATERIALS AND METHODS

The present cross-sectional observational study was carried out in 30 foetuses during January 2020 upto July 2022. The foetuses were collected from Department of Obstetrics and Gynaecology (IUD-Intrauterine Death Foetuses) and foetuses kept in Department of Anatomy, Uttar Pradesh University of Medical Science, Saifai, Etawah, Uttar Pradesh, India. The ethical clearance was taken from University Ethical Committee (Ref no 665/UPUMS/DEAN/2019-20/E.C.NO.2019/20 Date 08.07.2019). The parents consent was also taken before collecting IUD foetuses.

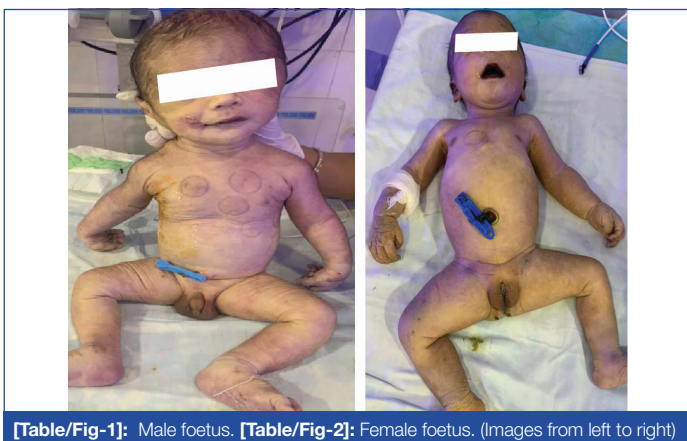Inclusion criteria: Gestation week from 28 weeks onwards upto 40-week foetuses were included in this study.

Exclusion criteria: Foetuses have any abnormal development of nervous system and spinal cord was excluded from the study.

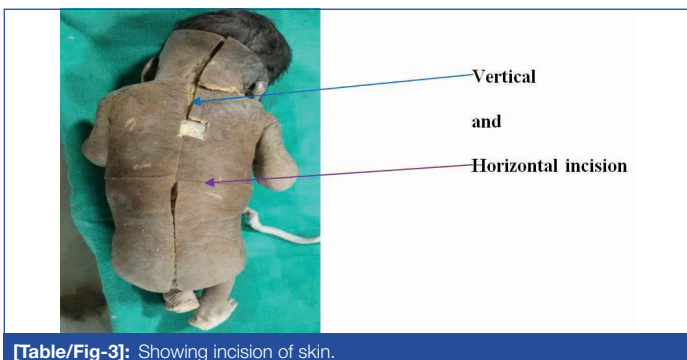
Study Procedure

The foetuses were kept in 10% formalin solution as soon as collected from labour room, Department of Obstetrics and Gynaecology, Uttar Pradesh University of Medical Science, Saifai, Uttar Pradesh, India. The measurement taken initially were cranio-Rump (CR) Length, Biparietal diameter (BPD), APD (Antero-posterior diameter), Abdominal Circumference (AC), Femur length and Foot length to estimate the

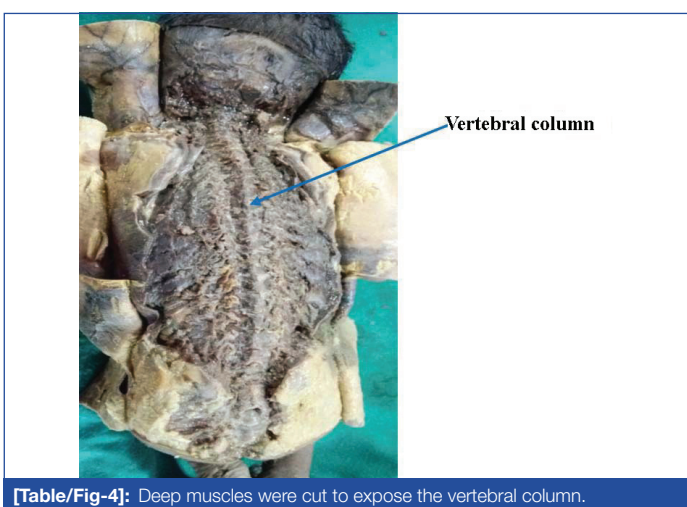
gestational age of foetuses kept in the anatomy department. The early dissection included incision of skin from external occipital protuberance upto lower limit of coccyx. The skin was cut and reflected laterally. The superficial fascia, superficial muscles and deep muscles of back from external occipital protuberance upto lowermost point of sacrum and coccyx was cut and removed to visualise the vertebral column. The spines and laminae of vertebra were cut with the help of scissor and scalpel in midline. The surface of the spinal cord i.e. the dura and arachnoid mater was clean and cut from top to bottom. All the spinal nerves coming out from the spinal cord laterally were cleaned. Moving downward, all the nerves of cauda equina were separated and spread out to visualise the filum terminale. The length of filum terminale from lowermost point of conus medullaris upto terminal attach point was measured with the help of measuring scale [Table/Fig-1-11]. For descriptive purpose, the foetuses were divided into three groups according to their gestational age (four foetuses in 1st group 28-31 weeks, 12 foetuses in 2nd group 32-35 weeks and rest 14 foetuses were in 3rd group 36-40 weeks gestational age).



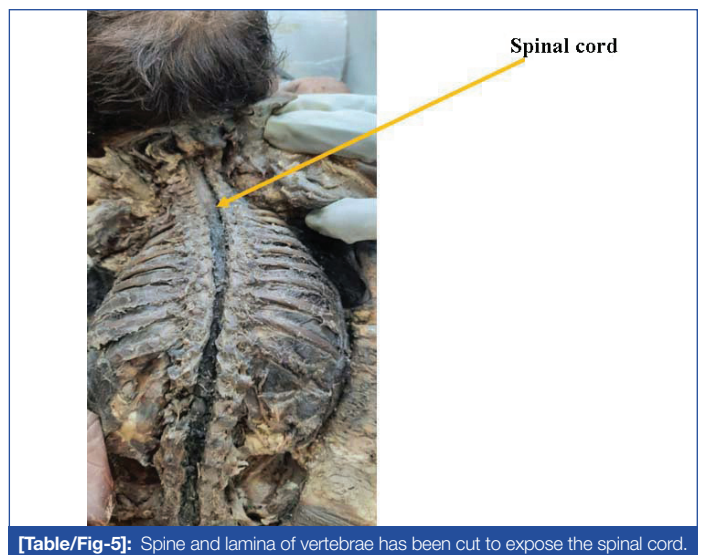
[Table/Fig-1]: Male foetus. [Table/Fig-2]: Female foetus. (Images from left to right)



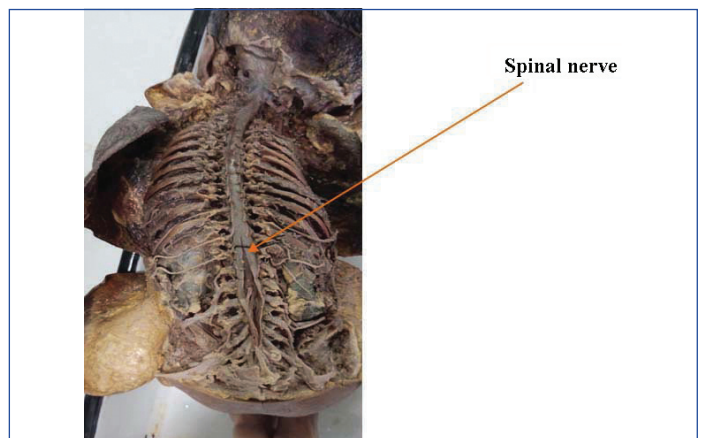
[Table/Fig-3]: Showing incision of skin.



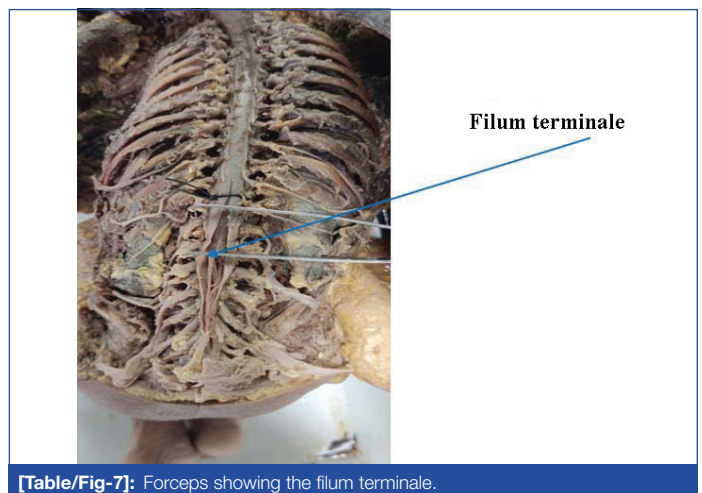
[Table/Fig-4]: Deep muscles were cut to expose the vertebral column.



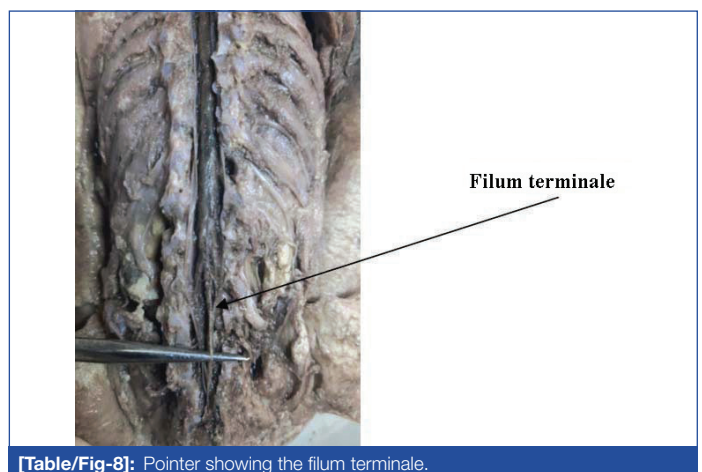
[Table/Fig-5]: Spine and lamina of vertebrae has been cut to expose the spinal cord.



[Table/Fig-6]: Dura mater was cut to expose the spinal nerve.



[Table/Fig-7]: Forceps showing the filum terminale.



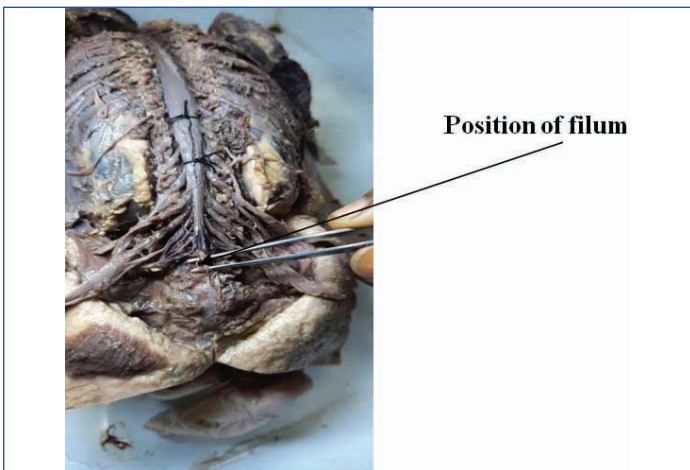
[Table/Fig-8]: Pointer showing the filum terminale.

STATISTICAL ANALYSIS

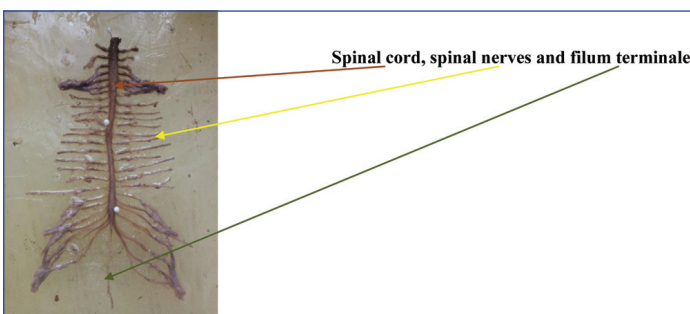
All the data were recorded in Microsoft excel sheet and Statistical Package for the Social Sciences (SPSS) 23.0 software was used for statistical analysis. Numerical values were reported as the



[Table/Fig-9]: Showing the measurement of filum terminale.



[Table/Fig-10]: Showing the position of filum.



[Table/Fig-11]: Showing the spinal cord, spinal nerves and filum terminale.

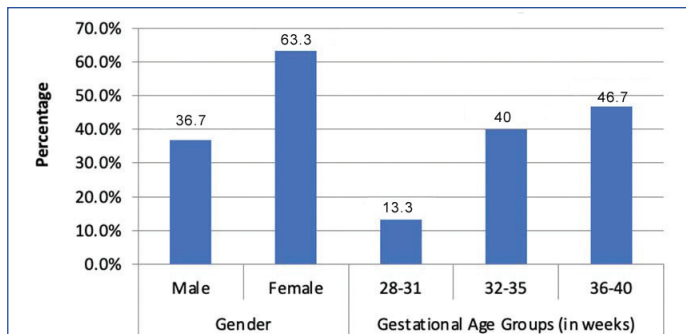
mean±standard deviation. Student's t-test or one way ANOVA was used to analyse quantitative variables. Two tailed p-values were considered significant (p<0.05).

RESULTS

The majority 14 (46.7%) of the foetuses belonged to 36-40 weeks gestational age group followed by 12 (40.0%) foetuses in 32-35 weeks gestational age group and rest 4 (13.3%) foetuses were 28-31 weeks gestational age group. In present study, 19 (63.3%) foetuses were female and rest 11 (36.7%) were male. Nine (81.8%) male foetuses were between 36-40 weeks and two (18.2%) were in 32-35 weeks gestational age group; while 10 (52.6%) female foetuses were in gestational age 32-35 weeks followed by five (26.3%) in 36-40 week and 4 (21.1%) in gestational age 28-31 weeks gestational age group. No male foetus was included in gestational age 28-31 weeks gestational age group [Table/Fig-12].

Present study noted that the mean length of filum terminale was 4.35±1.04 cm with range minimum 2.31cm to maximum 5.90 cm. The length of filum terminale increased with respect to increasing gestational age [Table/Fig-13]. The gender-wise difference in the length of filum terminale was noted and it was found that male foetuses had greater measurements of length of filum terminale than the female [Table/Fig-14].

This study noted that the length of spinal cord and length of filum terminale measurement significantly increased with increasing gestational age (p-value <0.001) but ratio of length of filum terminale to total length of spinal cord (FT/SC) were insignificantly higher with increasing gestational age (p-value >0.05) [Table/Fig-15]. Present



[Table/Fig-12]: Gender and gestational age group-wise distributions of studied foetuses.

S. No.	Gestational age groups (in weeks)	Length of filum terminale (in cm)		
		Average	Minimum	Maximum
1	28-31	3.08±0.71	2.31	4.00
2	32-35	4.09±0.70	3.20	5.60
3	36-40	4.94±0.97	2.60	5.90
Total		4.35±1.04	2.31	5.90

[Table/Fig-13]: Length of filum terminale distributions in various gestational age groups.

S. No.	Gestational age groups (in weeks)	Length of filum terminale (Male) (in cm)	Length of filum terminale (Female) (in cm)
1	28-31	-	3.08±0.71
2	32-35	4.32±1.10	4.04±0.67
3	36-40	5.12±1.03	4.60±0.87
Total		4.98±1.03	3.99±0.87

[Table/Fig-14]: Length of filum terminale in male and female distributions in various gestational age groups.

study also noted that the length of spinal cord, length of filum terminale measurement and ratio of length of filum terminale to total length of spinal cord (FT/SC) were significantly higher in male foetuses (p-value <0.05) [Table/Fig-16].

In this study, it was noted that in all the foetuses, the filum terminale was attached to the dorsal aspect of lower level of sacrum. In none of the foetus the filum terminale was attached to coccyx.

S. No.	Gestational age groups (in weeks)	Length of spinal cord (in cm)	Length of filum terminale (in cm)	Ratio of length of filum terminale to total length of spinal cord (FT/SC)
1	28-31	12.16±1.24	3.08±0.71	0.26±0.07
2	32-35	14.45±0.75	4.09±0.70	0.28±0.04
3	36-40	15.71±0.84	4.94±0.97	0.31±0.05
F value		27.458	8.469	2.531
p-value*		<0.001	<0.001	0.098

[Table/Fig-15]: Length of spinal cord and filum terminale distributions in various gestational age groups.

*One Way ANOVA

S. No.	Gender	Length of spinal cord (in cm)	Length of filum terminale (in cm)	Ratio of length of filum terminale to total length of spinal cord (FT/SC)
1	Male	15.59±1.17	4.98±1.03	0.32±0.05
2	Female	14.24±1.39	3.99±0.87	0.28±0.05
t value		2.694	2.801	2.092
p-value*		0.012	0.009	0.046

[Table/Fig-16]: Length of spinal cord and filum terminale in male and female distributions in various gestational age groups.

*Independent Sample t test

DISCUSSION

In this study, majority 46.7% foetuses belonged to 36-40 weeks gestational age group followed by 40.0% foetuses in 32-35 weeks gestational age group and rest 13.3% foetuses in 28-31 weeks gestational age groups.

The human embryo of 7-5 mm cranio-rump length possesses a tail. This is reduced to a tail bud in 25-27 mm embryos and has disappeared in 30-35 mm fetuses [7]. Absorption of the tail is completed by 30 mm cranio-rump length [8]. In the very youngest embryos, the spinal cord extends to the tip of the tail and, with the reduction of the tail, the spinal cord ends at the remnant of the tail bud [8]. Dedifferentiation of the spinal cord is well demonstrated in the 11-30 mm cranio-rump length embryonic stages.

The mean length of filum terminale of the studied fetuses was 4.35 ± 1.04 cm with range minimum 2.31 cm to maximum 5.90 cm in present study. The gender-wise difference in the length of filum terminale was more in male fetuses than the female fetuses in present study. Nasr MAY et al., found that the length of filum terminale was 164.2 ± 11.6 mm in male, 159.2 ± 10.1 mm in female and 162.3 ± 12.8 mm in all cadavers ($p > 0.05$) [4]. The results of present research were in line with those of Gomes Pinto FC et al., [9] and De Vloot P et al., [10] who found no significant correlation between the body length and filum terminale length. Minimal variations and minor differences were found in the morphometric parameters of filum terminale in the previous cadaveric studies, where the mean length of filum terminale varied from 155.4-158.8 mm [3,9,10].

In the smallest embryos of 11-15 mm cranio-rump length, the spinal cord is divisible at the level of the 32nd (Co 3) vertebra into a cranial part with a wide central canal and an atrophic caudal part with a narrow central canal. Later the caudal end of the cranial part develops into the conus medullaris and its lumen forms the terminal ventricle. The caudal atrophic part undergoes regressive changes, becomes slender and eventually forms the filum terminale [7].

Present study noted that the length of spinal cord and length of filum terminale measurement significantly increased with increasing gestational age (p -value < 0.001) but ratio of length of filum terminale to total length of spinal cord (FT/SC) were insignificantly higher with increasing gestational age (p -value > 0.05). Anatomic studies of the filum terminale are rare, and some of those studies are based on data obtained by using radiological methods such as myelography, CT, MRI [11, 12]. Tarlov IM [13] found that the length of the extradural component of the filum terminale is approximately 2.2 cm in the newborn infant. In adults, they found that the mean length of the filum terminale externa was 7.5 cm. Another investigator found that the mean length of the filum terminale externa was approximately 8 cm [14]. In all 15 of specimens, Shane Tubbs R et al., found that this structure ranged in length from 7-10.5 cm (mean 8 cm) [15]. The aforementioned findings contradict comments made by Bale PM that after birth the filum terminale externa is difficult to find [16].

In the 30 mm cranio-rump length embryo, the wall of the coccygeal spinal cord thins out opposite and just caudal to the 1st coccygeal nerve to form the conus medullaris with a corresponding enlargement of the central canal opposite the 2nd and 3rd coccygeal vertebrae forming the terminal ventricle. Caudal to it, the central canal becomes obliterated and the cord is replaced by a fibrous strand, the filum terminale. The coccygeal spinal cord therefore undergoes dedifferentiation. There is no further dedifferentiation of the sacral region of the spinal cord after the 30 mm stage [8].

The formation of the filum terminale involves (1) dedifferentiation and redifferentiation of the caudal (coccygeal) part of the spinal cord caudal to 30th segment and (2) relative shortening of the spinal cord and ascent of the conus medullaris due to mechanical disproportion between growth in length of the spinal cord and the vertebral column [7]. The filum terminale thus represents the region of the spinal cord between its tip and the conus medullaris (terminal ventricle), caudal to the 1st coccygeal (30th) segment, which has dedifferentiated and redifferentiated into a slender fibrous strand [8].

Limitation(s)

In the present study, the sample size was limited. Future study could be conducted with a larger sample size. This study was a single centred study within limited geographical area so it was not representative of entire India and so further multicentre studies are recommended.

CONCLUSION(S)

The length of filum terminale and length of spinal cord were significantly higher in 36-40 weeks gestational age group than the 28-35 weeks gestational age group. The length of filum terminale and length of spinal cord was also significantly higher male. The importance of this study is mainly for surgeons and anaesthetists for the proper position of spinal cord in foetus so that during surgery, the conus medullaris, cauda equina must not get harmed.

REFERENCES

- [1] Dutta AK. Essentials of Neuro-Anatomy, 2nd edition, Current Books International. 2004.
- [2] Arthurs OJ, Thayil S, Wade A, Chong WK, Sebire NJ, Taylor AM. Normal ascent of the conus medullaris: A postmortem foetal MRI study. *J Matern Fetal Neonatal Med.* 2012;26(7):697-02.
- [3] Fontes RB, Saad F, Soares MS, de Oliveira F, Pinto FC, Liberti EA, et al. Ultrastructural study of the filum terminale and its elastic fibers. *Neurosurg.* 2006;58:978-84.
- [4] Nasr AY, Hussein AM, Zaghloul SA. Morphometric parameters and histological study of the filum terminale of adult human cadavers and magnetic resonance images. *Folia Morphol (Warsz).* 2018;77(4):609-19.
- [5] Yandt KD, Park TS, Kaukman BA. Normal diameter of filum terminale in children: In-vivo measurement. *Pediatr Neurosurg.* 1997;27:257-59.
- [6] Hansasuta A, Tubbs RS, Oakes WJ. Filum terminale and dural sac termination: Study in 27 cadavers. *Pediatr Neurosurg.* 1999;30:176-79.
- [7] Kunitomo K. The development and reduction of the tail and of the caudal end of the spinal cord. *Contributions to Embryology.* 1918;26:161-98.
- [8] Streeter GL. Factors involved in the formation of the filum terminale. *Am J Anat.* 1919;25:01-11.
- [9] Gomes Pinto FC, de Vasconcellos Fontes RB, Leonhardt Mde C, Amodio DT, Porro FF, Machado J, et al. Anatomic study of the filum terminale and its correlations with the tethered cord syndrome. *Neurosurg.* 2002;51(3):725-29; discussion 729.
- [10] De Vloot P, Monea AG, Sciort R, van Loon J, Van Calenbergh F. The filum terminale: A cadaver study of anatomy, histology, and elastic properties. *World Neurosurg.* 2016;90: 565-73.
- [11] Gryspeerdt GL. Mylographic assessment of occult forms of spinal dysraphism. *Acta Radiol.* 1963;1:702-17.
- [12] McLendon RE, Oakes WJ, Heinz ER, Yeates AE, Gurger PC. Adipose tissue in filum terminale: A computed topographic finding that indicates tethering of the spinal cord. *Neurosurg.* 1988;22:873-76.
- [13] Tarlov IM. Structure of filum terminale. *Arch Neurol Psychiatry.* 1938;40:01-17.
- [14] Harmeier JW. The normal histology of the intradural filum terminale. *Arch Neurol Psychiatry.* 1933;29:308.
- [15] Tubbs RS, Murphy RL, Kelly DR, Lott R, Salter EG, Oakes WJ. The filum terminale externum. *J Neurosurg: Spine.* 2005;3(2):149-52.
- [16] Bale PM. Sacrococcygeal developmental abnormalities and tumors in children. *Perspect Pediatr Pathol.* 1984;3:09-56.

PARTICULARS OF CONTRIBUTORS:

1. PhD Scholar, Department of Anatomy, Smt. B. K. Shah Medical Institute and Research Centre, Vadodara, Gujarat, India.
2. Professor and Head, Department of Anatomy, Smt. B. K. Shah Medical Institute and Research Centre, Vadodara, Gujarat, India.
3. Assistant Professor, Department of Physiology, Naraina Medical College and Research Centre, Kanpur, Uttar Pradesh, India.
4. Professor, Department of Anatomy, Smt. B. K. Shah Medical Institute and Research Centre, Vadodara, Gujarat, India.

NAME, ADDRESS, E-MAIL ID OF THE CORRESPONDING AUTHOR:

Dr. Preeti Gupta,
C304, Type 4, New Campus, UPUMS, Saifai, Etawah, Uttar Pradesh, India.
E-mail: physiologypreeti@gmail.com

AUTHOR DECLARATION:

- Financial or Other Competing Interests: None
- Was Ethics Committee Approval obtained for this study? Yes
- Was informed consent obtained from the subjects involved in the study? Yes
- For any images presented appropriate consent has been obtained from the subjects. No

PLAGIARISM CHECKING METHODS: [Jain H et al.]

- Plagiarism X-checker: Jul 29, 2022
- Manual Googling: Oct 11, 2022
- iThenticate Software: Oct 13, 2022 (24%)

ETYMOLOGY: Author Origin

Date of Submission: Jul 27, 2022
Date of Peer Review: Sep 03, 2022
Date of Acceptance: Oct 14, 2022
Date of Publishing: Nov 01, 2022