

# Early Onset Sarcoidosis/Blau Syndrome: Disguising as Juvenile Idiopathic Arthritis

BHARAT KUMAR SINGH<sup>1</sup>, SEEMA SINGH<sup>2</sup>, SAVITA SINGH<sup>3</sup>

## ABSTRACT

Blau Syndrome (BS) is a rare autoinflammatory granulomatous disorder which mostly develops at an early age (less than four years) and is described by granulomatous dermatitis, symmetric arthritis and recurrent uveitis. Hereby, the authors present a case of a 5-year-old female child with joint pain and swelling since four years. Initially, her diagnosis was made as juvenile idiopathic arthritis-polyarticular Rheumatoid Factor (RF) negative and was initiated on methotrexate along with bridge steroids (prednisolone). When she presented to the hospital, she had skin coloured micropapular rashes, mostly non follicular over body, from last nine months and after skin and synovial biopsy, the diagnosis was reviewed as early onset sarcoidosis/BS-sporadic type. The present rare report highlights that, BS is an under-recognised and reported childhood arthritis which may have multisystem involvement. The onset of arthritis without ocular or skin manifestations may be mistaken as juvenile idiopathic arthritis.

**Keywords:** Early rheumatoid arthritis, Granulomatous dermatitis, Inflammation, Polyarticular rheumatoid factor, Uveitis

## CASE REPORT

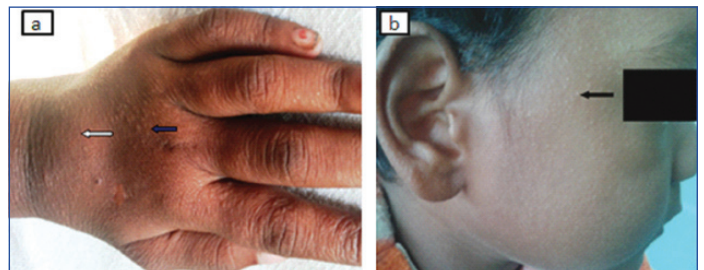
A 5-year-old female child presented to the Department of Rheumatology with joint pain and swelling since four years, for which naproxen was prescribed by her family physician. She was taking Non Steroidal Anti-inflammatory Drug Naprosyn (NSAIDs) as and when needed. She had been well till one year of age then her mother noticed swelling and pain over both the knees, ankles, wrists, small joints of hands. Patient had a history of difficulty in walking, playing and early morning stiffness for around 30 minutes for four weeks. It was insidious in onset and gradually progressing. She was the younger of two siblings and was born out of non consanguineous marriage. There was no family history of any autoimmune disease.

On examination, child appeared unwell with moderate fever, pale with no organomegaly or lymphadenopathy. Wrist, small joints of hands, knee and ankle joints were swollen with no tenderness, redness or warmth. Swelling was disproportionately more than pain; however, no deformities were noted. Erythrocyte Sedimentation Rate (ESR) (45 mm/hr) and high-sensitivity C-Reactive Protein (CRP) (29.4 mg/L) were raised however, haemoglobin was 9.2 g/dL, platelets were 2.5 lacs/mm<sup>3</sup> with normal total and differential counts. X-rays showed soft tissue swelling with no juxta articular osteopenia or joint space narrowing. Auto-antibody profile RF, Anti-Cyclic Citrullinated Peptide (anti-CCP) antibody, Antinuclear Antibodies (ANA), Human Leukocyte Antigen B27 (HLA-B27) was negative.

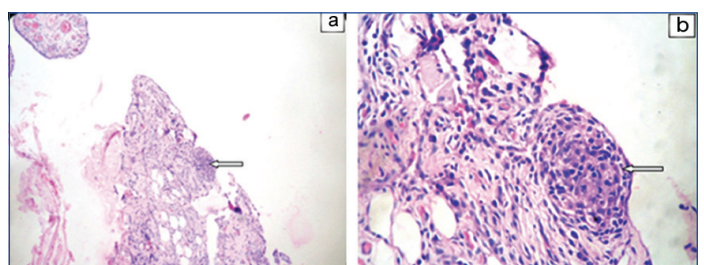
The diagnosis was made as juvenile idiopathic arthritis-polyarticular RF negative based on the International League of Associations for Rheumatology's (ILAR) criteria [1], and was initiated on methotrexate 10 mg/m<sup>2</sup> and increased to 15 mg/m<sup>2</sup> (duration three months) along with bridge steroids (prednisolone 0.5 mg/kg/day). She responded well to the treatment with improvement in joint pain, swelling, and fever. Steroids were tapered-off over three months and maintained on methotrexate.

After 18 months she had two episodes of bilateral anterior uveitis due to poor compliance, which was managed with topical steroids and mydriatics. Now, she had developed skin coloured micropapular rashes mostly non follicular over body, from last nine months [Table/Fig-1]. These rashes were non tender, non itchy and joint swellings appeared again. Her skin and synovial biopsies [Table/Fig-2] revealed non caseating epithelioid granulomas and Ziehl-Neelsen (ZN) stain was negative. Mantoux test, interferon-gamma release

assays were negative. Serum Angiotensin-Converting Enzyme (ACE) level was 97 U/L and serum calcium was 10.1 mg/dL. Her diagnosis was reviewed as early onset sarcoidosis/Blau syndrome-sporadic type based on clinical history and histopathology findings. ANA and HLA-B27 were also negative. Her parents chose not to go for genetic analysis due to financial limitations. She was initiated again on methotrexate (10 mg/m<sup>2</sup>) and low dose prednisolone (7.5 mg) and she is doing well, till the latest follow-up from the last nine months. Methotrexate was continued and prednisolone was tapered-off in three months.



**[Table/Fig-1]:** Micropapular rashes (a) white arrow showing swelling of metacarpal joints and blue arrow indicating the micropapular rashes (b) black arrow showing micropapular rashes.



**[Table/Fig-2]:** Synovial biopsy. a: Showing granulomatous inflammation synovial biopsy. b: Showing multinucleated giant cells (H&E stain 10X).

## DISCUSSION

Blau syndrome is primarily an inherited and chronic inflammatory syndrome which is described by granulomatous dermatitis, symmetric arthritis and recurrent uveitis which mostly develops at an early age (<4 years) [2]. It has been reported that patients with Early Onset Sarcoidosis (EOS) may also have mutations in CARD15/NOD2 as BS; hence, BS and EOS are considered as familial and sporadic forms of same disease, respectively. To the best of our

Author	Place	Year of publication	Age (years)/ Sex	Systemic involvement	Treatment received	Outcome
Present study	Jaipur, Rajasthan	2022	5/Female	Joint pain, swelling, pain over knees, ankles, wrists, small joints of hands. History of difficulty in walking and playing and early morning stiffness	Methotrexate 10 mg/m <sup>2</sup> increased to 15 mg/m <sup>2</sup> along with prednisolone 0.5 mg/kg/day	Responded well and joint pain, swelling and fever were subsided.
Jindal AK et al., [8]	Chandigarh	2021	3/Female	History of fever and symmetric polyarthritis of large and small joints involving both upper and lower limbs boggy swellings, tenderness, and restriction of movements in the joints.	Mycophenolate mofetil (1.5 gm daily) along with oral prednisolone (1 mg/kg/day followed by gradual tapering) Administration of adalimumab (40 mg every two weeks).	Showed good response to this treatment. Proteinuria has resolved and liver functions have normalised.
Naik AU et al., [9]	Porur, Tamil Nadu	2018	5/Male	Sudden onset of pain, redness, and diminution of vision in both eyes for one week	Adalimumab monotherapy (20 mg subcutaneous injections every two weekly)	Uveitis, cystoid macular oedema and arthritis resolved completely.
Jain L et al., [10]	Bhubaneswar	2018	12/Female	Bilateral granulomatous anterior uveitis accompanied by boggy arthritis of knee and ankle joints, intermittent fever, and nodular skin rash	Oral methotrexate and corticosteroids	Ocular inflammation resolved completely following therapeutic vitrectomy in both eyes Systemic symptoms of fever and arthritis continued to wax.
Agarwal K et al., [24]	Dibrugarh, Assam	2016	7/Female	History of redness and scaling all over the body for 10 months, Boggy swelling of the elbow, wrist, ankle and knee joints for the last six months	Systemic corticosteroids at a dose of 1 mg/kg body weight, tapered to 0.5 mg/kg after four weeks and gradually tapered-off thereafter. Methotrexate at a dose of 0.5 mg/kg body weight	The skin lesions responded well, with a decrease in the size and number and the joint swelling improved considerably but there was no change in the ocular symptoms.
Sinha P et al., [25]	Pune, Maharashtra	2020	14/Female	History of multiple exacerbations and remissions and history of multiple skin-coloured, non itchy, pinhead-sized eruptions over the body for the past 10 years	Oral methotrexate	Responded well with the reduction in arthritis as well as the resolution of skin lesions.

**[Table/Fig-3]:** Important findings from present study and previously reported cases from India [8-10,24,25].

knowledge, there are <200 patients with BS [3], of which familial is the commonest one with very few sporadic cases. Cases of BS have been reported in Caucasians, Afro-Americans, and Asian's [4,5]; however, limited reports are available from India [6-10].

Blau syndrome may have varied presentation ranging from 17 months to 45 years of age [11,12]. Arthritis is one of the most common symptoms in patients with BS which is symmetrical, non erosive and usually involves wrists, small joints of hands and feet and ankles. Initially, this may be mistaken as juvenile idiopathic arthritis in the absence of ocular or skin involvement. Frequent granulomatous inflammation may contribute to the development of wrist ankylosis and boutonniere finger deformities [13]. At the later stages, eye involvement (recurrent anterior uveitis, panuveitis with eye pain, photophobia or blurred vision) is most common which may demand close follow-up to avoid further damage and impact on quality of life [14]. Patients with BS may have papular erythematous rash which may be present for short duration. Arthritis is generally seen during first 10 years of life, which generally have limited symptoms or erosive swelling in wrists, ankles, knees, and/or elbows with progressive flexion contractures of the fingers. Uveitis, fever, cranial neuropathies, arteritis, and granulomatous involvement of visceral organs are also seen in some patients [15,16].

There is a limited evidence of BS from India [6-10]. The largest series from India reported seven cases ranging from 2-25 years of age and all these cases had a history of early onset skin rashes, joint involvement, uveitis and had negative ANA. Of these, five from two families had inherited mutation of NOD2 gene and remaining two cases had denovo mutation of the NOD2 gene [6]. Janarthanan M et al., reported three cases (mother and two children; 38/F, 10/M and 5/F) from the same family who presented with uveitis and arthritis and all were RF, ANA, and HLA-B27 negative and were being managed with methotrexate [7].

Another paper reported a female who had symmetric polyarthritis at the age of 3 years and developed granulomatous uveitis at 13 years and was diagnosed as BS with NOD2 mutation at the age of 21 years, when she had disseminated granulomas in liver and kidneys [8]. Mutation at the exon 4 of the NOD2 gene is the diagnostic finding for BS. Commonly, the R334W mutation is noted while other mutations like E600K, Y563S and M513T are also reported [17,18]. Genetic counselling should be conducted, since

BS is an inheritant autosomal dominant disorder, screening of the family of the patient becomes crucial.

In the present case, the symptoms presented started at the age of one year. Her RF, ANA and HLA-B27 were also negative and the diagnosis was made as early onset sarcoidosis/BS of sporadic type and being managed with methotrexate and low dose prednisolone. A recent case series of six patients, who were diagnosed with BS/EOS responded well to the treatment of corticosteroids, NSAIDs, methotrexate, infliximab, adalimumab, anakinra, and canakinumab [19]. Due to the rarity of the syndrome, there is no optimal management. Majority of patients require immunosuppression on a long-term and for ocular signs like cataract or glaucoma, surgery is suggested. For acute presentation, high dose glucocorticoids are administered. Methotrexate, corticosteroids and Tumour Necrosis Factor (TNF) inhibitors remain the standard medications for BS [20]. Data from a study by Matsuda T et al., on 50 cases of BS has shown that treatment with biological agents such as monoclonal antibodies, namely infliximab, adalimumab has avoided blindness [21]. Other biological agents such as canakinumab, tocilizumab or anakira have also shown favourable response [22,23]. The clinical presentation and treatment outcomes of previous Indian studies are summarised in [Table/Fig-3] [8-10,24,25]. Unfortunately, genetic analysis could not be performed due to financial limitations, a common problem in countries like India.

## CONCLUSION(S)

Blau syndrome is an under-recognised and under reported ailment of childhood arthritis which may have multisystem involvement. The onset of arthritis without ocular or skin manifestations may be mistaken as juvenile idiopathic arthritis. Genetic testing to detect the mutation in NOD2 gene is crucial for confirming the diagnosis. Immunosuppressants, monoclonal antibodies and TNF inhibitors have shown favourable outcomes in articular manifestation. Identifying the accurate treatment and analysing the pathogenesis of the disease is essential for better prognosis in future.

## REFERENCES

- [1] Petty RE, Southwood TR, Manners P, Baum J, Glass DN, Goldenberg J, et al. International League of Associations for Rheumatology classification of juvenile idiopathic arthritis: Second revision, Edmonton, 2001. *J Rheumatol*. 2004;31(2):390-92.

- [2] Stoevesandt J, Morbach H, Martin TM, Zierhut M, Girschick H, Hamm H. Sporadic Blau syndrome with onset of widespread granulomatous dermatitis in the newborn period. *Pediatr Dermatol*. 2010;27(1):69-73.
- [3] Velickovic J, Silan F, Bir FD, Silan C, Albuz B, Ozdemir O. Blau syndrome with a rare mutation in exon 9 of NOD2 gene. *Autoimmunity*. 2019;52(7-8):256-63.
- [4] Kanazawa N, Okafuji I, Kambe N, Nishikomori R, Nakata-Hizume M, Nagai S, et al. Early-onset sarcoidosis and CARD15 mutations with constitutive nuclear factor-kappaB activation: Common genetic etiology with Blau syndrome. *Blood*. 2005;105(3):1195-97.
- [5] Rybicki BA, Malirak MJ, Bock CH, Elston RC, Baughman RP, Kimani AP, et al. The Blau syndrome gene is not a major risk factor for sarcoidosis. *Sarcoidosis Vasc Diffuse Lung Dis*. 1999;16(2):203-08.
- [6] Babu K, Rao AP. Clinical profile in genetically proven blau syndrome: A case series from South India. *Ocul Immunol Inflamm*. 2020;29(2):250-56.
- [7] Janarthanan M, Poddar C, Sudharshan S, Seabra L, Crow YJ. Familial Blau syndrome: First molecularly confirmed report from India. *Indian J Ophthalmol*. 2019;67(1):165-67.
- [8] Jindal AK, Pílania RK, Suri D, Gupta A, Gattorno M, Ceccherini I, et al. A young female with early-onset arthritis, uveitis, hepatic, and renal granulomas: A clinical tryst with Blau syndrome over 20 years and case-based review. *Rheumatol Int*. 2021;41(1):173-81.
- [9] Naik AU, Annamalai R, Biswas J. Uveitis in sporadic Blau syndrome: Long-term follow-up of a refractory case treated successfully with adalimumab. *Indian J Ophthalmol*. 2018;66(10):1483-85.
- [10] Jain L, Gupta N, Reddy MM, Mittal R, Barik MR, Panigrahi B, et al. A novel mutation in helical domain 2 of NOD2 in sporadic Blau syndrome. *Ocul Immunol Inflamm*. 2018;26(2):292-94.
- [11] Çakan M, Keskindemirci G, Aydoğmuş Ç, Akı H, Hatipoğlu N, Kiyak A, et al. Coexistence of early onset sarcoidosis and partial interferon- $\gamma$  receptor 1 deficiency. *Turk J Pediatr*. 2016;58:545-49.
- [12] Ong LT, Nachbur U, Rowczenio D, Ziegler JB, Fischer E, Lin MW. A novel nucleotide oligomerization domain 2 mutation in a family with Blau syndrome: Phenotype and function. *Innate Immun*. 2017;23(7):578-83.
- [13] Yi Yong C, Mukhtyar C, Armon K. Blau syndrome treated with sequential biologics. *Rheumatol Adv Pract*. 2018;2(Suppl 1):rky034.028.
- [14] Marin-Noriega MA, Muñoz-Ortiz J, Mosquera C, de-la-Torre A. Ophthalmological treatment of early-onset sarcoidosis/Blau syndrome in a Colombian child: A case report. *Am J Ophthalmol Case Rep*. 2020;18:100714.
- [15] Jha S, Mittal S, Kumar RR, Dhooria A, Rawat A, Dhir V. An unusual cause of deforming erosive arthritis in an adult. *Rheumatology (Oxford)*. 2020;59(3):602.
- [16] Poline J, Fogel O, Pajot C, Miceli-Richard C, Rybojad M, Galeotti C, et al. Early-onset granulomatous arthritis, uveitis and skin rash: Characterization of skin involvement in Blau syndrome. *J Eur Acad Dermatol Venereol*. 2020;34(2):340-48.
- [17] Rosé CD, Pans S, Casteels I, Anton J, Bader-Meunier B, Brissaud P, et al. Blau syndrome: Cross-sectional data from a multicentre study of clinical, radiological and functional outcomes. *Rheumatology (Oxford)*. 2015;54(6):1008-16.
- [18] Sarens IL, Casteels I, Anton J, Bader-Meunier B, Brissaud P, Chédeville G, et al. Blau syndrome-associated uveitis: Preliminary results from an international prospective interventional case series. *Am J Ophthalmol*. 2018;187:158-66.
- [19] Paç Kisaarslan A, Sözeri B, Şahin N, Özdemir Çiçek S, Gündüz Z, Demirkaya E, et al. Blau syndrome and early-onset sarcoidosis: A six case series and review of the literature. *Arch Rheumatol*. 2019;35(1):117-27.
- [20] Matsuda T, Kambe N, Ueki Y, Kanazawa N, Izawa K, Honda Y, et al. Clinical characteristics and treatment of 50 cases of Blau syndrome in Japan confirmed by genetic analysis of the NOD2 mutation. *Ann Rheum Dis*. 2020;79(11):1492-99.
- [22] Lu L, Shen M, Jiang D. Blau syndrome with good responses to tocilizumab: A case report and focused literature review. *Semin Arthritis Rheum*. 2018;47(5):727-31.
- [23] Simonini G, Xu Z, Caputo R. Clinical and transcriptional response to the long-acting interleukin-1 blocker canakinumab in Blau syndrome-related uveitis. *Arthritis Rheum*. 2013;65(2):513-18.
- [24] Agarwal K, Barua S, Adhikari P, Das S, Marak R. Early-onset sarcoidosis and juvenile idiopathic arthritis: A diagnostic dilemma. *Indian J Dermatol Venereol Leprol*. 2016;82(5):542-45.
- [25] Sinha P, Kartik S, Bhatia JK, Choden T. Blau syndrome: A case report of a rare granulomatous disorder. *Indian J Paediatr Dermatol*. 2020;21(2):153-55.

#### PARTICULARS OF CONTRIBUTORS:

1. Consultant Rheumatologist, Department of Rheumatology, Santokba Durlabhji Memorial Hospital and Medical Research Institute, Jaipur, Rajasthan, India.
2. Assistant Professor, Department of Pathology, Rajasthan University of Health Sciences, Jaipur, Rajasthan, India.
3. Assistant Professor, Department of Microbiology, PDU Medical College, Churu, Rajasthan, India.

#### NAME, ADDRESS, E-MAIL ID OF THE CORRESPONDING AUTHOR:

Dr. Seema Singh,  
Assistant Professor, Department of Pathology, Rajasthan University of Health Sciences,  
Jaipur, Rajasthan, India.  
E-mail: drseemasingh@rediffmail.com

#### PLAGIARISM CHECKING METHODS: [Jain H et al.]

- Plagiarism X-checker: Mar 08, 2021
- Manual Googling: Sep 26, 2022
- iThenticate Software: Sep 27, 2022 (14%)

#### ETYMOLOGY: Author Origin

#### AUTHOR DECLARATION:

- Financial or Other Competing Interests: None
- Was informed consent obtained from the subjects involved in the study? Yes
- For any images presented appropriate consent has been obtained from the subjects. Yes

Date of Submission: **Mar 05, 2021**

Date of Peer Review: **Apr 29, 2021**

Date of Acceptance: **Sep 29, 2022**

Date of Publishing: **Nov 01, 2022**