

# Awake Fiberoptic Intubation in Vocal Cord Palsies

NEETA SANTHA<sup>1</sup>, DIKSHA DMELLO<sup>2</sup>, PAKHI SHARMA<sup>3</sup>

## ABSTRACT

Respiratory distress associated with vocal cord palsy can be attributed to recurrent laryngeal nerve injury. Bilateral vocal cord palsy can cause adduction of cords and respiratory distress. Airway, in these patients, can be compromised and result in unanticipated difficult intubation. The time frame to pass tube in such situations are less. This is a case series on successful airway management of three patients who presented with recurrent nerve palsy and airway obstruction. Thus the “cannot intubate-cannot oxygenate” situation was avoided in all the patients.

**Keywords:** Airway management, Intubate, Oxygenate

## INTRODUCTION

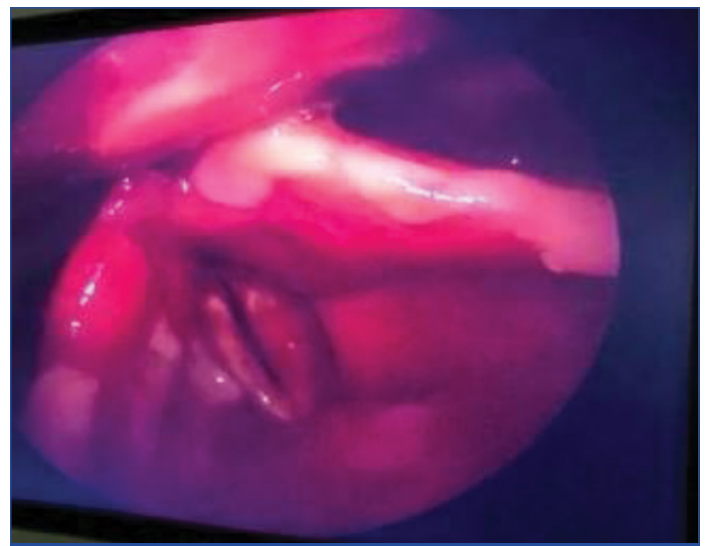
Recurrent laryngeal nerve injuries are a common cause for vocal cord paralysis. The causes include surgical intervention, malignancy, viral illness, diabetic neuropathy, and trauma. Endotracheal intubation is also responsible for significant number of recurrent laryngeal nerve palsies [1]. Vocal cord paralysis is a lesser known, important complication of intubation. Its incidence ranges from 0.1%-0.2% [2]. Such patients can present with an extremely narrow glottic opening and can result in unanticipated difficult airway. Awake fiberoptic intubation is an option in these situations which has a higher success rate. For any procedure to be successful, careful preoperative planning is essential. This is a case series on three patients who presented with vocal cord palsies. Proper airway assessment and preparation helped in successful intubations in these patients.

## CASE SERIES

### Case 1

A 71-year-old male presented with left capsuloganglionic bleed. He was known to have bronchial asthma since childhood, and was on bronchodilators. The patient was intubated in the Intensive Care Unit (ICU) with oral endotracheal tube 8.0 mm Internal Diameter (ID), fixed at 23 cm in view of poor Glasgow Coma Scale score (GCS), and risk of aspiration. He was extubated after 3 days in view of improved GCS and intact gag reflex. He developed respiratory distress 2 hours later and was posted for emergency tracheostomy, under General Anaesthesia (GA). On preanaesthetic evaluation, the patient was in respiratory distress with hoarseness of voice, tachypnea with a respiratory rate of 40 breaths/min and a Oxygen Saturation (SpO<sub>2</sub>) of 97% with oxygen on flow with via face mask at 5L/min. Video laryngoscopy under local anaesthesia showed oedematous vocal cords, in adducted position with poor cord movements on respiration [Table/Fig-1].

The patient was shifted to the operative room in a propped-up position. The plan of anaesthesia was awake fibreoptic intubation. Difficult airway cart was kept ready. After confirming nil per oral status, standard American Society of Anesthesiologists (ASA) monitors were connected. The patient remained in propped-up position at a 45° angle on the operating table due to respiratory distress. Oxygen was supplemented with nasal prongs at 2L/min. Nasal airway was prepared with lignocaine and adrenaline-soaked pledgets (1:2,00,000) kept for five minutes. Awake fibre optic intubation was carried out and the fiberoptic scope was



[Table/Fig-1]: Vocal cords in adducted position.

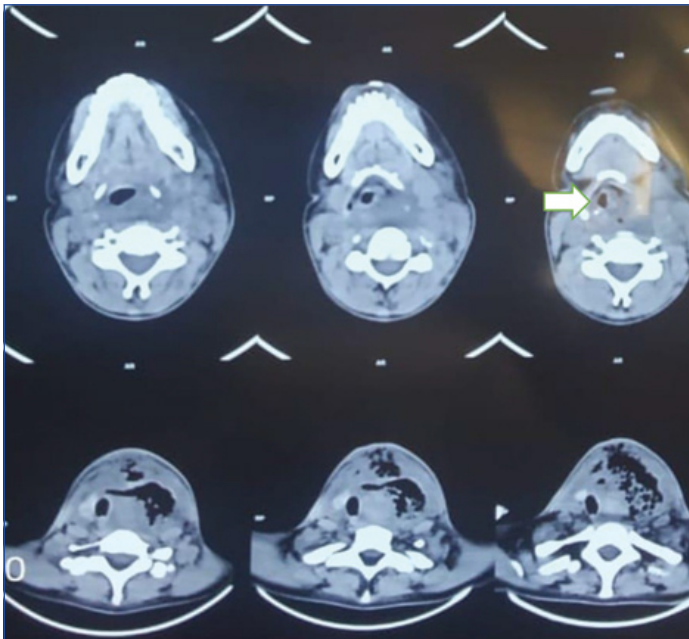
introduced through the nasal passage. Airway was anaesthetised using the spray-as-you-go technique with 2% lignocaine solution. Even mild sedation was deferred as the patient had a compromised airway and was in respiratory distress. On bronchoscopy, vocal cords appeared in adducted position and the scope was passed between the cords. A 7.5 mm ID nasal Right Angle Endotracheal (RAE) tube was railroaded into the trachea under vision. There was difficulty in negotiating the tube via the narrow space in between the cords. Position of the endotracheal tube was confirmed with End Tidal Carbon Dioxide (ETCO<sub>2</sub>) tracing. Once the tube was secured, induction was done with inj. fentanyl 50 mcg, and 8% sevoflurane. After induction, paralysis was achieved using inj. atracurium 50 mg. Maintained with O<sub>2</sub>:N<sub>2</sub>O in the ratio of 1:1 with sevoflurane at 1%. The patient underwent tracheostomy and a size 8 tracheostomy tube was inserted and confirmed with ETCO<sub>2</sub> tracing. Intraoperative vitals were stable and the procedure was uneventful. The patient was reversed after resuming spontaneous breathing. He was shifted to Medicine ICU on T piece at 6L/min of oxygen.

### Case 2

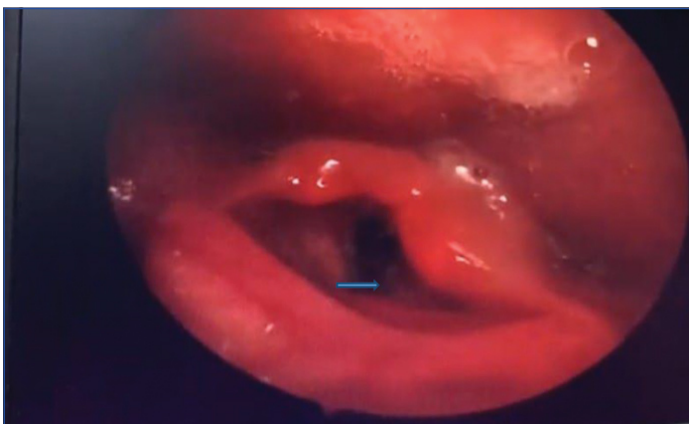
A 37-year-old female came with complaint of neck swelling since two years. Swelling was insidious in onset, gradually progressive, associated with dysphagia since 1 month; dysphagia was present more for solids than liquids. There was associated change in voice

since 1 month but there were no complaints of difficulty in breathing. Patient also complained of cough with expectoration and fever for 1 day. She was tachypneic and room air saturation was 96%. She presented with low blood pressure of 86/50 mmHg and fine crepitations over right basal region.

Computed Tomography (CT) scan of the neck was done which showed peripherally enhancing multiloculated lesion with air foci within (6×7×8.2 cms) the anterior aspect of the neck arising from the thyroid gland and reaching upto left parapharyngeal space superiorly till hyoid bone, inferiorly to superior mediastinum into prevascular space, medially compressing and displacing trachea to the right, posteriorly loss of fat plane of isthmus; complete thrombosis of left Internal Jugular Vein (IJV) Laryngeal inlet was compressed by the mass [Table/Fig-2].



[Table/Fig-2]: CT scan showing narrow airway.



[Table/Fig-3]: Paralysed left vocal cord.

Indirect laryngoscopy showed that there was posterior pharyngeal wall bulge, bulky arytenoids with fixed left vocal cord [Table/Fig-3]. The right-sided cord was mobile on respiration and phonation.

Patient was posted for biopsy and tracheostomy under general anaesthesia (GA). The plan of anaesthesia was awake nasal fiberoptic intubation. The procedure was explained and consent was taken from the patient. Patient was given nebulisation with 3 mL of 2% lignocaine. Pledgets soaked in 4% lignocaine were inserted into the nasal cavity.

After preparation of the airway, patient was shifted to the operating table. Oxygen supplementation was done with 2 liters of oxygen by nasal prongs. Standard monitors were connected and difficult airway cart was kept ready. Premedication was done with 0.2 mg of glycopyrrolate, 0.5 mg midazolam and 25 µg fentanyl. Nasal RAE

tube 7.5 mm, was railroaded into the insertion cord of the fiberoptic bronchoscope. The bronchoscope could be passed into the trachea but there was difficulty in inserting the endotracheal tube at the level of laryngeal inlet, as there was narrowing of airway at this level. There was difficulty in pushing the tube further down into trachea. The tube was kept at this position and the bronchoscope was withdrawn carefully. The circuit with ETCO<sub>2</sub> was connected to confirm the tube position. Then an airway exchange catheter (Cooks Airway Exchange 14F) was passed through the tube into the trachea and tube was further pushed inside with the help of the catheter. Tube was fixed after confirming with ETCO<sub>2</sub> and auscultation for bilateral air entry. Induction was done with propofol and relaxant used was atracurium. Anaesthesia was maintained with oxygen nitrous oxide and sevoflurane. Tracheostomy and biopsy was done. After the procedure, patient was reversed and shifted to postoperative ICU on T piece. Later biopsy confirmed anaplastic carcinoma of the postcricoid region.

### Case 3

A 70-year-old female patient was posted for direct laryngoscopy and biopsy of the vocal cord growth. She had hoarseness of voice, for one year. Indirect laryngoscopy revealed a fixed left vocal cord and mobile right vocal cord. She didn't have any other co-morbidities.

Plan of anaesthesia was awake fiberoptic intubation. Nebulisation of the airway was done with 4% lignocaine. The patient was shifted to the operating table. Oxygen was connected with nasal prongs at 2 L/min. Mild sedation was given with 0.5% midazolam. 7.5 mm nasal RAE tube was railroaded into the insertion cord of the fiberoptic bronchoscope. Spray-as-you-go technique with 2% lignocaine was done. Bronchoscope was passed through the nasal passage and once the tracheal entry was confirmed, endotracheal tube was inserted into trachea. After confirmation of tube placement, anaesthesia was introduced with fentanyl, propofol and atracurium. After the procedure patient was extubated fully awake.

## DISCUSSION

The larynx is the most common site of airway injury during endotracheal intubation, including haematoma, arytenoid subluxation and vocal cord paralysis [3]. In the first case, the patient developed vocal cord palsy and stridor following intubation. Bilateral vocal cord paralysis following endotracheal intubation is much less appreciated, and often overlooked. When coupled with head and neck surgery, it causes diagnostic confusion [4]. Hoarseness is a symptom that appears usually after intubation. There can be varied reason for the palsy. The cricoid cartilage or vocal cords can be pushed to the oblique position of the neck by the posterior surface of endotracheal tube cuffs, leading to neuropraxia [5].

Unilateral vocal cord paralysis as observed in the second case, manifests as change in voice quality, perceived as dysphonia, vocal fatigue, decreased range and fatigue that can affect communication skills. The unilateral paralysis of vocal fold can be due to injury that involves the vagus nerve, which can be proximal or distal. The most common cause is iatrogenic [6]. Vocal cord palsy can also lead to an inefficient cough mechanism, which can lead to aspiration and pneumonia. A more serious complication is the development of obstruction, stridor and respiratory failure. There was difficulty in passing the tube down the trachea. Tube exchanger was the savior in this scenario and with the help of this airway gadget, trachea was successfully intubated.

Nagata M et al., described a case of vocal cord palsy in a 32-month-old child with left recurrent laryngeal nerve palsy. The child was posted for endoscopic evaluation of vocal cords. The child was induced with sevoflurane and paralysed with rocuronium. After the procedure, the airway was extubated using an airway exchange catheter. After confirming adequate spontaneous breathing, the

patient was observed in postoperative ICU. In the second case, as described in the case series an airway exchange catheter was used to push endotracheal the tube further into the trachea [7].

In another case, a 57-year-old male patient, who had progressive breathlessness due to thyroid swelling, was posted for thyroidectomy. He was a known case of acromegaly with features of a difficult airway. The plan of anaesthesia was awake fiberoptic intubation. Aerosolisation of the airway with local anaesthesia was done. Intravenous sedation and sevoflurane inhalation was used to secure airway with videolaryngoscopy assisted fiberoptic intubation. Here, in the second case, video laryngoscope was tried, but was unsuccessful in securing the airway. So awake fiberoptic was tried for the same [8].

Diagnostically, it is necessary to examine the structure and function of the larynx [9]. The risk greatly increases with increasing age, diabetes mellitus, hypertension, and duration of surgery [10]. In serious cases, reintubation or tracheostomy is required to relieve the obstruction. In the above case, incomplete bilateral recurrent laryngeal nerve palsy was suspected with vocal cord oedema most likely due to endotracheal intubation.

In another published report, a patient developed post-traumatic severe tracheal stenosis. His condition deteriorated suddenly and emergency intubation was tried, but endotracheal tube could not be pushed beyond the area of critical stenosis and it was 0.5 cm above the carina. Immediate extracorporeal circulation was established and trachea was exposed via thoracotomy incision and tracheal tube was inserted in the left main bronchus [11].

The intubating fiberoptic scope has a quoted success rate of 88%-100% [12]. Some authors still consider it to be the gold standard in anticipated difficult airway management. The introduction of supraglottic airway devices and video laryngoscope has dramatically changed airway management. In spite of advances in these airway devices error in airway assessment and strategic planning can lead to devastating consequences. National Audit Project of the Royal College of Anaesthetists, United Kingdom, concluded that judgemental errors, inappropriate choice of equipment and inadequate training can be contributory factors in major airway complications [13]. It is therefore imperative that Fiberoptic Intubation (FOI) is considered in a clinical context as part of a complete airway strategy.

## CONCLUSION(S)

Vocal cord paralysis following endotracheal intubation is a lesser known pathology but is a worrisome situation in the postextubation period where there is risk of airway obstruction and losing the airway following repeated failed attempts. Emphasis on prevention and recognition of this entity is important for the anaesthesiologist to allow an informed decision and planned intervention in the setting of complications.

## REFERENCES

- [1] Culp JM, Patel G. Recurrent Laryngeal Nerve Injury. In: StatPearls . Treasure Island (FL): StatPearls Publishing. 2022.
- [2] Tasli H, Kara U, Gokogoz MC, Aydin U. Vocal Cord Paralysis Following Endotracheal Intubation. Turk J Anaesthesiol Reanim. 2017;45(5):321-22.
- [3] Nazal CH, Vilches AA, Maran CV, Contreras KG , Valenzuela CN , Ventí PB, et al. Vocal cord paralysis after endotracheal intubation: an uncommon complication of general anaesthesia. Brazilian Journal of Anaesthesiology. 2018;68(6):637-40.
- [4] Matta RI, Halan BK, Sandhu K. Postintubation recurrent laryngeal nerve palsy. A review. J Laryngol Voice. 2017;7(2):25-28.
- [5] Tasli H, Kara U, Gökğöz MC, Aydin Ü. Vocal cord paralysis following endotracheal intubation. Turk J Anaesthesiol Reanim. 2017; 45(5):321-22.
- [6] Williamson AJ, Shermetaro C. Unilateral Vocal Cord Paralysis. [Updated 2022 Feb 7]. In: StatPearls. Treasure Island (FL): StatPearls Publishing; 2022 Jan-. Available from: <https://www.ncbi.nlm.nih.gov/books/NBK535420/>
- [7] Nagata M, Shimomura Y, Hara Y, Nakamura T, Hayakawa S , Komura H, et al., A devised strategy for tracheal extubation for predicted difficult airway in a child with unilateral vocal cord paralysis: A case report. JA Clin Rep. 2017;(21):02-04.
- [8] Sun X, Chen C, Zhou R, Chen G, Jiang C, Zhu T, et al. Anaesthesia and airway management in a patient with acromegaly and tracheal compression caused by a giant retrosternal goiter: A case report. Journal of International Medical Research. 2021;49(4):300060521999541.
- [9] Young VN, Smith LJ, Rosen C. Voice outcome following acute unilateral vocal cord paralysis. Ann Otol Rhinol Laryngol. 2013;122(3):197-04.
- [10] Kikura M, Suzuki K, Itagaki T, T Takada T, Sato S. Age and comorbidity as risk factors for vocal cord paralysis associated with tracheal intubation. Br J Anaesth. 2007;98:524-30.
- [11] Zhou YF, Zhu SJ, Zhu SM, An XX. Anaesthetic management of emergent critical tracheal stenosis. J Zhejiang Univ Sci B. 2007;8(7):522-25.
- [12] Wong J, Lee JSE, Wong TGL, Iqbal R, Wong P. Fiberoptic intubation in airway management: a review article. Singapore Med J. 2019;60(3):110-18.
- [13] Cook TM, Woodall N, Harper J, Benger J. Fourth National Audit Project. Major complications of airway management in the UK: results of the Fourth National Audit Project of the Royal College of Anaesthetists and the Difficult Airway Society. Part 2: intensive care and emergency departments. Br J Anaesth. 2011;106(5):632-42.

### PARTICULARS OF CONTRIBUTORS:

1. Associate Professor, Department of Anaesthesia, Kasturba Medical College, Mangalore, Manipal Academy of Higher Education, Manipal, Karnataka, India.
2. Postgraduate, Department of Anaesthesia, Kasturba Medical College, Mangalore, Manipal Academy of Higher Education, Manipal, Karnataka, India.
3. Postgraduate, Department of Anaesthesia, Kasturba Medical College, Mangalore, Manipal Academy of Higher Education, Manipal, Karnataka, India.

### NAME, ADDRESS, E-MAIL ID OF THE CORRESPONDING AUTHOR:

Neeta Santha,  
Associate Professor, Department of Anaesthesia, Kasturba Medical College,  
Mangalore, Karnataka, India.  
E-mail: drneetas@yahoo.com

### PLAGIARISM CHECKING METHODS: [\[Jain H et al.\]](#)

- Plagiarism X-checker: Jun 19, 2022
- Manual Googling: Jul 19, 2022
- iThenticate Software: Jul 20, 2022 (16%)

### ETYMOLOGY: Author Origin

### AUTHOR DECLARATION:

- Financial or Other Competing Interests: None
- Was informed consent obtained from the subjects involved in the study? Yes
- For any images presented appropriate consent has been obtained from the subjects. No

Date of Submission: **Jun 15, 2022**  
Date of Peer Review: **Jul 06, 2022**  
Date of Acceptance: **Jul 21, 2022**  
Date of Publishing: **Nov 01, 2022**