


# Classical Hodgkin's Lymphoma Presenting as Erythroderma

KUMAR PARIMALAM<sup>1</sup>, R PRIYAVATHANI<sup>2</sup>, KANNAN RAJKUMAR<sup>3</sup>, RAJAN MANIPRIYA<sup>4</sup>, ELANGO VAN SUPRIYA<sup>5</sup>

## ABSTRACT

Hodgkin's Lymphoma (HL) with direct cutaneous involvement is uncommon, unlike non specific paraneoplastic skin changes, which can occur during the course of the disease. Direct cutaneous infiltration commonly affects the chest and manifests as papules and plaques. Nodules in some patients may ulcerate. Paraneoplastic manifestations can be eczematous itchy papules or lichenified plaques adjacent to the affected lymph nodes. Authors' reported a case of a 31-year-old female with erythroderma, of four months duration, who did not respond to treatment with corticosteroids and cyclosporine. Skin biopsy showed minimal epidermotropism without mitotic cells. Immunohistochemistry (IHC) showed CD3, CD4, CD5 and CD8 positivity and CD15, CD 20 negativity. She had frequent exacerbations while on treatment with steroids. Amongst this confusing clinical picture, it was the emergence of an axillary lymph node, after two months of initiating treatment which on histopathology was compatible with HL and on IHC positive for CD3, CD20 and CD30 and negative for CD15. These findings confirmed the diagnosis as classical HL. The present case is being reported to highlight the importance of thorough clinical examination with particular reference to lymph node screening.

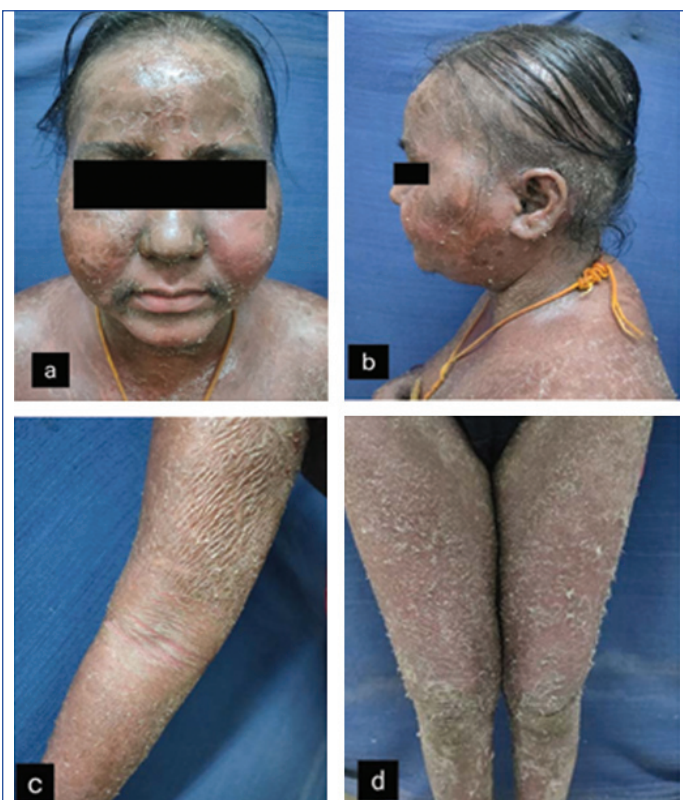**Keywords:** Atypical exfoliative dermatitis, Dermatogenic lymphadenopathy, Epidermotropism, Immunohistochemistry

## CASE REPORT

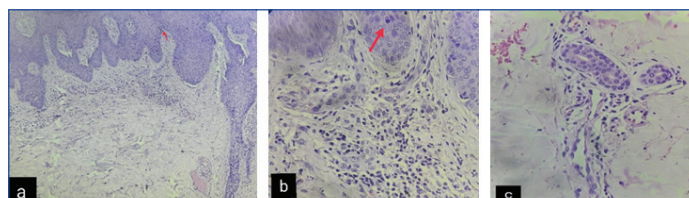
A 31-year-old female presented with erythema and scaling all over the body for the past four months [Table/Fig-1]. The patient developed spontaneous occipital headache, after complete neurological and ophthalmological evaluation including Computed Tomography (CT) Brain, Magnetic Resonance Imaging (MRI), was diagnosed as idiopathic intracranial hypertension and was treated with Tab. phenobarbitone and Tab. acetazolamide 250 mg thrice daily. There was no significant medical or family history.

She developed generalised erythema and scaling all over the body involving more than 90% body surface area associated with intense itching, after one month of starting the above two drugs. Drug-induced erythroderma was suspected and Tab. phenobarbitone was stopped while Tab. acetazolamide was continued. In spite of the change in regimen, erythroderma did not settle. Hence, the patient was admitted in the ward.

The patient's complete blood count, renal function test, liver function test was within normal limits. Peripheral smear showed neutrophilic leucocytosis. She was started on Inj. dexamethasone 2 cc intramuscular once daily followed by Cap. cyclosporine 200 mg. Erythroderma started resolving and hence steroids were tapered by 5 mg per week after two weeks of initiating treatment. At a dosage of Tab. prednisolone 10 mg/day, she developed pruritus followed by fever, chills, headache, facial oedema, alopecia, and generalised hyperpigmentation. The lesions increased progressively and there was profuse scaling all over the body surface in spite of continuing the above drugs for two weeks. Hence, patient was initiated to parenteral steroid of Inj. dexamethasone 2 cc in the morning and 1 cc in the night. In the meantime, skin biopsy revealed hyperkeratosis, parakeratosis, focal acanthosis, and minimal epidermotropism. Dermis showed perivascular lymphohistiocytic infiltrate [Table/Fig-2]. In view of epidermotropism and absence of eosinophils, cutaneous T-cell lymphoma was suspected. However, her peripheral smear did not show Sézary cells. The IHC of the skin was positive for CD3 in 90% of lymphoid cells, CD4 and CD8 in perivascular lymphocytes, CD5 focal positivity in lymphocyte aggregates in deeper dermis and was negative for CD20 [Table/Fig-3].

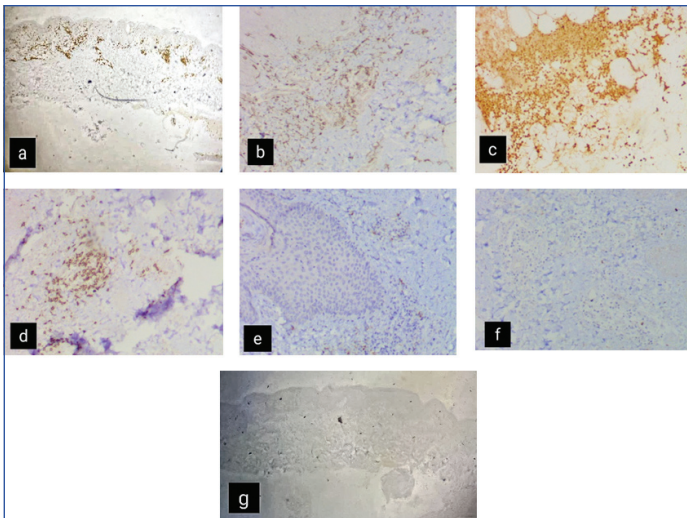


**[Table/Fig-1]:** a) Erythema, scaling and pigmentation over face; b) Lateral profile of face showing alopecia; c) Erythema and fissuring over elbow; d) Diffuse erythema and exfoliative dermatitis of lower extremities.



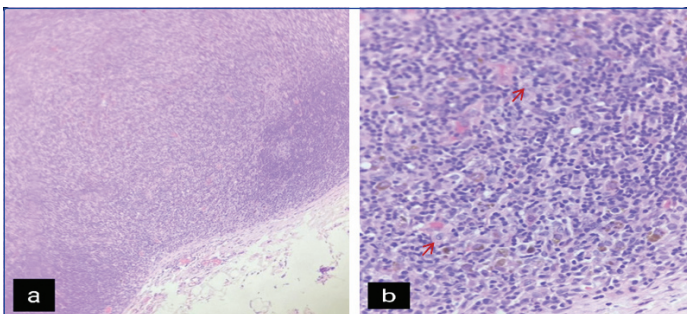
**[Table/Fig-2]:** a) Epidermotropism (red arrow) (H&E, 10X); b) and c) Perivascular lymphocytic inflammatory infiltrate (H&E, 40X).





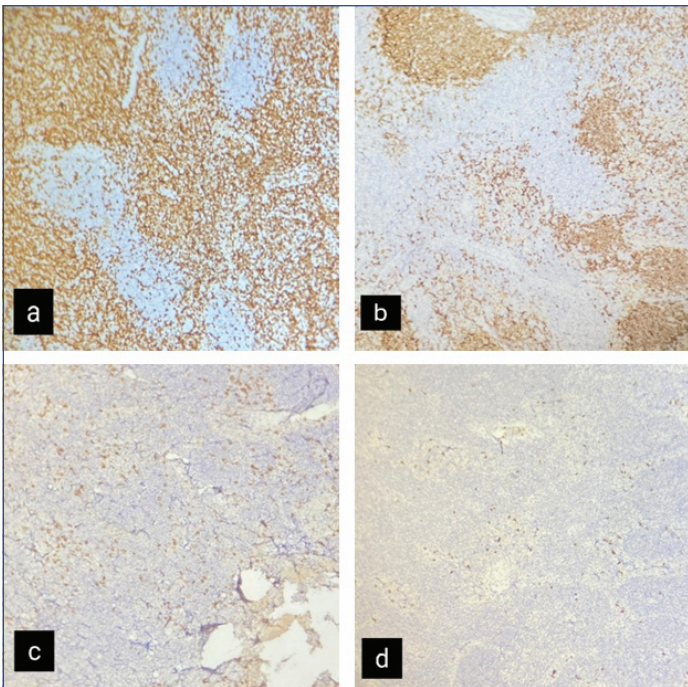
**[Table/Fig-3]:** a) CD3; b) CD4; c) CD5; d) CD8 positivity in lymphocytes; e) CD15; f) CD30; g) CD20 negative IHC of skin (40X).

After two weeks of 3 cc dexamethasone per day, a single firm axillary lymph node of size 2 cm was observed. Ultrasonography (USG) of axilla showed multiple axillary lymph nodes, with preserved fatty hilum. Axillary lymph node excisional biopsy under general anaesthesia was performed, which on histopathological examination revealed effaced lymph node parenchymal architecture and focal atretic germinal centers composed of sheets of mature activated lymphocytes. It also showed intervening large mononuclear cells with vesicular nucleus and conspicuous nucleoli in contrast to lipomelanotic reticulosis of dermatogenic lymphadenopathy which showed large melanin granules in intra and extra cytoplasmic cells. Few binucleate cells and pigment laden histiocytes were present. Sinusoids were dilated and congested [Table/Fig-4]. The IHC study of the lymph node showed CD3 positivity in 90% of lymphoid cells, CD20 positivity in 80% lymphocytes centered predominantly around atretic germinal centers and in large cells in paracortical region, CD30 membranous positivity in large cells, with 30% large cells showing cytoplasmic dot positivity. It was negative for CD15 [Table/Fig-5]. With these findings, classical HL was diagnosed.

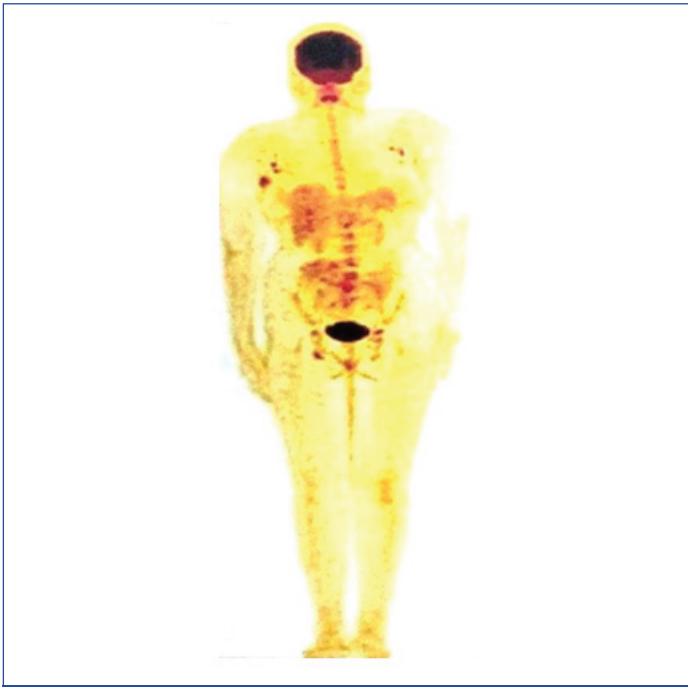

**[Table/Fig-4]:** a) Lymphocyte parenchyma with effaced architecture with focal atretic centers composed of sheets of activated lymphocytes (H&E, 10X); b) Large mononuclear cells with vesicular nucleus and conspicuous nucleoli (red arrow) (H&E, 40X).

After IHC of axillary lymph node biopsy, Ultrasonography (USG) neck and Contrast Enhanced Computed Tomography (CECT) of neck, chest and abdomen were done in collaboration with medical oncology and haematology team. USG neck showed subcentrimetric nodes noted in level Ia, Ib, II, III, IV regions bilaterally. Contrast enhanced CT of neck, chest, and abdomen showed no abnormality other than the nodes already detected by USG neck. Positron Emission Tomography (PET) and CT showed diffuse cutaneous thickening and minimal subcutaneous fat stranding in infra-umbilical region with minimal increased metabolic activity. Diffuse increased metabolic activity in multiple vertebrae and bilateral pelvic bones with no corresponding CT changes. Final diagnosis of HL involving bilateral cervical, axillary, external iliac and inguinal lymphadenopathy spleen, skin and bone marrow [Table/Fig-6] was confirmed.



**[Table/Fig-5]:** Immunohistochemistry of axillary node biopsy (40X) showing: a) CD3; b) CD20; c) CD30 positivity; d) CD15 negative.

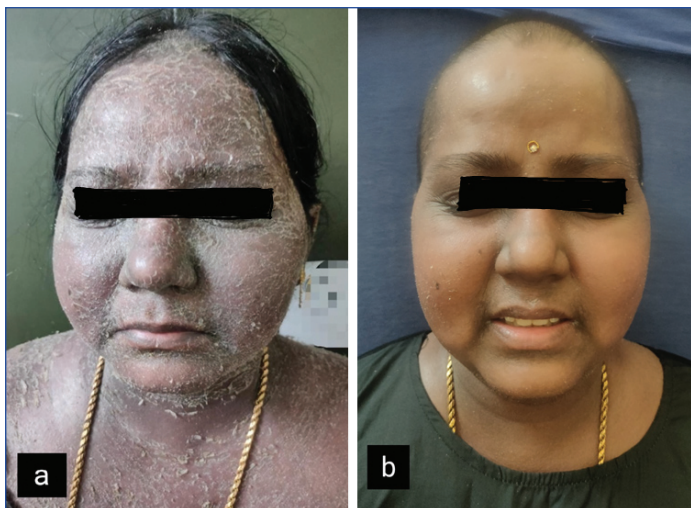

**[Table/Fig-6]:** The 18-fluorodeoxyglucose Positron Emission Tomography-computed tomography whole body scan showing metabolic activity in bilateral cervical, axillary, external iliac and inguinal lymphadenopathy, spleen, cutaneous and marrow involvement.

The patient was started on ABVD (drugs doxorubicin hydrochloride (Adriamycin), bleomycin sulfate, vinblastine sulfate, and dacarbazine) regimen. She showed reduction in erythema and scaling after one week and a decrease in size of the lymph node in two weeks after therapy. The patient is under follow-up at a biweekly interval. There was significant overall improvement after one month [Table/Fig-7]. There were no significant side-effects of drugs, and she has completed four cycles of chemotherapy.

**DISCUSSION**

Hodgkin's lymphoma is a curable malignancy representing around 10% of all lymphomas [1]. It originates from germinal center or postgerminal center B-cells, and the hallmark is the presence of Reed-Sternberg cell. Erythroderma is an inflammatory disorder in which generalised erythema and scaling involving more than 90% of the body surface area occurs. It is a morphological



**[Table/Fig-7]:** a) Prechemotherapy status with exfoliative dermatitis; b) After 4 cycles of chemotherapy.

reaction pattern of skin due to various causes like psoriasis, atopic dermatitis, contact dermatitis, malignancy and drug intake [2]. In HL, erythroderma occurs late in the course of the disease as a para neoplastic syndrome. Pal S and Haroon TS, have reported an incidence of 5.5% of HL in a series of 90 erythrodermas [3]. Clinical examination and prompt investigations for various etiopathological factors helps in the early diagnosis and appropriate management of erythroderma.

Cutaneous manifestations of HL include solitary cutaneous ulcer, eczematous plaques, red rash, nodule, erythroderma and pruritus [4-7]. Most of these cutaneous manifestations were present in the index patient [Table/Fig-8], and she also developed axillary lymph node while on treatment for erythroderma. But, she initially presented with scaling and erythema and underwent remissions and exacerbations.

| Variables         | Dhull AK et al., [4]     | Asad U et al., [5] | Khawandanah M et al., [6] | Hakkou D et al., [7] | Present case, 2022                       |
|-------------------|--------------------------|--------------------|---------------------------|----------------------|--|
| Age (years)       | 22                       | 28                 | 46                        | 30                   | 31                                       |
| Duration          | 2 years                  | 8 months           | 3 months                  | 16 months            | 4 months                                 |
| Sequence          | Lymph node to skin       | Lymph node to skin | Lymph node to skin        | Lymph node to skin   | Skin to lymph node                       |
| Cutaneous finding | Solitary cutaneous ulcer | Eczematous plaques | Red rash                  | Nodule               | Erythroderma<br>Pigmentation<br>Pruritus |

**[Table/Fig-8]:** Cutaneous manifestations of Hodgkin's lymphomas compared to previous study [4-7].

Specific neoplastic involvement can be primary (confined to the skin) or secondary to systemic involvement (metastatic). Hodgkin's lymphomas represents 0.58% of all diagnosed cancers with slight male predominance (1.1:1), in contrast to the index patient [8]. It shows a bimodal peak with age between 25 and 30 years as in the index case and between 75 and 80 years [9].

Most common presentation of HL is painless lymphadenopathy, only one-third of patients present with B symptoms like- unexplained fever, drenching night sweats and weight loss, intermittent fever (Pel-Ebstein fever), pruritus. Whereas, the present case had all the above mentioned symptoms [10]. Modes of spread of the disease to the skin include hematogenous dissemination, direct extension from involved lymph nodes, and retrograde lymphatic spread from involved proximal lymph nodes [11]. Skin involvement in the index case could have been by haematogenous spread or by lymphatic spread rather than a paraneoplastic presentation as skin showed IHC markers positivity.

Hodgkin's lymphomas classically presents with painless multiple lymphadenopathy, of India rubber consistency. Unlike non hodgkin's

lymphomas subtypes, skin involvement of HL is extremely rare. The HL is characterised by orderly spread of disease from one lymph node group to another. Isolated extra lymphatic involvement in the absence of nodal disease is rare. Visceral involvement may be secondary to extension from adjacent lymph node regions or may be hematogenous. The HL only rarely involves central nervous system and skin.

The index case was positive for CD3 both in the skin and lymph node which is a rare presentation. Literature search has shown convincingly that majority of classical HL are of B cell origin and HL cases of unequivocal T-cell origin are extremely rare [12]. The largest series of classical HL analysed for T-cell marker expression showed 5% positivity of cases in the following rank order: CD2 > CD4 > CD3 > CD5 > CD8. Interestingly, 2% expressed more than one T-cell marker [11]. In the index patient, the common T-cell marker expression between skin and lymph node was found to be CD3 positivity [13,14].

Meticulous search for lymphadenopathy in atypical erythroderma patients will lead to unearthing of HL, and investigations including IHC and Positron Emission Tomography and Computed Tomography (PET-CT) scans will confirm the stage of lymphoma, as the prognosis grossly depends on the staging.

Cutaneous involvement in HL is associated with diffuse lymphadenopathy, late stage disease and poor prognosis. [4]. The present case is an exception where the patient presented with paraneoplastic syndrome of classical HL in the skin with findings of atypical erythroderma, cyclical exfoliative dermatitis and Pel-Ebstein type of B symptoms [5]. Also PET-CT showed Standardised Uptake Value (SUV) for skin as 1.2 which is in favour of reactive secondary rather than metastasis. Treatment options for HL include systemic chemotherapy with or without radiotherapy [15]. The index patient was started on ABVD (Inj. adriamycin 30 mg intravenous (i.v.), Inj. bleomycin 15 U i.v., Inj. Vinblastine 6 mg intravenous, Inj. dacarbazine 500 mg). Following chemotherapy, patient developed nausea and vomiting which subsided after appropriate symptomatic treatment. After completion of four cycles of chemotherapy, reduction in size of enlarged lymph nodes was noted, erythroderma decreased, scalp hair growth restarted and darkness of skin reduced.

Erythroderma is a very uncommon initial presentation of HL. The finding of single enlarged axillary lymph node during the course of disease helped to arrive at the diagnosis clearly. Meticulous clinical examination, serial biopsy and detailed immunohistochemical analysis is mandatory for the early diagnosis of HL.

## CONCLUSION(S)

This present case nicely depicts the fact that a patient of atypical progressive erythroderma occurring in a cyclical pattern of erythema and exfoliative dermatitis, in the background of multiple non contiguous lymphadenopathy not responding to conventional immunosuppressive agents is an ominous sign. Histopathology and IHC of both skin and lymph node to be performed in such cases for early diagnosis of underlying lymphoma. The PET-CT picks up metabolically active spots in the bone, other viscera and distinguishes between reactive lesions and organic secondaries.

## Acknowledgement

The authors are extremely thankful and express their sincere gratitude to Dr. Bharathi Vidhya Jayanthi (Director- Institute of Pathology), Dr. Geetha Devadas and Dr. Padmavathi, (Professors of Institute of Pathology, Madras Medical College), whose immense help led to the confirmation of diagnosis.

## REFERENCES

- [1] Jemal A, Siegel R, Ward E, Hao Y, Xu J, Thun MJ. Cancer statistics, 2009. *CA Cancer J Clin.* 2009;59(4):225-49.
- [2] Kingai-Asadi A, Freedberg IM. Exfoliative dermatitis. *Fitzpatrick's Dermatology in general medicine.* 6<sup>th</sup> ed. New York: McGraw-Hill. 2003:436-31.



- [3] Pal S, Haroon TS. Erythroderma: A clinic-etiological study of 90 cases. *Int J Dermatol.* 1998;37(2):104-07.
- [4] Dhull AK, Soni A, Kaushal V. Hodgkin's lymphoma with cutaneous involvement. *BMJ Case Rep.* 2012;2012:bcr2012007599.
- [5] Asad U, Austin B, Sturgeon A, Stetson C. Paraneoplastic eczematous eruption associated with Hodgkin's lymphoma. *Proc (Bayl Univ Med Cent).* 2019;32(4):587-88.
- [6] Khawandanah M, Kraus T, Cherry M. Refractory classical Hodgkin lymphoma presenting with atypical cutaneous involvement and diagnosis of ZZ Phenotype alpha-1 antitrypsin deficiency. *Case Rep Hematol.* 2014;2014:642868.
- [7] Hakkou D, Belefqih I, Sabri S, Dikhaye S, Bachir H, Hamaz S, et al. Primary Cutaneous Hodgkin's Lymphoma: An Extremely Rare Entity. *Cureus.* 2021;13(11):e19272.
- [8] Shenoy P, Maggioncalda A, Malik N, Flowers CR. Incidence patterns and outcomes for Hodgkin lymphoma patients in the United States. *Adv Hematol.* 2011;2011:725219. Doi: 10.1155/2011/725219. Epub 2010 Dec 16. PMID: 21197477; PMCID: PMC3010617.
- [9] Ansell SM, Armitage JO. Management of Hodgkin lymphoma. *Mayo Clin Proc.* 2006;81(3):419-26. Doi: 10.4065/81.3.419. PMID: 16529147.
- [10] Gallamini A, Hutchings M, Ramadan S. Clinical presentation and staging of Hodgkin lymphoma. *Semin Hematol.* 2016;53(3):148-54. Doi: 10.1053/j.seminhematol.2016.05.005.
- [11] Tzankov A, Bourgau C, Kaiser A, Zimpfer A, Maurer R, Pileri SA, et al. Rare expression of T-cell markers in classical Hodgkin's lymphoma. *Mod Pathol.* 2005;18(12):1542-49.
- [12] Müschen M, Rajewsky K, Bräuninger A, Baur AS, Oudejans JJ, Roers A, et al. Rare occurrence of classical Hodgkin's disease as a T cell lymphoma. *J Exp Med.* 2000;191(2):387-94.
- [13] Seitz V, Hummel M, Marafioti T, Anagnostopoulos I, Assaf C, Stein H. Detection of clonal T-cell receptor gamma-chain gene rearrangements in Reed-Sternberg cells of classic Hodgkin disease. *Blood.* 2000;95(10):3020-4.
- [14] Cossman J, Annunziata CM, Barash S, Staudt L, Dillon P, He WW, et al. Reed-Sternberg cell genome expression supports a B-cell lineage. *Blood, The Journal of the American Society of Hematology.* 1999;94(2):411-16.
- [15] Introcaso CE, Kantor J, Porter DL, Junkins-Hopkins JM. Cutaneous Hodgkin's disease. *J Am Acad Dermatol.* 2008;58(2):295-98.

**PARTICULARS OF CONTRIBUTORS:**

1. Professor and Head, Department of Dermatology, Madras Medical College, Chennai, Tamil Nadu, India.
2. Professor, Department of Dermatology, Madras Medical College, Chennai, Tamil Nadu, India.
3. Associate Professor, Department of Dermatology, Madras Medical College, Chennai, Tamil Nadu, India.
4. Senior Assistant Professor, Department of Dermatology, Madras Medical College, Chennai, Tamil Nadu, India.
5. Postgraduate, Department of Dermatology, Madras Medical College, Chennai, Tamil Nadu, India.

**NAME, ADDRESS, E-MAIL ID OF THE CORRESPONDING AUTHOR:**

Dr. Elangovan Supriya,  
Postgraduate, Department of Dermatology, Madras Medical College, Ladies Hostel,  
Parktown, Chennai, Tamil Nadu, India.  
E-mail: supriyaelangovan96@gmail.com

**PLAGIARISM CHECKING METHODS:** [Jain H et al.]

- Plagiarism X-checker: Jun 11, 2022
- Manual Googling: Sep 08, 2022
- iThenticate Software: Sep 10, 2022 (13%)

**ETYMOLOGY:** Author Origin**AUTHOR DECLARATION:**

- Financial or Other Competing Interests: None
- Was informed consent obtained from the subjects involved in the study? Yes
- For any images presented appropriate consent has been obtained from the subjects. Yes

Date of Submission: **Jun 07, 2022**  
Date of Peer Review: **Jul 22, 2022**  
Date of Acceptance: **Sep 12, 2022**  
Date of Publishing: **Nov 01, 2022**