

Aesthetic and Functional Rehabilitation with Prosthetic Approach and Vertical Dimension Occlusion Increase: A Case Report

ÖZLEM ÖZİŞÇİ



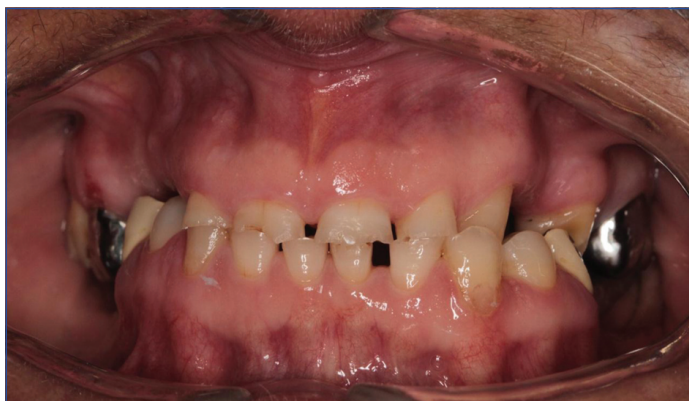ABSTRACT

Prosthetic rehabilitation of severely worn teeth with loss of vertical dimension is difficult due to limited space and the need for complex treatments. To improve aesthetics, maintain anterior tooth relationships, and provide space for the prosthesis, effective treatment alternatives are needed to increase the Occlusal Vertical Dimension (OVD). This will reduce the need for invasive procedures and endodontic treatments. For optimum treatment, accurate measurements of the OVD, interocclusal resting area, and central relationship recordings are needed. The contours of the facial soft tissues should be examined. Before beginning the full mouth rehabilitation, it should be kept in mind that severe abrasion does not always result in the loss of vertical dimension, and it does not necessarily eliminate all defective occlusal interactions. In preventive and restorative dentistry, managing tooth wear and attrition is a fascinating subject. One of the treatment alternatives after a confirmed diagnosis is full mouth reconstruction along with identifying the sources. It is complex and difficult to manage dental attrition. A clinical evaluation of the patient following the cementation of temporary fixed restorations or the use of a diagnostic splint or temporary removable prosthesis can assist in determining the OVD. It is recommended to utilise fixed restorations rather than a removable appliance to increase OVD since patient adaptation is predictable. In the present case (57-year-old female patient), the vertical dimension was restored with an improvement in both function and aesthetics, providing a satisfactory clinical outcome.

Keywords: Bruxism, Full mouth rehabilitation, Occlusal splint, Tooth wear

CASE REPORT

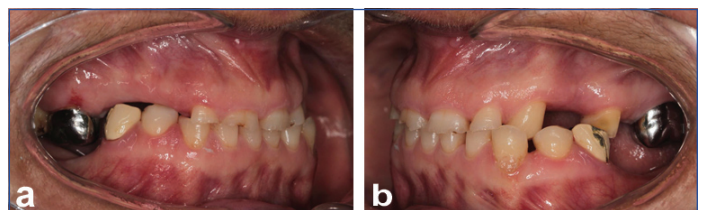
A 57-year-old female patient came with a chief complaint of significantly worn out dentition to the Department of Prosthodontics. Patient reported unaesthetic anterior teeth, chewing difficulty caused by missing teeth and, upper and lower anterior tooth hypersensitivity. The patient was in good general health, non smoker and with no history of medication allergies. A thorough history was obtained and clinical examination was performed to record baseline data. Excessive wear on the teeth, restoration fractures, metal ceramic crowns on teeth 16, 27, 35, 45, and the lack of teeth 18, 15, 14, 13, 24, 26, 28, 36, 37, 38, 46, 47, 48 were noticed during dental examination [Table/Fig-1,2]. The anterior teeth had sharp enamel edges, dentinal craters and attrition wear as a result of the lack of posterior support. The patient gave a history of night grinding of teeth since four years. The patient also provided information about previous prosthodontic treatments from seven years ago.



[Table/Fig-1]: Intraoral frontal view.

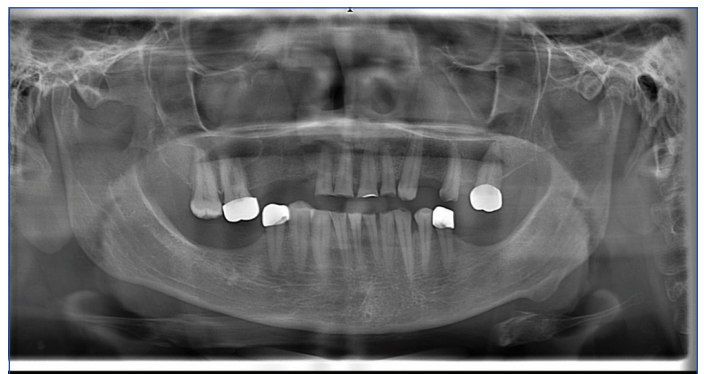
Patient did not use her old Removable Partial Denture (RPD) because it was uncomfortable to wear despite a lack of the mandibular posterior teeth.

The patient with worn out anterior teeth also had a clinically reduced clinical crown height and an edge-to-edge incisor relationship with a reduced overjet and overbite. The lateral view revealed a cross bite in the posterior region [Table/Fig-2a,b]. Excessive dentinal loss was found on the occlusal and incisal surfaces and the attrition had approached the pulp.



[Table/Fig-2]: a) Lateral view on the right side. b) Lateral view on the left side.

A healthy periodontium was found during the periodontal examination, and multiple missing teeth were revealed on a panoramic radiograph, along with the attrition of the most of the teeth [Table/Fig-3].



[Table/Fig-3]: Initial radiographic assessment.

During extraoral examination, it was found that there was a decrease in the height of the lower face and the occlusal vertical dimension was significantly reduced due to the absence of mandibular posterior

teeth. The distance between the two reference points on the nose and chin was measured using a scale while the mandible was in its physiological rest or centric relation position. The patient was then instructed to either occlude at the maximum intercuspal position or to close her mouth in a way so that all the teeth were in contact, indicating Centric Occlusion (CO). The distance between the two reference points was once again measured with a scale while the patient was in the CO position.

The available treatments included full mouth rehabilitation with metal ceramic restoration, reconstructing the mandibular region that was missing teeth with implants or a removable partial denture.

Various treatment alternatives, such as crown lengthening procedures and implant placements, were explained to the patient after an analysis of their intraoral and extraoral conditions. Patient expressed a fear of all surgical procedures while explaining her financial restrictions. The patient did not want any crown lengthening procedure and implant surgery.

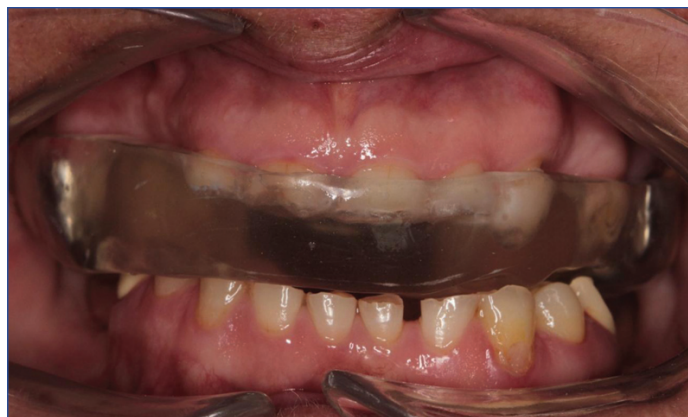Therefore, it was decided to use cast removable partial dentures for the lower posteriors, individual porcelain fused to metal crowns for the lower anteriors, and porcelain fused to metal fixed partial dentures for the upper arch. Patient's approval was obtained before clinical procedures began.

Alginate impressions were taken, and cast models were created to replicate the patient's current occlusion status. Using a facebow record and an interocclusal record made with the aid of a Lucia jig, the patient's casts were mounted on a semi-adjustable articulator (Hanau™ Modular Articulator; Whip Mix Corp., Louisville, United States of America). The patient's gnathologic examination revealed no signs of disease in the Temporomandibular Joint (TMJ) or masticatory muscles. The gnathologic investigations showed drooping commissures and wrinkles around the mouth. Analysing the temporomandibular joint indicated no pain or tenderness. This showed that the patient's stomatognathic system had adapted to the occlusal vertical dimension gradually decreasing. However, with the occlusal vertical dimension, it was difficult to restore the worn and missing teeth. A 6 mm increase in the current vertical dimension of occlusion was planned based on the clinical findings and radiographic analyses.

When treating Temporomandibular joint Disorder (TMD) and restoring an OVD that has been disrupted, a stabilisation splint is a conservative initial line of treatment. An occlusal splint temporarily alters the mandible's occlusal contacts and function. The goal is to maintain centric relation of the mandible through centric relate occlusion against the splint and equal contacts of the posterior teeth. Vertical dimension at rest was also determined. The occlusal vertical dimension was measured and the interocclusal distance was calculated.

An occlusal splint was prepared for canine protection occlusion from hard transparent acrylic to the upper jaw [Table/Fig-4]. The goal of the occlusal prescription of the splint was a removable, mutually protective system. The splint had to be worn continuously for six weeks to evaluate the patient's tolerance for the increase in OVD (at all times other than when eating). The patient was called in for follow-up one week after the initial postinsertion visits since only minor adjustments were required.

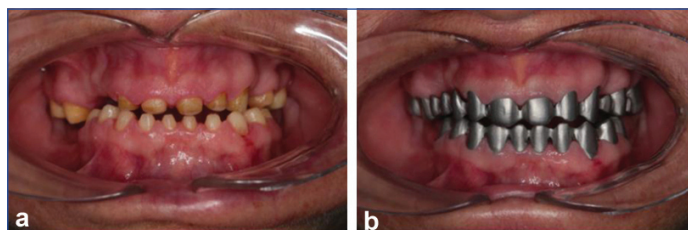
The new VDO was determined by a 6 mm increase in the articulator's incisal guide pin. The actual increase was found 3 mm in the anterior teeth and 2-3 mm in the posterior teeth because the patient's interocclusal rest space was 2-3 mm larger on the premolar area than the usual distance. The interocclusal rest distance of the patient was 2-3 mm larger than the normal distance in the premolar area, which caused the major increase to be seen in the anterior teeth.



[Table/Fig-4]: Frontal view of occlusal splint in the mouth.

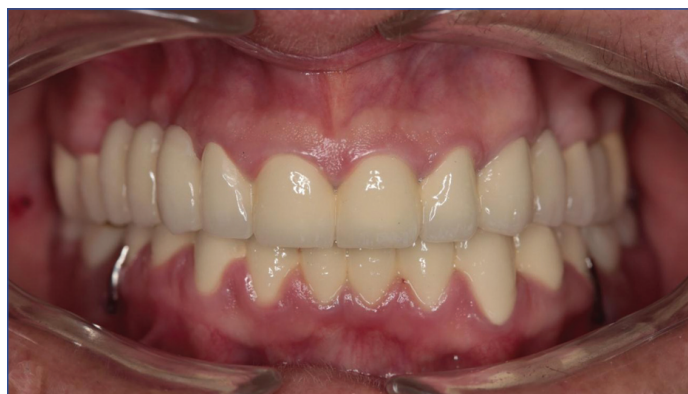The purpose of the splint's design was to provide excursive direction of movement for the anterior teeth while providing bilateral contacts of all posterior teeth in centric relation. With the exception of centric relation, all jaw positions the anterior guidance disoccluded the posterior teeth.

At the end of six weeks the patient reported no muscle or joint pain. The restoration of anterior teeth with a single crown is more aesthetically appealing, but because of the short length of the crowns, there was a risk of decementation. The patient was informed of a variety of treatment options, including full coverage metal, Porcelain fused metal, or zirconia for posterior teeth and full coverage porcelain veneered crown or full coverage zirconia for anterior teeth. Finally after considering patient's choice and financial condition, all the teeth in the mouth were prepared for metal-supported porcelain-fixed bridge prosthesis. The 14-units splinted crown for the maxillary arch (porcelain fused to metal was made for teeth 17, 16, 12, 11, 21, 22, 23, 25, 27) and 10-units splint crown with porcelain fused to metal material for mandibular teeth 35, 34, 33, 32, 31, 41, 42, 43, 44, 45. The final preparation was completed for all of the remaining teeth and definitive impressions with polyvinylsiloxane impression material were made (Elite HD, Zhermack, Italy) [Table/Fig-5].



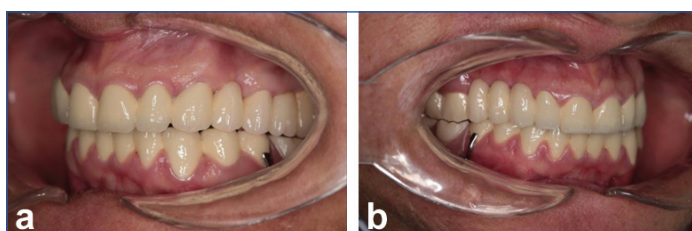
[Table/Fig-5]: Preparation and metal framework trial.

During the trial period, the patient's response to the increased vertical dimension was assessed. The patient showed no symptoms and adapted favourably to the new vertical dimension. Customised anterior guide table was used to construct porcelain fused to metal restorations, which were then cemented [Table/Fig-6].



[Table/Fig-6]: Definitive restoration frontal view.

The mandible was classified as having Kennedy's class I partial edentulous space [1]. The altered cast was made by taking another impression on the posterior alveolar ridge with the individual tray that is attached to the Removable Partial Denture (RPD) framework. The definitive mandibular RPD was fabricated and delivered with minimal occlusal adjustment after the RPD framework was adapted and a wax denture trial was completed. The RPD design consisted of RPI clasps on the mandibular second premolar abutments, and lingual bar major connector. [Table/Fig-7] shows the final restorations in place. The posterior teeth were protected from excursive force and wear by the anterior teeth, whereas the bite force was sustained by the posterior teeth. Daily oral hygiene instructions (proper/daily use of dental aids (such as floss, particular end-tufted, and interdental brushes), and reinforcement of the instructions through demonstrations on models and examinations were administered. Patients who are informed about their oral hygiene status are more likely to practice improved oral hygiene. The patient's acceptance will also be increased by a thorough explanation of the significance of postcementation instructions, proper/daily use of dental aids (such as floss, particular end-tufted, and interdental brushes), and reinforcement of the instructions through demonstrations on models. As a result, the alveolar mucosa will get better and continue to be healthy.



[Table/Fig-7]: a) Post-treatment intraoral photographs left and b) Right side.

DISCUSSION

It is essential to understand that severe wear does not necessarily result in decreased OVD before treating a patient full mouth rehabilitation. Patients with excessive and ongoing occlusal wear can be complicated and difficult to treat, making it one of the challenging issues to deal with [2,3]. Physiologically and with age, all teeth show some wear as a result of functional activity, but occlusal disorders and parafunctional habits like bruxism can increase speed and intensify this process [4,5].

Clinical decision-making is complicated by a lack of data about the long-term outcomes of treatment procedures and materials. The popularity of adhesive procedures, a conservative and reversible treatment option, is increasing [6,7]. However, in this case, the use of composite resin restoration was not a suitable fit for patient rehabilitation. The first structure to suffer the parafunctional load of bruxism is dental enamel. Heavy horizontal forces are applied to the teeth when the mandible shifts from side to side, which is not recommended and increases the risk of damage to the teeth and/or supporting tissues. Additionally, because bruxism occurs in eccentric positions, only a few teeth are subjected to the strong stresses that would normally be applied during functional activity when the jaw is in or close to the centric occlusion position [8-12]. Due to the severity of tooth wear, the parafunction-related loss of tooth tissue is related to dental sensitivity, an excessive reduction in the height of the clinical crown, and possible changes in OVD [13,14].

The remaining tooth structures, which were less than 3 mm and insufficient to provide composite resin adhesion to the dentin surface, were required to support the RPD with full crowns. As a result, the conventional treatment technique was undertaken, which included a trial overlay splint, regular monitoring followed by a definitive prosthesis [15,16].

A natural overjet and overbite were established, the anterior teeth were lengthened, and the anterior tooth relationship was corrected

by increasing the VDO. If VDO is increased without careful consideration, it might cause several problems. The transition period can shorten the overall treatment time depending on the patient's condition and ability to adjust. There is always a risk that the patient might be unable adapt to a new vertical dimension condition if re-establishment of the occlusal vertical dimension (OVD) is suddenly made to the new prosthesis. Therefore, the rehabilitation of OVD should be done gradually through a comprehensive treatment plan. A trial phase of OVD treatment with interim prosthesis is required as part of the rehabilitation treatment. There is no established standard for how long it takes a patient to adapt to this new VD, but literature suggests a period of four weeks as minimum, whereas six weeks were considered in the present case [10,11]. The primary goal of full mouth rehabilitation procedures is to restore and maintain optimal dental health throughout a patient's life [17,18].

The efficacy of the occlusal splint is clinically determined. Patients with occlusal wear on permanent teeth tend to tolerate vertical dimension increase very well, with the increase being within the physiological limits of the orofacial musculature. In cases where the vertical dimensions of the occlusion violate the length of the relaxed contraction of the muscle fibres, especially the masticatory muscles, any treatment involving an increase in the vertical dimensions is certain to fail. The best way to determine if an increase in vertical dimension will be tolerated is by patient examination of acceptable interocclusal distance and speaking space [19].

The method of treatment that was chosen in the present case was based on a simple yet effective rehabilitation procedure for patients needing who needed low-cost rehabilitation with a high probability of long-term success. According to patient's financial condition, the establishment of posterior occlusion, which was temporarily achieved with a provisional removable partial denture but requires safer patient adaptation to be replaced by a definitive posterior prosthesis, starts with a definitive removable partial denture and improves to rehabilitation with osseointegrated implants. However, the outcome over the long-term depends on more than just the patient's hygiene and care.

CONCLUSION(S)

One of the most prevalent treatments for severely worn dentition patients is full mouth reconstruction. The appropriate measurement of the occlusal vertical dimension is an important aspect of the rehabilitation process. In the present case, removable occlusal overlay splint was used to increase the vertical dimension of the occlusion, followed by a final restoration based on an appropriate diagnosis. Patient had no physical symptoms of TMJ like pain and tenderness, and the results were positive as the patient expressed satisfaction with the improvement in facial appearance and aesthetics.

REFERENCES

- [1] Carr AB, McGivney GP, Brown D. McCracken's Removable Partial Prosthodontics. 1973.
- [2] Humel MMC, Takahashi JMFK, Paulillo LAMS, Mesquita MF, Martins LRM. Direct restorative treatment of anterior worn teeth after re-establishment of occlusal vertical dimension: A case report. *Gerodontology*. 2012;29(4):299-307.
- [3] Sato S, Hotta TH, Pedrazzi V. Removable occlusal overlay splint in the management of tooth wear: A clinical report. *The Journal of Prosthetic Dentistry*. 2000;83(4):392-95.
- [4] Gargari M, Ceruso FM, Prete V, Pujia A. Prosthetic-restorative approach for the restoration of tooth wear. Vdo increase, rehabilitation of anatomy and function and aesthetic restoration of anterior teeth. Case report. *Oral Implantol (Rome)*. 2012;5(2-3):70-74.
- [5] Rahman MM, Biswas U, Bank RK, Abid M, Anwar RB. Life changing dentistry with Full Mouth Rehabilitation- A case report. *Update Dent Coll J [Internet]*. 2022;12(1):40-44. Cited on 2022 May 29.
- [6] Ergun G, Yucel AS. Full-mouth rehabilitation of a patient with severe deep bite: A clinical report. *J Prosthodont*. 2014;23(5):406-11.
- [7] Kalra A, Sandhu HS, Sahoo NK, Nandi AK, Kalra S. Full-mouth rehabilitation using twin-stage technique. *Int J Oral Health Sci*. 2019;9(1):40-44.
- [8] Fishman LS. Dental and skeletal relationships to attritional occlusion. *Angle Orthod*. 1976;46(1):51-63.
- [9] Varrela J. Dimensional variation of craniofacial structures in relation to changing masticatory-functional demands. *Eur J Orthod*. 1992;14(1):31-36.

- [10] Bachhav VC, Aras MA. Altering occlusal vertical dimension in functional and esthetic rehabilitation of severely worn dentition. *J Oral Health Res.* 2010;1(1):02-08.
- [11] Reddy SV, Kumar MP, Sravanthi D, Mohsin AH, Anuhya V. Bruxism: A literature review. *J Int Oral Health.* 2014;6(6):105-09.
- [12] Alfadda SA. A conservative and reversible approach for restoring worn teeth: A clinical report. *J Prosthet Dent.* 2014;112(1):18-21.
- [13] Widmalm SE, Lee YS, McKay DC. Clinical use of qualitative electromyography in the evaluation of jaw muscle function: A practitioner's guide. *Cranio.* 2007;25(1):63-73.
- [14] Singh R, Dua P, Prakash P, Bhandari SK. Occlusal splint: A vital adjunct in full mouth rehabilitation for cases of severely worn dentition. *International Journal of Contemporary Medical Research.* 2019;6(11):K20-K24.
- [15] Song MY, Park JM, Park EJ. Full mouth rehabilitation of the patient with severely worn dentition: A case report. *J Adv Prosthodont.* 2010;2(3):106-110.
- [16] Johansson A, Johansson AK, Omar R, Carlsson GE. Rehabilitation of the worn dentition. *J Oral Rehabil.* 2008;35(7):548-66.
- [17] Chacona RL. Enamel loss and occlusal vertical dimension. Causes and considerations for treatment. *Dent Today.* 2003;22(4):92-97.
- [18] Zinzala B, Javiya P, Sethuraman R, Tiwari A, Patel R, Jain J. Functional and esthetic full mouth rehabilitation of a patient with severely worn dentition: A clinical report. *Int J Oral Health Med Res.* 2017;4(5):42-45.
- [19] Niemann W. The bicuspid block MORA convertible appliance. *Funct Orthod.* 2004;21(1):12-26.

PARTICULARS OF CONTRIBUTORS:

1. Lecturer, Department of Prosthodontics, Başkent University, Faculty of Dentistry, Ankara, Cankaya, Turkey.

NAME, ADDRESS, E-MAIL ID OF THE CORRESPONDING AUTHOR:

Özlem Özışçi,
Başkent Üniversitesi Diş Hekimliği Fakültesi 2.Kat Protez Kliniği 82. Sokak No:26
06490 Bahçelievler, Ankara, Cankaya, Turkey.
E-mail: oslemozisci@gmail.com

PLAGIARISM CHECKING METHODS: [\[Jain H et al.\]](#)

- Plagiarism X-checker: Jun 01, 2022
- Manual Googling: Sep 12, 2022
- iThenticate Software: Sep 16, 2022 (7%)

ETYMOLOGY: Author Origin**AUTHOR DECLARATION:**

- Financial or Other Competing Interests: None
- Was informed consent obtained from the subjects involved in the study? Yes
- For any images presented appropriate consent has been obtained from the subjects. Yes

Date of Submission: **May 29, 2022**Date of Peer Review: **Jul 19, 2022**Date of Acceptance: **Sep 19, 2022**Date of Publishing: **Nov 01, 2022**