

Obstructed Left Paraduodenal Hernia with Spontaneous Reduction Demonstrated on Computed Tomography: A Case Report

VARSHA P RANGANKAR¹, KRISHNARJUN MURALINATH², PARAG V PATIL³, SAMEEH UZ ZAMAN⁴

(CC) BY-NC-ND

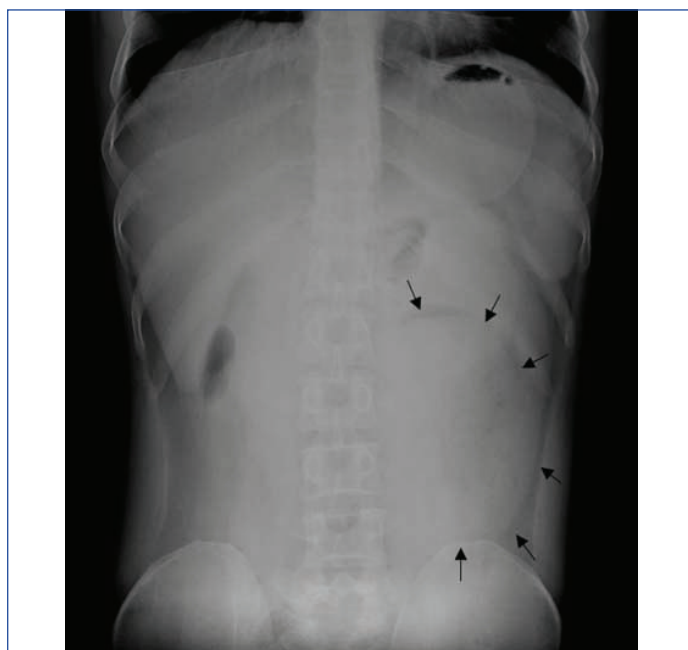
ABSTRACT

Paraduodenal hernias (PDH) are the most frequently occurring internal hernia, caused due to non fusion between inferior mesentery and parietal peritoneum. The herniation of the bowel through the fossa of Landzert results in the left paraduodenal hernia which constitutes 75% of PDH. A case of a 34-year-old male with obstructed left PDH and a spontaneous reduction is demonstrated on Computed Tomography (CT). The patient had a cluster of jejunal loops forming a sac-like mass in the left anterior pararenal space, with surrounding mass effect with twisting and stretching of the mesenteric vessels at the hernia orifice, which showed a spontaneous reduction on subsequent contrast-enhanced and delayed CT studies. Despite the imaging evidence of spontaneous reduction of left PDH in the present case, surgery remains the mainstay in terms of management for left paraduodenal hernia.

Keywords: Converging, Inferior mesenteric vein, Obstruction, Sac, Transient

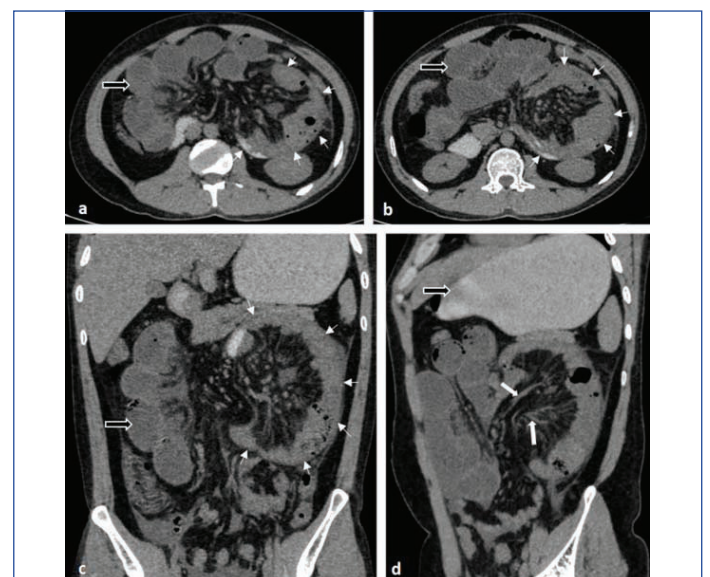
CASE REPORT

A 34-year-old male presented with severe generalised abdominal pain that lasted two days, associated with decreased appetite, vomiting, and constipation. The patient also had a history of intermittent belching and mild abdominal pain localised over the left lumbar and iliac fossa regions for one year. He had no known comorbidities or previous surgical history. On palpatory examination, the patient had tenderness over the left iliolumbar region. The laboratory investigations, including renal and liver function tests, serum amylase, and lipase levels, were within normal limits. A plain anteroposterior radiograph of the abdomen (erect position), that was taken on admission showed a fairly well-defined, round to oval radiopacity with radiolucent margins in the left paraumbilical and lumbar regions, overlying the ipsilateral psoas shadow [Table/Fig-1]. Ultrasonography of the abdomen and pelvis showed dilated oedematous fluid-filled aperistaltic small bowel loops suggestive of intestinal obstruction.



[Table/Fig-1]: Plain anteroposterior radiograph of abdomen in erect position showing a fairly well-defined, round to oval radiopacity with radiolucent margins in the left paraumbilical and lumbar regions (black arrows).

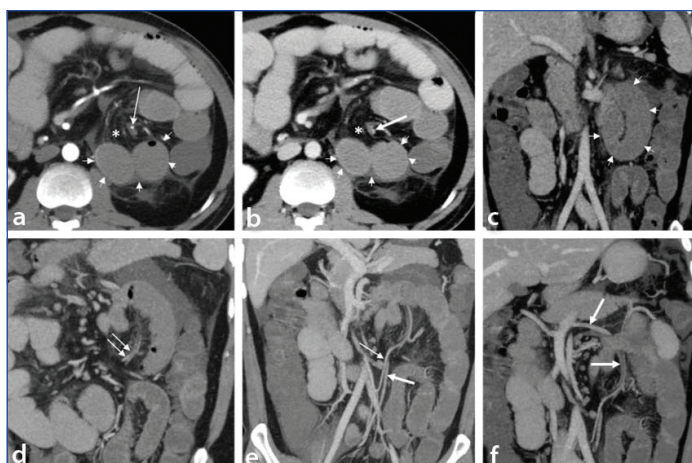
Computed Tomography (CT) examination of the abdomen with oral contrast [Table/Fig-2] showed a sac-like mass containing clustered jejunal loops in the left anterior pararenal space, leading to the displacement of adjacent bowel, and the distal part of the pancreas. The mesenteric vessels were stretched, twisted, and converged along the medial aspect of this sac (hernia orifice) with surrounding mesenteric fat stranding. Significant dilatation of jejunal loops was noted, proximal to the hernia sac. The stomach was overdistended and opacified with the oral contrast. However, the oral contrast did not opacify the dilated jejunal loops. The small intestinal loops distal to the sac, and the large bowel were not dilated. The diagnosis of left paraduodenal internal hernia with small intestinal obstruction was made based on imaging findings.



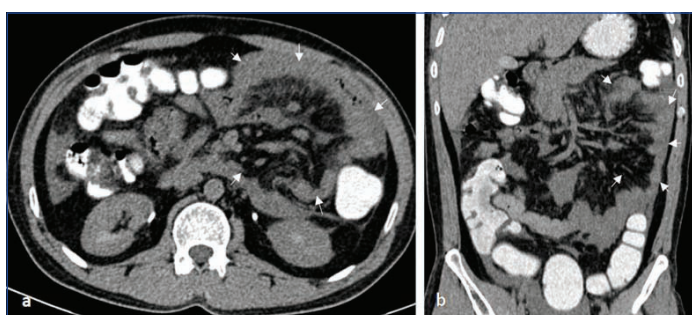
[Table/Fig-2]: a-c) Axial and coronal reformatted CT images showing left paraduodenal hernia with a cluster of jejunal loops in the hernia sac in the left anterior pararenal space (small white arrows). The mesenteric vessels are seen stretched, twisted, and seen converging along the medial aspect of the sac representing the hernia orifice (d, thick white arrows). Significant dilatation of the jejunal loops proximal to the sac with over-distended oral contrast opacified stomach (a-d, black arrows with white outline).

After the initial CT study, the patient had resolution of the symptoms with reduced abdominal pain and per rectal passage of air and faeces. The subsequent CT of the abdomen postadministration of intravenous and oral contrast [Table/Fig-3] was performed after

five hours to evaluate the vascular structures and status of the bowel. There was contrast opacification of the stomach, duodenum, jejunal and proximal ileal loops with oral contrast with no opacification of the distal ileal loops. The jejunal loops remained dilated. Mesenteric fat stranding continued to be seen with twisting of mesenteric vessels and convergence of vessels on the left side. However, there was significant reduction in the size of the hernia sac which contained reduced number of jejunal loops, compared to the previous study [Table/Fig-3a-c]. Ascending left colic artery and inferior mesenteric vein were displaced laterally and seen anterolateral to the hernia orifice [Table/Fig-3d-f]. The inferior mesenteric vein showed anatomical variation and was draining into the superior mesenteric vein just proximal to the portal confluence [Table/Fig-3f]. The CT abdomen with rectal contrast was performed after five hours in view of further improvement in the patient's symptoms, which revealed complete resolution of the left paraduodenal hernia and the small bowel dilatation [Table/Fig-4]. The patient was recommended surgery for abdominal exploration and closure of the hernial orifice. However, the patient did not consent to the surgery after his symptoms were relieved. He was discharged and kept on regular follow-up. The patient was asymptomatic and did not report any relapse of a similar episode on the subsequent periodic follow-ups over the past two and half years and has been advised regular monitoring for the possibility of relapse.



[Table/Fig-3]: a-c) Contrast-enhanced CT of the abdomen after 5 hours showing significant reduction in the size of the hernia sac (small white arrows) with left ascending colic artery (a, long thin arrow) and inferior mesenteric vein (b, long thick arrow) seen anterior to the hernial sac and anterolateral to the hernia orifice (a-b, marked by an asterisk). d-f) Oblique coronal reformatted CT images showing the left ascending colic artery (e, thin arrow) and inferior mesenteric vein (f, thick arrow) in anterior relation to the hernia sac with lateral displacement. The inferior mesenteric vein had variant anatomy in this patient and was draining in the superior mesenteric vein just proximal to the portal confluence (f, thick arrows). Dilatation of jejunal bowel loops is also seen.



[Table/Fig-4]: a,b) CT abdomen with rectal contrast reveals reduction in the small bowel dilatation with complete resolution of the left paraduodenal hernia as highlighted by white arrows in the location of the previously seen hernia sac.

DISCUSSION

Internal hernias are rare protrusions of abdominal viscera, most notably the small intestine, through congenital or acquired apertures in the mesentery or peritoneum within the abdominopelvic cavity [1,2]. Congenital hernial orifices may be normally present foramina, fossae, or recesses or may result from congenital defects in mesenteric and

peritoneal fusion and bowel rotation. Paraduodenal hernias (PDH) constitute 53% of internal hernia cases, out of which 75% are left PDHs [2]. These may be potentially life-threatening due to bowel entanglement in these defects, with acute intestinal obstruction, strangulation, ischaemia, and necrosis of the herniated bowel. Reducible internal hernias can be asymptomatic, while some patients can also have chronic recurrent mild digestive complaints, abdominal pain, and recurring incidents of intestinal obstruction, posing a challenge to diagnose preoperatively [1-3]. PDH can also present with chronic recurrent symptoms and show spontaneous reduction as reported in the literature [1-5]. However, only two reported cases of left PDH with the spontaneous regression documented on CT were found [4,5].

Paraduodenal hernias (PDH) are hypothesised to be peritoneal anomalies caused by non fusion of mesentery with the parietal peritoneum and midgut non rotation with small intestine entrapment under the developing colon [1,5]. Left PDH develops through the congenital peritoneal fossa of Landzert which is normally present in about 2% of the population [1,2]. The ascending left colic artery and the Inferior Mesenteric Vein (IMV) lift a fold of the peritoneum leading to the formation of Landzert's fossa [1,2]. These vessels run along the lateral aspect of Landzert's fossa, which is located behind and to the left side of the ascending segment of the duodenum. The small intestine can herniate through this fossa and become entrapped within the left paraduodenal hernia sac. Left PDH can be asymptomatic or present with nausea, vomiting, recurrent, often postprandial, epigastric or colicky periumbilical pain. The symptoms of recurrent intestinal obstruction with mild distension, and acute cramp-like or chronic intermittent pain are also seen in reducible hernias [2].

Conventional radiographic imaging usually shows dilated bowel loops with air-fluid levels with or without soft tissue density due to hernia sac in obstructed PDH. On ultrasonography, the hernia sac with bowel loops within and surrounding membrane may be visualised [6]. Multidetector CT is the favoured imaging modality in the cases of PDH presenting as acute abdomen with suspected small bowel obstruction and strangulation with risk of bowel ischaemia and perforation. The presence of a cluster of dilated small bowel loops with a sac-like mass in the left anterior pararenal space is one of the key CT features of left PDH [1-5,7,8]. The hernia sac can cause a mass effect by displacing the adjacent viscus, mainly the adjacent duodenum, stomach, pancreas and bowel. The mesenteric vessels supplying these herniated small bowel loops are stretched, enlarged and seen converging at their point of entry into the hernia sac [1-5]. The anterior and medial borders of the left PDH contain the inferior mesenteric vein and ascending left colic artery which can be displaced laterally [2]. Inferior mesenteric vein situated anterior to the hernia orifice provides a good landmark in assessing left PDH [2]. Strangulation and incarceration can occur in upto 64% of obstructed PDH with high reported mortality without accurate perioperative diagnosis [9].

The PDHs, especially the smaller ones, may be transient and are known to reduce spontaneously [1-5]. However, the demonstration of spontaneous reduction on imaging has rarely been reported in the literature. Meyers MA, reported it on barium studies in 1970 [10]. Only two case reports were found in the literature search demonstrating transient nature and spontaneous regression of left PDH on CT [4,5]. Ovali GY et al., reported the spontaneous regression in repeat CT after five days [4], while Maheshwari S et al., reported it in follow-up CT after 11 months [5]. In the present case, the spontaneous reduction that was demonstrated on CT occurred overnight within 16 hours from the time of emergency admission of the patient.

Laparoscopic or open abdominal surgery is the only definitive treatment for left PDH. Timely surgical intervention is essential in the acute presentation of obstructed left PDH which is associated with a high incidence of complications and mortality. The obstructed intestinal loops are reduced and released during the surgery,

followed by repair of the hernia orifice defect [7,8,11]. The hernia orifice can also be widened, making it a part of the larger peritoneal cavity to avoid future bowel incarceration [7,11]. The intraoperative identification of PDH and hernia orifice may be challenging if there is a spontaneous reduction of the left PDH before or during the surgery as was seen in the index case [7,12]. In the present case, the patient was not operated on due to a lack of consent on his part, as well as the possibility of difficulty in intraoperative identification of the hernia orifice due to complete spontaneous reduction of the PDH. However, the patient is being followed-up on a regular basis and has been advised to be monitored closely for the possibility of relapse.

CONCLUSION(S)

Paraduodenal hernias can be difficult to diagnose due to vague presentation, overlapping symptoms, and transient nature. For best diagnostic yield, they should be imaged with contrast-enhanced CT during the presentation of symptoms. Spontaneous reduction in obstructed left PDH is rarely demonstrated on imaging. Despite the index case showing rare imaging evidence of spontaneous reduction of left PDH, surgery remains the definitive treatment.

REFERENCES

- [1] Takeyama N, Gokan T, Ohgiya Y, Satoh S, Hashizume T, Hataya K, et al. CT of internal hernias. *Radiographics*. 2005;25(4):997-15. Doi: 10.1148/rg.254045035. PMID: 16009820.
- [2] Martin LC, Merkle EM, Thompson WM. Review of internal hernias: Radiographic and clinical findings. *AJR Am J Roentgenol*. 2006;186(3):703-17. Doi: 10.2214/AJR.05.0644. PMID: 16498098.
- [3] Chiang CL, Du WN, Huang SM, Wang CY, Chiang RA. Left paraduodenal hernia: An un-common cause of acute abdomen. *International Journal of Gerontology*. 2011;5(3):171-72. <https://doi.org/10.1016/j.ijge.2011.09.029>.
- [4] Ovali GY, Orguc S, Unlu M, Pabuscu Y. Transient left paraduodenal hernia. *Comput Med Im-aging Graph*. 2005;29(6):459-61. Doi: 10.1016/j.compmedimag.2004.09.019. PMID: 15994059.
- [5] Maheshwari S, Khadka A, Bhattacharjee S, Rajesh U, Maria V. Case report of left paraduodenal hernia with a spontaneous reduction on follow-up: The rare demonstration on computed tomography. *Egypt J Radiol Nucl Med*. 2020;51(224):01-04. <https://doi.org/10.1186/s43055-020-00338-4>.
- [6] Wachsberg RH, Helinek TG, Merton DA. Internal abdominal hernia: Diagnosis with ultrasonography. *Can Assoc Radiol J*. 1994;45(3):223-24. PMID: 8193972.
- [7] Downes R, Cawich SO. A case of a paraduodenal hernia. *Int J Surg Case Rep*. 2010;1(2):19-21. Doi: 10.1016/j.ijscr.2010.06.003. Epub 2010 Oct 8. PMID: 22096667; PMCID: PMC3199615.
- [8] Doishita S, Takeshita T, Uchima Y, Kawasaki M, Shimono T, Yamashita A, et al. Internal hernias in the era of multidetector CT: Correlation of imaging and surgical findings. *Radiographics*. 2016;36(1):88-06. <https://doi.org/10.1148/rg.2016150113>.
- [9] Wong Y, Lath N, Eng A, Navasivagum V. Clinical features of paraduodenal hernia. *Proc Sin-gap Healthcare* 2018;27(2):139-142. <https://doi.org/10.1177/2010105817744799>.
- [10] Meyers MA. Paraduodenal hernias. *Radiologic and arteriographic diagnosis*. *Radiology*. 1970;95(1):29-37. Doi: 10.1148/95.1.29. PMID: 5417044.
- [11] Manojlović D, Čekić N, Palinkaš M. Left paraduodenal hernia- A diagnostic challenge: Case report. *Int J Surg Case Rep*. 2021;85:106138. Doi: 10.1016/j.ijscr.2021.106138. Epub 2021 Jun 29. PMID: 34256232; PMCID: PMC8369286.
- [12] Shetty P, Selvaraju K, Singh S. A left paraduodenal hernia causing recurrent small bowel obstruction: A case report. *Webmed Central Gastrointestinal Surgery*. 2010;1(12):WMC001308.

PARTICULARS OF CONTRIBUTORS:

1. Professor, Department of Radioadiagnosis, Dr. D. Y. Patil Medical College, Hospital and Research Centre, Pune, Maharashtra, India.
2. Postgraduate Resident, Department of Radioadiagnosis, Dr. D. Y. Patil Medical College, Hospital and Research Centre, Pune, Maharashtra, India.
3. Professor, Department of Radioadiagnosis, Dr. D. Y. Patil Medical College, Hospital and Research Centre, Pune, Maharashtra, India.
4. Postgraduate Resident, Department of Radioadiagnosis, Dr. D. Y. Patil Medical College, Hospital and Research Centre, Pune, Maharashtra, India.

NAME, ADDRESS, E-MAIL ID OF THE CORRESPONDING AUTHOR:

Dr. Varsha P Rangankar,
Professor, Department of Radioadiagnosis, Dr. D. Y. Patil Medical College, Hospital and Research Centre, Pune-411018, Maharashtra, India.
E-mail: varsharangankar@gmail.com

PLAGIARISM CHECKING METHODS: [Jain H et al.]

- Plagiarism X-checker: Jul 06, 2022
- Manual Googling: Sep 13, 2022
- iThenticate Software: Sep 22, 2022 (12%)

ETYMOLOGY: Author Origin

AUTHOR DECLARATION:

- Financial or Other Competing Interests: None
- Was informed consent obtained from the subjects involved in the study? Yes
- For any images presented appropriate consent has been obtained from the subjects. Yes

Date of Submission: Jul 05, 2022
Date of Peer Review: Aug 28, 2022
Date of Acceptance: Sep 23, 2022
Date of Publishing: Jan 01, 2023