

Multidisciplinary Management in a Patient with Hemifacial Microsomia and Microglossia

SANTOSH KUMAR¹, PRIYANKA JAYASWAL²

(CC) BY-NC-ND

ABSTRACT

Hemifacial Microsomia (HFM) is the second most common congenital craniofacial anomaly following cleft lip and palate. On contrary, microglossia is a very rare congenital anomaly. To the best of authors' knowledge, HFM associated with microglossia has not been reported in the literature. Hereby, the authors present a case report of a 13-year-old girl, who presented with features of hemifacial microsomia, blindness, microglossia, hypodontia, bilateral transposition between upper first premolar and canine, anterior crowding and deep bite. Patient's treatment was started with fixed orthodontic appliance and arches were aligned by maintaining the transposed position of the teeth. After completion of orthodontic treatment, maxillary right and left first premolars were contoured into lateral incisor and canine, respectively, to have satisfactory functional and aesthetic outcome.

Keywords: Aesthetic outcome, Orthodontic treatment, Transposition

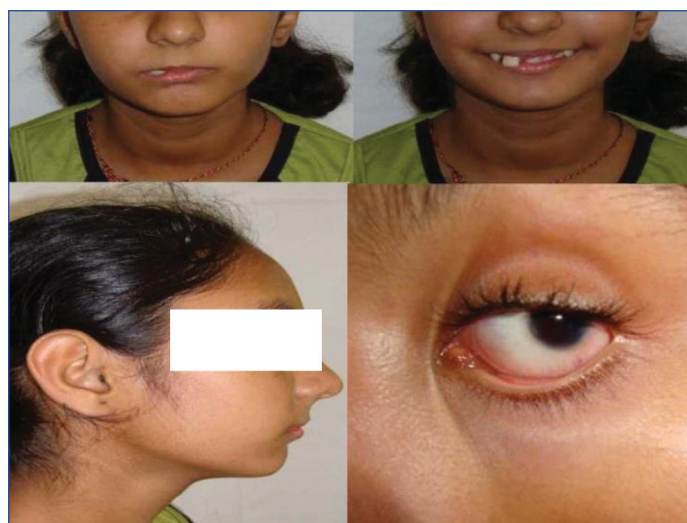CASE REPORT

A 13-year-old girl patient was reported with chief complaint of unaesthetic appearance of her teeth. Patient gave history of loss of vision in left eye since birth. There was no relevant family history and her mother had been well during pregnancy and delivery.

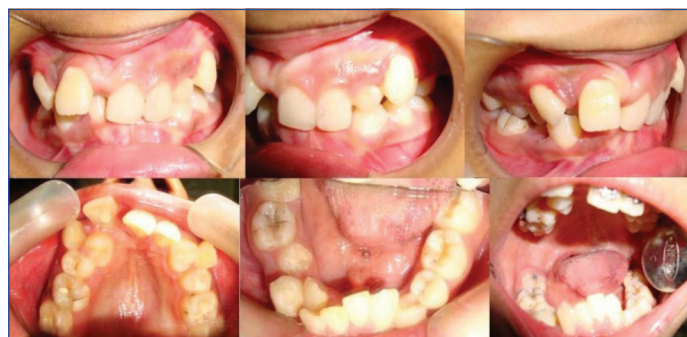Extraoral clinical evaluation showed under development of left side of the face, mandibular retrusion, facial asymmetry with chin deviated to her left side. The corner of the mouth on the left side was posteriorly placed compared to the other side leading to macrostomia. Clinical examination showed a convex facial profile and competent lips. Clinical examination of the left eye revealed microphthalmia, inferior iris coloboma and lipoeperimoids. Intraoral examination revealed microglossia, with an evident reduction in tongue dimensions and posterior tongue positioning. Right maxillary and left mandibular lateral incisors were found to be missing. The upper dental midline was shifted to right and lower dental midline was shifted to left with respect to the facial midline [Table/Fig-1,2]. The complete transposition of teeth between upper first premolar and the canine was noted bilaterally, which were also confirmed on occlusal and intraoral radiograph [Table/Fig-3]. There was 100% anterior deep bite and overjet was 2 mm. Crowding was noted in the upper and lower labial segment. Both upper and lower dental arches were collapsed and most of the teeth were carious. Patient's dental malocclusion was diagnosed as Angle's Class II subdivision malocclusion, with deep bite and oligodontia.

Cephalometric analysis indicated a Class II skeletal pattern due to a retrognathic mandible, retroclined mandibular and maxillary incisors [Table/Fig-4]. Orthopantomogram revealed slight underdevelopment of the left side ramus with normal appearing condyle [Table/Fig-3]. The patient's haemogram and serum biochemistry investigations were within normal limits. Audiological evaluation revealed no hearing deficit. Based on clinical and radiographic findings, a diagnosis of hemifacial microsomia along with microglossia was established. The treatment objectives included restoration of decayed teeth, levelling and alignment of teeth to restore the oral function and aesthetics and maintenance of oral hygiene measures during and after the orthodontic treatment.

Considering the patients increased susceptibility of caries and compromised oral hygiene, it was decided to accomplish the treatment in two phases. First phase included the restoration of all the carious teeth and reinforcement of oral hygiene measures.



[Table/Fig-1]: Pretreatment extraoral photographs showing under development of left side of the face, mandibular retrusion, facial asymmetry, loss of vision in left eye with microphthalmia, inferior iris coloboma and lipoeperimoids.

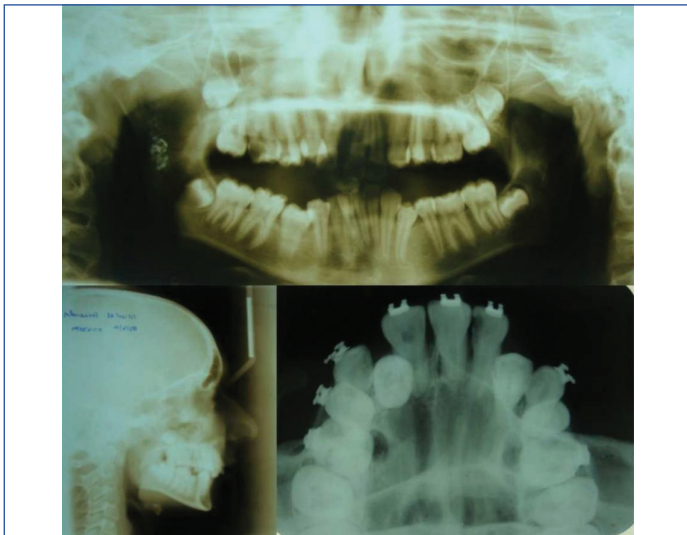


[Table/Fig-2]: Pretreatment intraoral photographs, showing anterior deep bite, missing upper right and lower left lateral incisor and transposition between upper canine and first premolar bilaterally and microglossia.

Second phase included correction of the malocclusion using a fixed orthodontic appliance without extraction.

Treatment Progress

All the caries were restored during the first phase of the treatment. Root canal treatment was done in relation to upper right central



[Table/Fig-3]: Pretreatment radiographs showing skeletal class II pattern, mandibular retrognathia and complete transposition between upper canine and first premolar bilaterally.

Parameters	Norms	Pretreatment	Post-treatment
SNA	84.1°±3.2°	79	79
SNB	81.9°±3.5°	74	75
ANB	2.3°±2.2°	5	4
FMA	29.4°±5.4°	27	28
IMPA	98.0°±5.6°	86°	95°
U1-NA	27.4°±6.2°	18°	26°
U1-NA	7.5 mm±2.6	2 mm	5 mm

[Table/Fig-4]: Cephalometric values showing improvement in incisor inclination. SNA: Sella-nasion to A point angle; SNB: Sella-nasion to B point angle; ANB: A point to B point angle; FMA: Frankfort mandibular plane angle; IMPA: Angle between long axis of lower incisor and mandibular plane angle; U1-NA: Angle between upper incisor to NA line; U1-NA: Distance from upper incisor to NA line

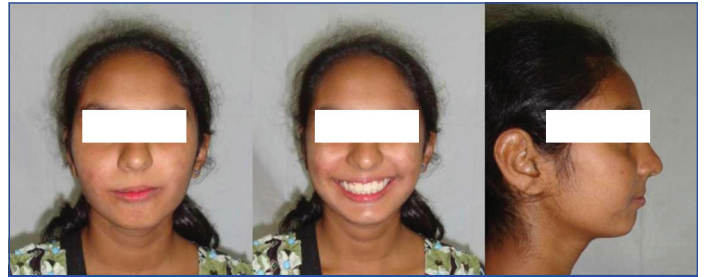incisor and patient was put on meticulous oral hygiene measures for next three months. After an overall consideration of the cephalometric and dental cast analyses, a non extraction treatment plan was decided, to accomplish the second stage of the treatment. Upper and lower dental arches were bonded with a 0.022"×0.028" preadjusted edgewise appliance (MBT) and levelling and alignment was initiated with 0.012" NiTi wire and working upto 0.019"×0.025" stainless steel wire.

As both the dental arches were collapsed and right maxillary and left mandibular lateral incisors were found to be missing, it was decided to level and align the arch-by-arch expansion. Expanded arch wires were used to expand the upper and lower dental arches. The levelling and alignment of maxillary arch was accomplished in 14 months. In both upper quadrants, canine and first premolar were aligned by maintaining their transposed position. During the active orthodontic treatment, the patient was motivated and periodontally maintained by the dental hygienist on a monthly basis. After completion of orthodontic treatment at 18 months, appliances were removed and maxillary right and left first premolars were contoured into lateral incisor and canine respectively. Further, occlusal interferences were checked and eliminated during lateral excursions by selective grinding. Multistranded stainless steel lingual retainers were bonded in both arches. In addition, upper and lower Hawley's appliance were also given to the patient for retention purpose and was advised to wear at night time for one year. The total treatment time including retention period was two year and six months.

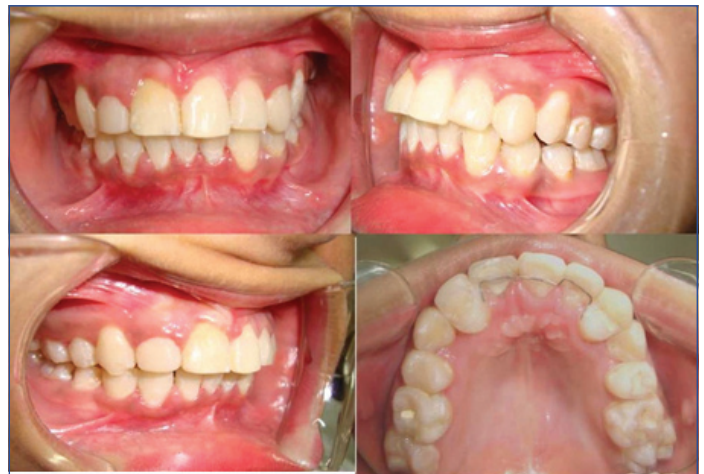Treatment Results

Immediate post-treatment records after 18 months of orthodontic treatment duration, showed balanced facial profile, simulated class I canine relationship bilaterally with ideal overjet and overbite. Molar relationship was class I on the left side and Class II on the right side.

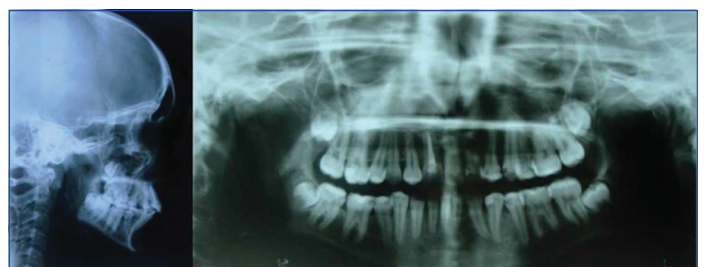The crowding of both dental arches and the deviation of the maxillary dental midline were corrected, and the results are shown in the post-treatment stage [Table/Fig-5,6]. The post-treatment panoramic radiograph showed parallel roots with no signs of root resorption [Table/Fig-7]. Cephalometric superimpositions on the anterior cranial base (SN plane) confirmed the labial movement of the incisors and a slight inferior movement of the mandible. Molar eruption was within a normal range [Table/Fig-8].



[Table/Fig-5]: Post-treatment extraoral photograph showing balanced facial profile.



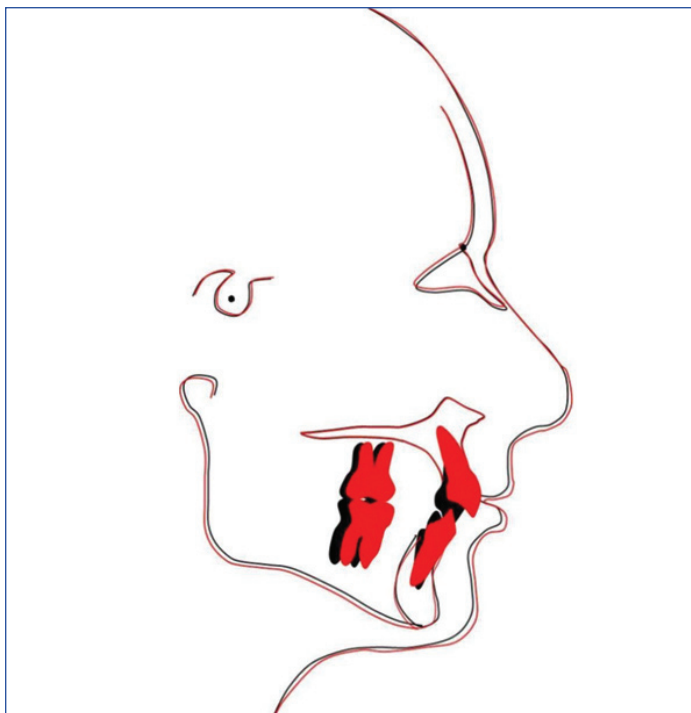
[Table/Fig-6]: Post-treatment intraoral photograph showing well-aligned arches with ideal overjet and overbite.



[Table/Fig-7]: Post-treatment radiographs showing ideal angulation and inclination of the teeth.

DISCUSSION

Hemifacial Microsomia (HFM) is believed to be the second most common congenital craniofacial anomaly following cleft lip and palate with reported incidences of 1 per 3,500 live births [1]. HFM is a complex anomaly involving both skeletal and soft tissues, with distortions in all three planes of space. Treatment requires an interdisciplinary team care integrated plan, that is best provided by a multidisciplinary team to achieve the best outcomes, both functionally and aesthetically [2,3]. Blindness and microglossia associated with hemifacial microsomia have been reported on rare



[Table/Fig-8]: Superimposition on SN plane showing labial movement of incisors.

occasions [4,5]. In the present case, patient has microglossia and loss of vision in the left eye since birth. The lack of normal tongue musculature as seen in hypoglossia, affects the development of jaws and produces malocclusion of teeth, as evident in the case reported here.

In the present case, complete transposition between the upper canine and first premolar were noted bilaterally. Tooth transposition is an anomaly of eruption where two adjacent teeth interchange their position in the same quadrant. This anomaly is frequently associated with maxillary canine and first premolar [6,7]. Although the aetiology of transposition may be multifactorial, two theories are widely accepted. [8]. One is transposition of the analogue during odontogenesis and migration of the tooth from the normal path of eruption. On the other hand, concurrence of other congenital dental anomalies indicate towards a genetic influences.

The treatment of tooth transposition always imposes a significant challenge to the clinician [9,10]. Complete transposition of canine and first premolar, are managed by orthodontic alignment maintaining their interposed positions. Later the occlusal surfaces of these teeth are modified using restorations, to achieve canine-guided or group function occlusion [11-13]. In the case reported here, the complete transposition of teeth between upper first premolar and the canine was noted bilaterally. The right maxillary lateral incisor was also missing. Therefore, after completion of orthodontic treatment, maxillary right and left first premolars were contoured into lateral incisor and canine, respectively.

In a clinical situation, where a maxillary lateral incisor is missing along with canine-premolar transposition, first premolar may be substituted for the missing lateral incisor to avoid prosthetic restoration and to achieve canine guidance occlusion [12]. The long-term stability has been reported by Parker WS, in such cases [14]. In the case discussed here, the mesiodistal dimensions of right maxillary first premolar and left maxillary lateral incisor, were comparable which helped to achieve a class I canine relation, bilaterally. The patient was able to appreciate the desired aesthetic outcome, which was achieved by orthodontic alignment followed by recontouring of transposed tooth. As orthodontic treatment resulted in expansion of the upper and lower dental arches and patient had microglossia, a permanent retention was planned with a fixed lingual retainer coupled with removable Hawley's retainer.

CONCLUSION(S)

Hemifacial Microsomia associated with microglossia is a very rare developmental anomaly, which produces significant orofacial distortions on the affected side. Treatment requires an early diagnosis and integrated plan, that is best provided by a multidisciplinary team to achieve the best outcomes, both functionally and aesthetically. Understanding of rare dental anomalies, is crucial for better multidisciplinary management of such cases, in the future.

REFERENCES

- [1] Paul MA, Opyrchal J, Knakiewicz M, Jaremków P, Bajtek J, Chrapusta A, et al. Hemifacial microsomia review: Recent advancements in understanding the Disease. *J Craniofac Surg.* 2020;31(8):2123-27.
- [2] Allam KA. Hemifacial microsomia: Clinical features and associated anomalies. *J Ranoiac Surg.* 2021;32(4):1483-86.
- [3] Guo R, Chang S, Wang B, Zhang Q. Ipsilateral hemifacial microsomia with dextrocardia and pulmonary hypoplasia: A case report. *World J Clin Cases.* 2022;10(9):2948-53.
- [4] Grippaudo FR, Kennedy DC. Oromandibular limb hypogenesis syndrome: A case of aglossia with an intra oral band. *Br J Plast Surg.* 1998;51(6):480-83.
- [5] Bagnulo MA, Ferreria SL, Sanchez Z, Cangialosi TJ. Hypoglossia-hypodactylia type IA: A case report. *Columbia Dent Rev.* 1999;4;11-14.
- [6] Correa MS, Correa FNE, de Freitas KMS, de Freitas MR, Garib DG, Janson G. Two-phase orthodontic treatment of two different types of tooth transposition in the same patient. *J Orthod.* 2021;48(4):426-34.
- [7] Liaw J, Lin J, Huang G. The applications of TADs in canine transpositions. *Semin Orthod.* 2018;24 (1):155-90.
- [8] Pedalino A, Matias M, Gaziri D, Vieira B, Alves L, Ursi W, et al. Treatment of maxillary canine transposition. *Angle Orthod.* 2020;90(6):873-80.
- [9] Jain S, Debbarma S. Patterns and prevalence of canine anomalies in orthodontic patients. *Med Pharm Rep.* 2019;92(1):72-78.
- [10] Finkelstein T, Shapira Y, Pavlidi AM, Davidovitch M, Blumer S, Schonberger S, et al. Canine transposition-prevalence, distribution and treatment considerations among orthodontic patients. *J Clin Pediatr Dent.* 2020;44(4):268-73.
- [11] Nyakale MD. Orthodontic treatment of bilateral transposition of maxillary canines and lateral incisors. *Case Rep Dent.* 2022;2022:8094008.
- [12] Souza RM, Oliveira HT, Farret MM. Orthodontic treatment of unilateral cleft lip and palate associated with maxillary canine/premolar transposition: Case report. *Dental Press J Orthod.* 2020;25(3):54-64.
- [13] Lorente C, Lorente P, Perez-Vela M, Esquinas C, Lorente T. Orthodontic management of a complete and an incomplete maxillary canine-first premolar transposition. *Angle Orthod.* 2020;90(3):457-66.
- [14] Parker WS. Transposed premolars, canines, and lateral incisors. *Am J Orthod Dentofac Orthop.* 1990;97(5):431-48.

PARTICULARS OF CONTRIBUTORS:

1. Professor, Department of Orthodontics, Faculty of Dental Sciences, SGT University, Budhera, Gurugram, Haryana, India.
2. Aesthetic Dental Surgeon, Private Practitioner, Department of Aesthetic Dentistry, Teeth and Braces Super-specialty Dental Care Centre, Gurugram, Haryana, India.

NAME, ADDRESS, E-MAIL ID OF THE CORRESPONDING AUTHOR:

Dr. Santosh Kumar,
Professor, Department of Orthodontics and Dentofacial Orthopaedics, Faculty of Dental Sciences, SGT University, Budhera, Gurugram-122505, Haryana, India.
E-mail: drsantoshortho@gmail.com

PLAGIARISM CHECKING METHODS: [Jan Het al.]

- Plagiarism X-checker: Aug 11, 2022
- Manual Googling: Dec 26, 2022
- iThenticate Software: Nov 03, 2022 (20%)

ETYMOLOGY: Author Origin

AUTHOR DECLARATION:

- Financial or Other Competing Interests: None
- Was informed consent obtained from the subjects involved in the study? Yes
- For any images presented appropriate consent has been obtained from the subjects. Yes

Date of Submission: **Aug 07, 2022**

Date of Peer Review: **Oct 06, 2022**

Date of Acceptance: **Nov 07, 2022**

Date of Publishing: **Jan 01, 2023**