

Rare Case of Caesarean Scar Pregnancy with Soaring β -hCG Levels: A Therapeutic Challenge

NISHTHA JAISWAL¹, REENA YADAV², APURWA BARDHAN³, MANISHA KUMAR⁴

ABSTRACT

Caesarean Scar Pregnancy (CSP) is a life-threatening form of ectopic pregnancy characterised by abnormal implantation of embryo within the myometrium and fibrous tissues of a previous scar on the uterus. This is the case report of a 24-year-old pregnant lady who underwent previous caesarean section presented at eight weeks gestation with bleeding per-vaginam. Ultrasound of pelvis revealed an intrauterine gestational sac with a live foetus at the site of previous caesarean scar with very high levels of serum beta-human Chorionic Gonadotropin (β -hCG) of 88789 mIU/mL. To prevent surgical complications, a conservative approach was employed, involving injection methotrexate and uterine artery embolisation. Serial measurements of serum β -hCG and transvaginal sonography were used for monitoring. Treatment was successful and the β -hCG levels returned to normal on day 48. This case report highlights that conservative management is successful even with extremely high serum β -hCG levels, and an early recognition and timely intervention is the key to prevent poor outcomes.

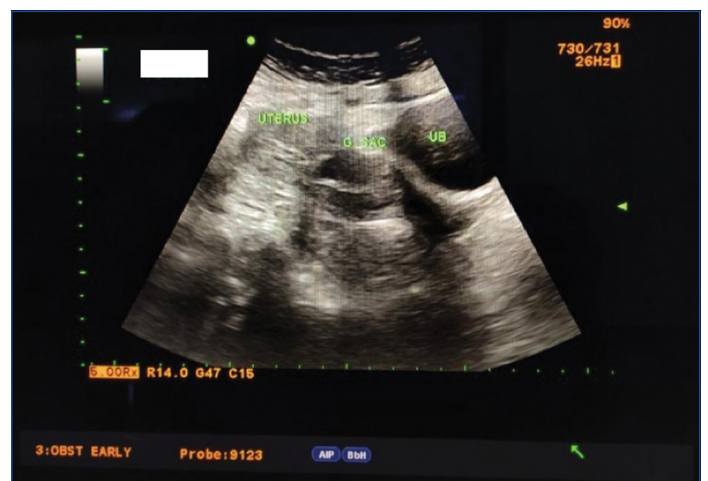Keywords: Ectopic pregnancy, Maternal morbidity, Medical management, Scar site

CASE REPORT

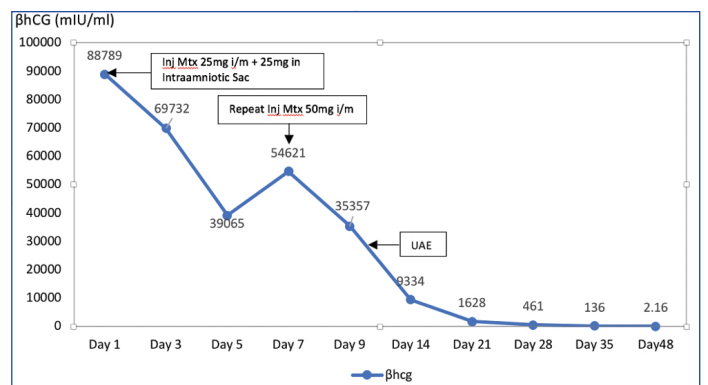
A 24-year-old female patient reported at eight weeks of gestation with a chief complaint of bleeding per vaginam for two days. She had one living child, born out of a lower segment Caesarean Section (CS) before four years ago followed by a spontaneous abortion one year back requiring dilatation and curettage. The patient was haemodynamically stable. Transvaginal ultrasound revealed a single intrauterine gestational sac with live foetus in the lower uterine segment at the previous caesarean scar site with Crown Rump Length (CRL) of eight weeks [Table/Fig-1]. The beta-human Chorionic Gonadotropin (β -hCG) level on the day of admission was found to be raised (88789 mIU/mL). Diagnosis of Caesarean Scar Pregnancy (CSP) was made and the patient was admitted for further management. In order to prevent surgical complications associated with CSP, decision for conservative management was taken. Ultrasound guided intra-amniotic sac instillation of 25 mg Methotrexate (Mtx) was done and 25 mg Mtx was given to the patient systemically (intramuscular injection). Post injection an ultrasound was done and confirmed the loss of foetal cardiac activity. Serial β -hCG monitoring was done [Table/Fig-2]. After an initial fall in β -hCG levels there was an increase in the values on day 7 of intervention, following which another dose of 50 mg injection Mtx was given to the patient intramuscularly. Uterine Artery Embolisation (UAE) was done on day 11 as the patient complained of increased bleeding per vaginam. Repeat ultrasound showed residual heterogenous contents at the scar site with minimal vascularity and no identifiable foetal parts. β -hCG showed a falling trend and the patient was discharged on day 30. On further follow-up, the β -hCG levels reached normal values on day 48 after which patient had normal menstruation. Follow-up ultrasound done after four weeks showed an empty uterus with no discernible intrauterine contents [Table/Fig-3].

DISCUSSION

Caesarean scar pregnancy is a rare form of ectopic pregnancy where there is complete or partial implantation of the gestational sac, villi and placenta into the myometrium of a previous scar [1]. The incidence of CSP is approximately 1:2,000 of all pregnancies

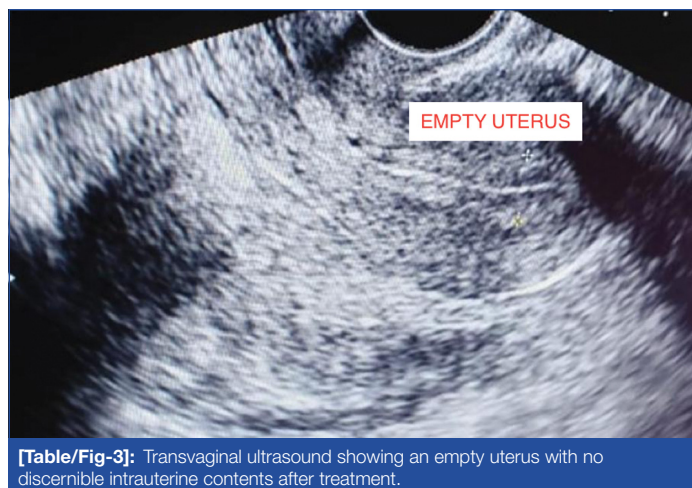

[Table/Fig-1]: Transvaginal ultrasound showing intrauterine Gestational Sac (G SAC) with foetus at the previous caesarean scar site posterior to Urinary Bladder (UB).



[Table/Fig-2]: Trends of serum β -hCG levels (mIU/mL) following conservative management

[2,3]. There is increased occurrence of CSP in recent years and it is a serious life threatening disorder. The pathophysiology of CSP involves implantation of gestational sac in a poorly healed CS scar or invasion into the myometrium via a microscopic dehiscence tract of



[Table/Fig-3]: Transvaginal ultrasound showing an empty uterus with no discernible intrauterine contents after treatment.

the caesarean scar. The commonest symptom is painless vaginal bleeding, that may be massive and the diagnosis depends upon transvaginal ultrasonography and colour doppler findings. In a study conducted by Lin Y et al., the patients of CSP were divided into three broad categories depending on the ultrasound findings [4].

Type I: (a) Partial implantation of the gestational sac into the uterine scar, partially or mostly located in the uterine cavity, and even reaching the bottom of the uterine cavity in some cases; (b) Deformed and elongated gestational sac with acute lower end; (c) The myometrium between the gestational sac and the bladder >3 mm; (d) Colour doppler ultrasound showing trophoblast blood flow signal (low resistance blood flow) in the scar.

Type II: (a) Partial implantation of the gestational sac into the uterine scar, partially or mostly located in the uterine cavity, and even reaching the bottom of the uterine cavity in some cases; (b) Deformed and elongated gestational sac with acute lower end; (c) The myometrium between the gestational sac and the bladder ≤3 mm; (d) Colour doppler ultrasound showing trophoblast blood flow signal (low resistance blood flow) in the scar.

Type III: (a) Complete implantation of the gestational tissues in the muscular layer of the uterine scar with protrusion outward towards the bladder; (b) Uterine cavity and cervical canal empty; (c) Very thin myometrium between the gestational sac and the bladder ≤3 mm or may be even missing; (d) Colour doppler ultrasound showing trophoblast blood flow signal (low resistance blood flow) in the scar.

Treatment options of CSP include expectant management, medication, UAE, curettage, surgery and their combination, but the optimal management remains to be determined [5]. The most important aim of treatment is to prevent massive haemorrhage and to conserve the uterus for future fertility. A multimodal approach was used in the treatment of the present case patient with successful outcome using Mtx in combination with uterine artery embolisation for optimum conservative management of CSP despite a soaring serum β-hCG levels of 88789 mIU/mL.

In 2016, Birge O et al., reported a similar case of CSP in a 46-year-old woman managed successfully with Mtx, however their initial β-hCG levels was not as high [6]. In a systematic review conducted by Gonzalez N and Tulandi T they compared the success of different modalities of treatment for CSP and found that while local and systemic Mtx had comparable cure rates of 69.2% vs 67.3%, respectively, the success rate was 99.16% when Mtx was combined with UAE [7]. Similarly in a meta-analysis conducted by Maheux-Lacroix S et al., it was found that medical therapy with Mtx, in haemodynamically stable women, had success rates of 56%, 60%, and 77% for systemic, local, and combined systemic and local therapy, respectively [8]. Cali G et al., reported higher risk of maternal morbidity including severe haemorrhage, early uterine rupture and hysterectomy in a CSP with positive foetal heart activity, if managed expectantly [9]. Most reported cases of medical management of CSP have an initial β-hCG levels much lower than the present case subject. It is worth mentioning that a patient with a very high serum β-hCG (88789 mIU/mL) could also respond to conservative medical management.

CONCLUSION(S)

Accurate, and early diagnosis of CSP and effective management are important to reduce maternal morbidity and mortality. Effective use of management with methotrexate combined with uterine artery embolisation can prevent complications such as massive haemorrhage and uterine rupture and need for untimely hysterectomies in young patients.

REFERENCES

- Gao L, Huang Z, Zhang X, Zhou N, Huang X, Wang X. Reproductive outcomes following cesarean scar pregnancy - a case series and review of the literature. *Eur J Obstet Gynecol Reprod Biol.* 2016;200:102-07.
- Jauniaux E, Jurkovic D. Placenta accreta: pathogenesis of a 20th century iatrogenic uterine disease. *Placenta.* 2012;33:244-51.
- Jurkovic D, Hillaby K, Woelfer B, Lawrence A, Salim R, Elson CJ. Cesarean scar pregnancy. *Ultrasound Obstet Gynecol.* 2003;21:310.
- Lin Y, Xiong C, Dong C, Yu J. Approaches in the treatment of cesarean scar pregnancy and risk factors for intraoperative hemorrhage: a retrospective study. *Front Med.* 2021;8:682368.
- Lumbiganon P, Laopaiboon M, Gulmezoglu AM, Souza JP, Taneepanichskul S, Ruyan P, et al. Method of delivery and pregnancy outcomes in Asia: the WHO global survey on maternal and perinatal health 2007-08. *Lancet.* 2010;375:490-99.
- Birge Ö, Karaca C, Arslan D, Kinali E. Medical management of cesarean scar pregnancy at advanced age: case report and literature review. *Clin Exp Obstet Gynecol.* 2016;43(1):140-42.
- Gonzalez N, Tulandi T. Cesarean scar pregnancy: a systematic review. *J Minim Invasive Gynecol.* 2017;24(5):731-38.
- Maheux-Lacroix S, Li F, Bujold E, Nesbitt-Hawes E, Deans R, Abbott J. Cesarean scar pregnancies: a systematic review of treatment options. *J Minim Invasive Gynecol.* 2017;24(6):915-25.
- Cali G, Timor-Tritsch IE, Palacios-Jaraquemada J, Monteagudo A, Buca D, Forlani F, et al. Outcome of cesarean scar pregnancy managed expectantly: Systematic review and meta-analysis. *Ultrasound Obstet Gynecol.* 2018;51(2):169-75.

PARTICULARS OF CONTRIBUTORS:

- Associate Professor, Department of Obstetrics and Gynaecology, Lady Hardinge Medical College, New Delhi, Delhi, India.
- Director Professor and Head, Department of Obstetrics and Gynaecology, Lady Hardinge Medical College, New Delhi, Delhi, India.
- Ex-Senior Resident, Department of Obstetrics and Gynaecology, Lady Hardinge Medical College, New Delhi, Delhi, India.
- Director Professor, Department of Obstetrics and Gynaecology, Lady Hardinge Medical College, New Delhi, Delhi, India.

NAME, ADDRESS, E-MAIL ID OF THE CORRESPONDING AUTHOR:

Dr. Nishtha Jaiswal,
203, Type 4 LHMC Faculty Flats, New Delhi, Delhi, India.
E-mail: nishtha.amu@gmail.com

AUTHOR DECLARATION:

- Financial or Other Competing Interests: None
- Was informed consent obtained from the subjects involved in the study? Yes
- For any images presented appropriate consent has been obtained from the subjects. Yes

PLAGIARISM CHECKING METHODS: [Jain H et al.]

- Plagiarism X-checker: May 31, 2022
- Manual Googling: Aug 13, 2022
- iThenticate Software: Aug 17, 2022 (15%)

ETYMOLOGY: Author Origin

Date of Submission: **May 25, 2022**
Date of Peer Review: **Jul 16, 2022**
Date of Acceptance: **Aug 18, 2022**
Date of Publishing: **Dec 01, 2022**