

Ultrasound-guided Percutaneous Drainage of Intra-abdominal Collection and its Clinical Outcome: A Prospective Interventional Study

SUSHANT AGARWAL¹, BIJIT KUMAR DUARA², RAJIB AHMED³, BHASKAR DAS⁴

ABSTRACT

Introduction: Intra-abdominal collections are abscesses that occur within the peritoneal cavity, the pelvis or behind the peritoneum (retroperitoneum) or intra-parenchymal. They are common complications of colorectal disease, particularly inflammatory bowel disease, malignancy and trauma. Ultrasound is very useful in establishing the diagnosis, quantification and localisation of intra-abdominal abscesses. Open Surgical Drainage (SD) used to be the traditional treatment protocol. Recently however, percutaneous drainage procedures are becoming an essential therapeutic strategy in the treatment of this condition.

Aim: To study the therapeutic efficacy of ultrasound-guided drainage of abdominal abscess and to compare it with open SD.

Materials and Methods: A prospective interventional study was conducted in 94 patients with intra-abdominal abscess at Gauhati Medical College and Hospital, Guwahati, Assam, India, in between July 2019 to June 2020 who were randomly allocated into two groups and underwent respective procedures. The first group was Percutaneous Catheter Drainage (PCD) and second group was open Surgical Drainage (SD) group. Patient demographics, symptoms, aetiologies and locations of the collections as well as duration of hospital stay, success

rate, and complications were analysed. Results of radiological findings were tabulated, evaluated and collated between both the groups. Statistical Package for Social Sciences (SPSS) software 21.0 version was used for analysing data and p-value <0.05 was considered significant.

Results: For abdominal collections and abscesses, ultrasound guided percutaneous drainage was successful in 96.8% of the patients whereas it was successful in 80% cases in the SD group. Complications were more frequently encountered in patients who underwent open SD (16.70%) compared to percutaneous drainage (12.40%) which was significant (p-value 0.0136). The average duration of stay for the group undergoing percutaneous drainage was 9.13±1.62 days which was shorter than for the group undergoing SD was 11.10±1.75 days (p-value <0.001). The overall rate of failed percutaneous drainage was 3.2% as compared to SD where it was 20%.

Conclusion: The present study concluded that, image-guided percutaneous drainage has lesser complications and higher success rate for abdominal collections/abscesses as compared to SD. Due to lower mortality rates as well as shorter duration of hospitalisation than open SD, it can replace the traditional open or laparoscopic approach of drainage in most cases.

Keywords: Abdominal abscess, Pigtail catheterisation, Postoperative complications, Ultrasonography

INTRODUCTION

Intra-abdominal collections are abscesses that occur within the abdominal cavity i.e., within the peritoneal cavity, the pelvis or behind the peritoneum (retroperitoneum) [1]. They are common complications of colorectal disease, particularly inflammatory bowel disease, malignancy and trauma. Ultrasound is very useful in establishing the diagnosis, quantification and localisation of intra-abdominal abscesses. But, it is limited by presence of ileus and big exploratory wounds with the covering dressings [2]. The usual mechanism of visceral abscesses include haematogenous or lymphatic spread of an infective organism usually bacteria to an organ [3]. Non visceral abscesses usually occur after resolution of a diffuse peritoneal infective aetiology after which a loculated infected area or collection is localised by defensive mechanisms of the peritoneum [4].

Ultrasonography and Computed Tomography (CT) scan help in quantification and localisation of collection. Traditionally, open Surgical Drainage (SD) with adjuvant antibiotics has been used. However, sophisticated percutaneous drainage methods have recently gained importance for management of this problem. Image-guided percutaneous drainage of abdominal collections and abscesses show a high success rate with the advantage of being minimally invasive and thus, has been recently considered as the treatment of choice for the majority of cases regardless of aetiology. Percutaneous Drainage (PCD) is thus, feasible for critically-ill patients who are unfit for general anaesthesia. In most patients,

percutaneous drainage has replaced the old approach of abdominal collection drainage, and it is also employed as a temporary remedy in critically sick patients [5].

Studies have been done comparing the effectiveness of SD vs percutaneous drainage in management of intra-abdominal abscess drainage [5,6]. However, a review of literature of the topic revealed that there were very few studies that have been done for comparison in India, even though, India having a very high prevalence of intra-abdominal collections [7,8]. Due to its benefit in cost and morbidity, the present study aims to explore the benefit of percutaneous drainage in being a better management modality for treatment of abdominal abscesses.

Therefore, the aim of the present study was to evaluate the therapeutic efficacy of ultrasound-guided drainage of abdominal abscesses and its relationship with surgical drainage of abdominal abscesses.

MATERIALS AND METHODS

This was a prospective interventional study on the outcome of PCD for treatment of intra-abdominal abscess conducted among 94 patients with intra-abdominal abscess at Gauhati Medical College and Hospital, Guwahati, Assam, India, in between July 2019 to June 2020 after taking approval from Institutional Ethical Committee (No. MC/190/2007/Pt-11/Mar-2019/PG/111). Patients who gave written informed consent to participate in the procedure were included in the study.

The patients with clinical suspicion of intra-abdominal collection/abscess were assessed by detailed history and clinical examination as well as routine blood tests including complete blood count, renal function tests, urine microscopy, serology for Hepatitis B and C, Human Immunodeficiency Virus (HIV) and liver function tests. Diagnosis was confirmed by radiological investigations ultrasonography of abdomen and, if required, CT scan of the abdomen. The patients with ultrasound or CT documented collections/abscesses were assessed for image-guided percutaneous intervention as per the following inclusion and exclusion criteria.

Inclusion criteria: Patient of age group between 20 to 70 years and both genders with collection size more than 5 cm on ultrasound/CT scan presenting with sufficient suspicion of symptoms due to collection and refractory to medical management were included in the study.

Exclusion criteria: Patients below age of 20 and above the age of 70 years. Patients with co-existing uncorrected coagulopathy and uncooperative, unstable patients or refusal for procedure were excluded from the study.

Sample size calculation: A total of 130 total patients were included in the present study by convenient sampling, who were randomised into two groups (n=65 each) by computer generated random numbers with a block size of 10. The patients were allocated into two groups, however, due to period of strict lockdown during the course of the study period, detailed reports and data collection of only 30 patients in the SD group could be done. One patient from the PCD was lost to follow-up. The total sample size was 94 patients.

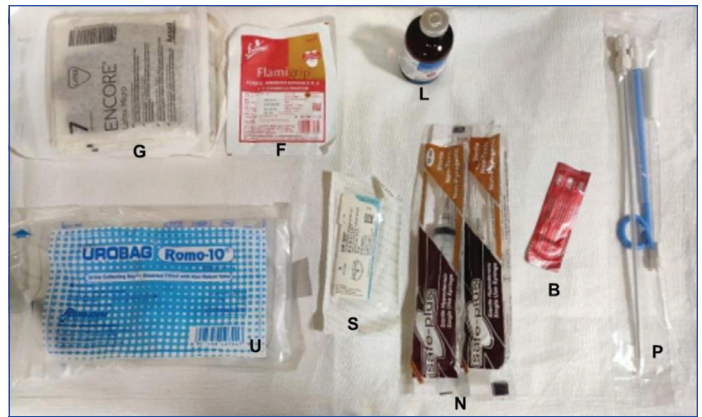Percutaneous Drainage (PCD) group (n=64)

Open Surgical Drainage (SD) group (n=30)

Study Procedure

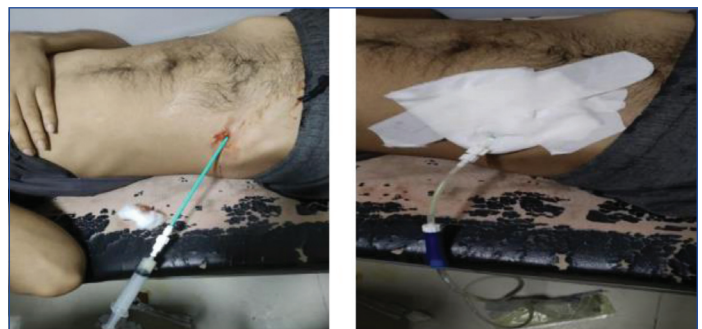Percutaneous Catheter Drainage (PCD) technique: Suitable antibiotic cover was started a day prior to the procedure. Abscess was localised by ultrasonography and a safe drainage route planned to avoid injury to other intra-abdominal organs. The local area was cleaned with betadine and spirit. With aseptic precaution sufficient local anaesthesia was given with 2% lignocaine. A stab incision (5 mm) was made at the planned skin entry site. The "trocar method" was used [9]. The locking pigtail catheter (Devon® percutaneous pigtail suprapubic catheter set, 8F/10F, length 22 cm) was mounted on a sharp stylet and introduced under sonographic guidance. Once, it was confirmed that sheath was in the cavity by imaging it was reconfirmed by removing stylet and aspirating the pus. The catheter was attached to a drainage bag (Urobag Romo 10). The catheter was fixed to the skin by 2-0 mersilk non absorbable reverse cutting surgical suture (Ethicon®) and a sterile dressing pad was applied. All catheters were allowed for gravity drainage and were flushed three to four times daily with 10 mL of sterile saline to prevent its blockage with debris. Intravenous (i.v.) ceftriaxone-sulbactam (1.5 grams i.v. twice daily) and (metronidazole 500 mg i.v. thrice daily) were given in therapeutic doses for a period of 2-4 weeks. Alternate day ultrasonogram studies were done to monitor the cavity size and volume and to confirm the position of tip of the catheter. The pigtail catheter was removed when drainage either ceased or was minimal and disappearance or reduction in size of collections on repeat imaging [Table/Fig-1,2].

Open Surgical Drainage (SD) technique: For open SD patients were made to fast for at least six hours and abscess localised by USG and marked. All surgeries were performed under general or epidural anaesthesia (3 mL 1.5% lignocaine with adrenaline 15 µ). The abdominal wall was opened in layers with an incision according to prior localisation by ultrasound. The abscess was localised and haemostatic forceps was used to enter the abscess cavity. It was completely drained out with suction. A thorough wash was given



[Table/Fig-1]: Tray showing equipments including 12-french catheter.

G: gloves; F: Elastic Adhesive Bandage (Flamingo Flavigrip); L: Lignocaine Hydrochloride 2%; U: drainage bag (Urobag Romo 10); S: 2-0 mersilk non absorbable reverse cutting surgical suture; N: 10 mL sterile syringe; B: Size 11 blade; P: pigtail catheter with stylet (Devon® percutaneous pigtail suprapubic catheter set, 8F/10F, length 22 cm)



[Table/Fig-2]: The procedure of pigtail catheter drainage. The image on the left shows the confirmation of the position of the catheter by aspiration. The image on the right shows pigtail catheter connected with the urobag.

with normal saline (0.9%). A thorough examination of the intra-abdominal contents was made to rule out other intra-abdominal pathology. Large bore tube drain was placed and brought out through a separate stab incision and the abdomen was closed in layers. Patient was monitored regularly with a watch on the temperature, pulse, respiration in the postoperative period. Oral feeds were started as tolerated by the patient. Drains were removed accordingly [Table/Fig-1,2].

Drainage was recorded daily and the response to treatment assessed by clinical and laboratory parameters and also by serial ultrasound. Normal saline was used for irrigation, whenever required. The duration of stay and time of defervescence of fever was recorded for every patient. Patients were followed-up for a period of three months and any complications during this period were recorded and managed according. The patients were discharged with clinical improvement; in ambulatory state, tolerating proper diet and oral antibiotics.

Success was defined by the following criteria [5]:

- After the abscess treatment, the patient recovered with improvement of symptoms, decreased White Blood Count (WBC) counts, improved appetite and overall condition.
- No recurrence or infectious complications observed within a three month follow-up after removal of catheter.
- Significant decrease in size on follow-up imaging by ultrasound (>60% reduction) with no evidence of loculation or multiple collections.

STATISTICAL ANALYSIS

Data were entered into Microsoft Excel sheet and Statistical Package for Social Sciences (SPSS) software 21.0 version was used for analysing data and p-value <0.05 was considered significant. The qualitative variables were presented as, percentages, frequencies and proportions. Categorical variables were presented in the form

of frequencies and percentages while continuous variables were presented as mean±Standard Deviation (SD). The association of qualitative variables was analysed using Fisher's-exact test and quantitative variables using Student's t-test.

RESULTS

Of the total 94 of cases included in the study, 64 patients were included in the ultrasound-guided PCD and 30 patients were included in the conventional SD group. Mean age of the population was 42 years with a standard deviation of eight years. The majority of the patients were in the age group of 41-50 years in percutaneous drainage and 21-30 years in SD group [Table/Fig-3].

Age (in years)	Percutaneous drainage n (%)	Surgical drainage n (%)
21-30	9 (14.06)	10 (33.33)
31-40	21 (32.81)	8 (26.67)
41-50	22 (34.38)	5 (16.67)
51-60	11 (17.19)	6 (20)
61-70	1 (1.56)	1 (3.33)

[Table/Fig-3]: Age distribution of intra-abdominal abscess in the studied population.

Abdominal pain was the most common symptom present in 84.4% patients with fever was the second most common symptom present in 65.6% of the patients followed by nausea/vomiting found in 48.4% in patients in PCD. Abdominal pain was also the most common symptom present in 73.3% patients in the SD group [Table/Fig-4].

Symptoms	Percutaneous drainage n (%)	Surgical drainage n (%)
Abdominal pain	54 (84.4)	22 (73.3)
Fever	41 (65.6)	18 (6)
Jaundice	14 (21.9)	4 (13.3)
Nausea/vomiting	31 (48.4)	13 (43.3)
Anorexia	19 (29.7)	17 (56.7)
Weight loss	11 (17.2)	10 (33.3)
Diarrhoea	3 (4.7)	5 (16.7)

[Table/Fig-4]: Showing symptoms associated with intra-abdominal abscess in the studied population.

PCD: Percutaneous drainage group; SD: surgical drainage group

Most of the cases were of unknown primary (32.8% and 40%) both in PCD and SD group followed by postoperative (20.3% in PCD group) and appendicitis (20% in SD group) with other causes are Crohn's disease, biliary pathology, diverticular, hepatitis, pancreatitis, pyelonephritis, abdominal trauma and tubercular [Table/Fig-5].

Aetiology	Percutaneous drainage n (%)	Surgical drainage n (%)	Total n (%)	p-value (Fischer's-exact test)
Appendicitis	4 (6.3)	6 (20)	10 (10.64)	0.015
Biliary pathology	4 (6.3)	4 (13.3)	8 (8.51)	
Crohn's disease	0	2 (6.7)	2 (2.13)	
Diverticular	1 (1.6)	1 (3.3)	2 (2.13)	
Hepatitis	7 (10.9)	1 (3.3)	8 (8.51)	
Pancreatitis	8 (12.5)	0	8 (8.51)	
Postoperative	13 (20.3)	0	13 (13.83)	
Pyelonephritis	2 (3.1)	2 (6.7)	4 (4.26)	
Traumatic	1 (1.6)	1 (3.3)	2 (2.13)	
Tubercular	3 (4.7)	1 (3.3)	4 (4.26)	
Unknown primary	21 (32.8)	12 (40)	33 (35.11)	

[Table/Fig-5]: Distribution of patients in the studied population based on the aetiology of intra-abdominal abscess.

p-value <0.05 was considered as statistically significant

Majority of abscesses in the studied population had a solitary lesion (81.3%) in the PCD but the majority of abscess in the SD were multiple (56.70%). The hepatic abscess collection was the most prevalent site followed by the subhepatic and pelvic. Other location of abscess formation in PD and SD groups included 11 patients had abscess in lesser sac, 10 patients had abscesses in the subdiaphragmatic, seven patients had abscess in perinephric and psoas abscess each and six patients had abscesses in ileocaecal and paracolic regions each [Table/Fig-6].

Location	Percutaneous drainage n (%)	Surgical drainage n (%)	Total n (%)	p-value (Fischer's-exact test)
Hepatic	20 (31.3)	6 (20)	26 (27.7)	0.067
Ileocaecal	3 (4.7)	3 (10)	6 (6.4)	
Lesser sac	9 (14.1)	2 (6.7)	11 (11.7)	
Paracolic	3 (4.7)	3 (10)	6 (6.4)	
Pelvis	3 (4.7)	6 (20)	9 (9.6)	
Perinephric	4 (6.3)	3 (10)	7 (7.4)	
Psoas abscess	3 (4.7)	4 (13.3)	7 (7.4)	
Subdiaphragmatic	9 (14.1)	1 (3.3)	10 (10.6)	
Subhepatic	9 (15.6)	2 (6.7)	12 (12.8)	

[Table/Fig-6]: Distribution of patients in the studied population based on the location of abscess.

p-value <0.05 was considered as statistically significant

The average duration of stay was longer in patients who underwent open SD (11.10±3.42 days) compared to percutaneous drainage (9.13±1.63 days). The mean time of defervescence of fever who underwent percutaneous drainage (4.31±1.75 days) and compared to percutaneous open SD (4.94±2.01 days) [Table/Fig-7]. Percutaneous drainage was successful in 96.8% patients whereas failure was seen in 3.2% patients, whereas, it was 80% successful and 20% failure in case of SD [Table/Fig-8].

Parameters	Percutaneous drainage (Mean±SD)	Surgical drainage (Mean±SD)	p-value (Student's t-test)
Average duration of stay (days)	9.13±1.62	11.10±3.42	<0.001
Mean time of defervescence of fever (days)	4.31±1.75	4.94±2.01	>0.05

[Table/Fig-7]: Comparison between PCD (n=64) and SD (n=30) group between given variables.

p-value <0.05 was considered as statistically significant

Variable	Percutaneous drainage n (%)	Surgical drainage n (%)
Success rate	62 (96.8)	24 (80)

[Table/Fig-8]: Success rate between PCD (n=64) and SD group (n=30).

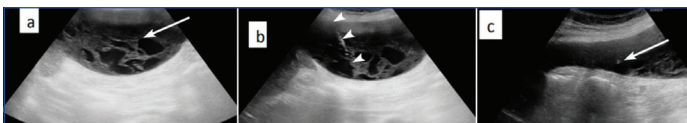
p-value <0.05 was considered as statistically significant

Complications were more frequently encountered in patients who underwent open SD (16.7%) compared to percutaneous drainage (12.4%) [Table/Fig-9]. In the PCD, complications included catheter blockage and catheter dislodgement which were seen in 4.7% and 3.1% patients, respectively in patients. Enteric communication, empyema, peritonitis and catheter site infection were seen in 1.6% patients each in the PCD. In the SD group, wound infection and bleeding were encountered in 6.7% patients each. Intestinal obstruction was seen in 3.3% of cases in SD [Table/Fig-9].

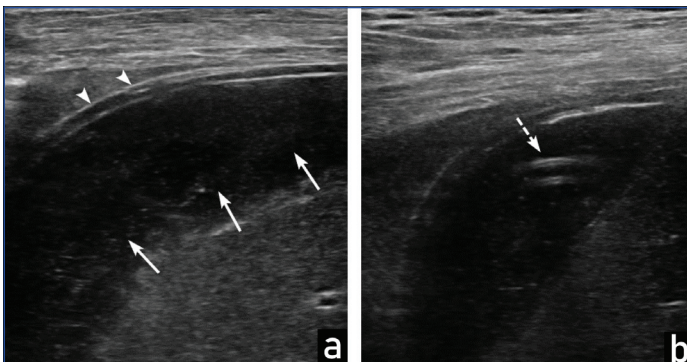
Predrainage and postdrainage USG scans for ultrasound guided percutaneous technique of intra-abdominal collections at different sites with are shown in [Table/Fig-10-12].

Complications	Percutaneous drainage n (%)	Surgical drainage n (%)	p-value (Fisher's-exact test)
Bleeding	0	2 (6.70)	0.0136
Catheter blockage	3 (4.70)	0	
Catheter dislodgement	2 (3.10)	0	
Catheter site infection	1 (1.60)	0	
Empyema	1 (1.60)	0	
Enteric communication	1 (1.60)	0	
Intestinal obstruction	0	1 (3.30)	
Peritonitis	1 (1.60)	0	
Wound infection	0	2 (6.70)	
Total	9 (12.40)	5 (16.70)	

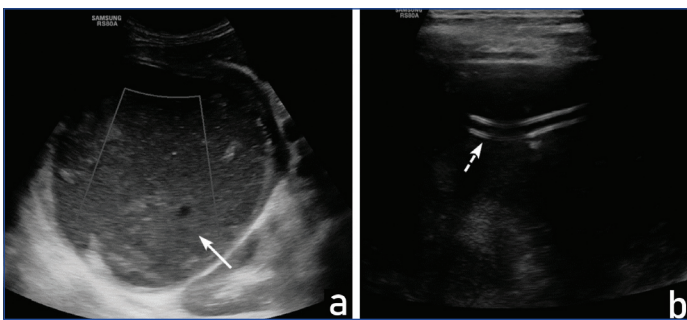
[Table/Fig-9]: Common complications encountered in patients who underwent percutaneous drainage and open Surgical Drainage (SD) of intra-abdominal abscess. p-value <0.05 was considered as statistically significant



[Table/Fig-10]: Pre-drainage and post-drainage ultrasound scans of right sub-hepatic collection. a) Ultrasound imaging shows a complex collection with internal echogenic septations in right sub-subhepatic region (arrow); b) Real-time pig tail catheterisation demonstrates the position of the needle and its tip (arrowhead) within the collection; c) Ultrasound showing pigtail catheter within the collection after the procedure.



[Table/Fig-11]: Pre-drainage and post-drainage ultrasound scans of sub diaphragmatic collection. a) Shows ultrasound examination of the abdomen performed showing subdiaphragmatic collection (white arrows) located beneath the diaphragm (arrowheads) before the procedure; b) shows pigtail catheter (white arrow) within the collection inserted via ultrasound guided percutaneous technique.



[Table/Fig-12]: Pre-drainage and post-drainage ultrasound scans of hepatic abscess. a) shows an ultrasound of liver depicting a large hepatic abscess in segment VI and VII of liver (arrow); b) shows the same patient with pigtail catheter within the abscess (dashed arrow).

DISCUSSION

In the present study, abdominal pain (84.4%) and fever (65.6%) were the most common symptoms observed in both PCD and SD groups. The present study is, also comparable with study reported by Dhurve AS et al., in which pain was the single most consistent symptoms, observed in all cases (100%) and associated with fever in 90% of cases [8]. In the present study, 35% patients the cause of abscess was not known called as cryptogenic cause. The present study is comparable with study reported by Dhurve AS et al., in which the cause of abscess was not known in 47.5% patients [8].

In India, liver abscesses are a very common tropical disease which was reflected in the present study with hepatic abscess being the most prevalent site of collection (31.3% of the cases in PCD and 20% cases in SD group) followed by the subhepatic site (15.6% in PD group) and pelvic (20% in SD group). This is comparable with study reported by Rajak CL et al., [10]. This is also comparable with study reported by Dhurve AS et al., who reported more visceral (solid organ) abscesses (67%) compared to both subphrenic and pelvic abscesses [8]. In a 2020 study by Wani RA et al., liver abscess was the most common cause of collection (64%) [5].

Intra-abdominal collections are treated by drainage, which can be either be done by traditional method of open surgical access or by image-guided percutaneous approach. The later has shown to supersede in the recent years. This is mainly because of the easier procedure, relative atraumatic nature as well as fewer complications. Akıncı D et al., encountered some catheter complications as dislodgement, obstruction, or kinking in (6.7%) of the patients, with no major injuries [6]. This was comparable to the present study with these complications accounting for 7.8% of patients. Dhurve AS et al., encountered different category of complications which are some cases of septicaemia and chest infections which are not related to the interventional maneuver itself, but a complication of the original septic condition [8].

In the present study, the total complication rate was 14.89%. There was a statistically significant higher rate of complication in the SD group (16.7%) as compared to PCD group (12.4%) (p-value=0.0136). Dhurve AS et al., reported a lower rate of complication of 7.5% in his 2018 study of USG guided percutaneous abscess drainage [8]. Akıncı D et al., and Lucey BC et al., also reported similar complication rates of 3.1% and 10.3%, respectively [6,11].

Mean hospital stay for the group undergoing percutaneous drainage (9.13±1.62 days) was shorter than for the group undergoing surgical (11.10±1.75 days) therapy (p-value <0.001). There were a variety of selection factors such as severity of illness and the presence of multiple abscesses that likely biased the surgically treated patients to ward a longer duration of hospitalisation. Politano AD et al., also reported that the median length of hospital stay in the SD group to be higher (28.1±1.62 days) than in the PCD group (13.5±0.78 days) (p-value <0.001) [12]. The same results were proved by Nguyen DL et al., who reported longer hospital stay (15.5 days) with SD compared to non SD [13].

In the current study, percutaneous drainage on which the study was focusing; there was a very significant success rate 96.8% patients and compared to the originally successful SD method. This is well compared and correlated with those reported by Akıncı D et al., [6]. A 84.4% of patients were successful drained by percutaneous techniques in a 2020 study by Wani RA et al., [5]. The present study had a failure rate of 3.2% in the PCD group. vanSonnenberg E et al., reported a failure rate of 8% in cases of abscess drainages which was higher than the present study [14]. This is correlated with study done by Akıncı D et al., with 6% failure rate [6].

There was no mortality noted in present study. This is correlated with the study done by vanSonnenberg E et al., where zero percent mortality was found [14]. Another study by Rafiq S et al., also had no mortality in their study done for loculated pleural space collections [15]. Wani RA et al., in their reported a mortality rate of 1.1% [5]. However, a 2011 study by Politano AD et al., reported a higher mortality in open SD (14.6%) than that in percutaneous drainage (4.2%) [12]. Percutaneous technique has a low complication rate and shorter mean hospital stay, as compared to surgery which is well-compared and correlated with those reported by Laganà D et al., and Gervais DA et al., who stated that percutaneous drainage is an effective alternative to operative drainage in patients at high risk, for general anaesthesia [16,17].

Limitation(s)

The present study was a single-centre study, which was done for a period of only one year. Further research is needed to generalise the results of the present study. Due to Coronavirus Disease-2019 (COVID-19) lockdown, during the course of the study period, detailed reports and data collection was only done for a small sample size. One patient from the PCD was lost to follow-up. The cases were followed-up only, for a shorter duration i.e, three months, complications beyond which were not taken into account for the study.

CONCLUSION(S)

Image-guided percutaneous drainage was found to be a safe, minimally invasive and relatively less traumatic procedure drainage technique for abdominal collections/abscesses with a high success rate. Ultrasonography as a choice of imaging guidance provides real-time visualisation of catheter position and movements, is cost-effective and free of ionising radiation. Percutaneous drainage has a lower rate of mortality, as well as, shorter duration of hospitalisation than open surgical drainage and thus, can replace the traditional open or laparoscopic approach of drainage in most cases.

REFERENCES

- [1] Mehta NY, Copelin II EL. Abdominal Abscess. In: StatPearls [Internet]. Treasure Island (FL): StatPearls Publishing; 2022.
- [2] Knochel JQ, Koehler PR, Lee TG, Welch DM. Diagnosis of abdominal abscesses with computed tomography, ultrasound, and 111In leukocyte scans. *Radiology*. 1980;137(2):425-32.
- [3] Adams DB, Harvey TS, Anderson MC. Percutaneous catheter drainage of infected pancreatic and peripancreatic fluid collections. *Arch Surg Chic Ill* 1960. 1990;125(12):1554-57.
- [4] Adil A, Ousehal A, Essodegui F, Abdelouafi A, Kadiri R. Percutaneous treatment of abdominal collections. Apropos of 135 cases. *J Radiol*. 1995;76(2-3):129-34.
- [5] Wani RA, Digra NC, Gupta K. Image-guided percutaneous drainage of intra abdominal fluid collections and abscesses: A hospital based prospective study. *World J Surg Surg Res*. 2020;3(1):1219.
- [6] Akıncı D, Ergun O, Topel Ç, Çiftçi T, Akhan O. Pelvic abscess drainage: Outcome with factors affecting the clinical success. *Diagn Interv Radiol*. 2018;24(3):146-52.
- [7] Shetty M, Deme S, Mohan K, Adiraju KP, Modugu NR, Chandra N, et al. Experience with splenic abscess from southern India. *J Clin Diagn Res*. 2016;10(10):OC22-25.
- [8] Dhurve AS, Bodade RM, Bugga RR, Nandu VV, Meshram MM. Clinical study of intra-abdominal abscess and its management by percutaneous USG guided drainage. *Int Surg J*. 2018;5(6):2211-16.
- [9] Fan W, Cc C, Chan J. Image-guided drainage using the trocar technique. *J Hong Kong Coll Radiol*. 2008;11:69-71.
- [10] Rajak CL, Gupta S, Jain S, Chawla Y, Gulati M, Suri S. Percutaneous treatment of liver abscesses: Needle aspiration versus catheter drainage. *AJR Am J Roentgenol*. 1998;170(4):1035-39.
- [11] Lucey BC, Boland GW, Maher MM, Hahn PF, Gervais DA, Mueller PR. Percutaneous nonvascular splenic intervention: A 10-year review. *AJR Am J Roentgenol*. 2002;179(6):1591-96.
- [12] Politano AD, Hranjec T, Rosenberger LH, Sawyer RG, Tache Leon CA. Differences in morbidity and mortality with percutaneous versus open surgical drainage of postoperative intra-abdominal infections: A review of 686 cases. *Am Surg*. 2011;77(7):862-67.
- [13] Nguyen DL, Sandborn WJ, Loftus EV, Larson DW, Fletcher JG, Becker B, et al. Similar outcomes of surgical and medical treatment of intra-abdominal abscesses in patients with Crohn's disease. *Clin Gastroenterol Hepatol*. 2012;10(4):400-04.
- [14] vanSonnenberg E, Mueller PR, Ferrucci JT. Percutaneous drainage of 250 abdominal abscesses and fluid collections. Part I: Results, failures, and complications. *Radiology*. 1984;151(2):337-41.
- [15] Rafiq S, Dar MA, Nazir I, Shaffi F, Shaheen F, Kuchay IA. Image-guided catheter drainage in loculated pleural space collections, effectiveness, and complications. *Lung India*. 2020;37(4):316-22.
- [16] Laganà D, Carrafiello G, Mangini M, Ianniello A, Giorgianni A, Nicotera P, et al. Image-guided percutaneous treatment of abdominal-pelvic abscesses: A 5-year experience. *Radiol Med (Torino)*. 2008;113(7):999-1007.
- [17] Gervais DA, Ho CH, O'Neill MJ, Arellano RS, Hahn PF, Mueller PR, et al. Recurrent abdominal and pelvic abscesses: incidence, results of repeated percutaneous drainage, and underlying causes in 956 drainages. *AJR Am J Roentgenol*. 2004;182(2):463-66.

PARTICULARS OF CONTRIBUTORS:

1. Assistant Professor, Department of Radiology, Gauhati Medical College and Hospital, Guwahati, Assam, India.
2. Professor, Department of Radiology, Gauhati Medical College and Hospital, Guwahati, Assam, India.
3. Resident, Department of Radiology, Gauhati Medical College and Hospital, Guwahati, Assam, India.
4. Resident, Department of Radiology, Gauhati Medical College and Hospital, Guwahati, Assam, India.

NAME, ADDRESS, E-MAIL ID OF THE CORRESPONDING AUTHOR:

Dr. Bhaskar Das,
Bhabani Path (Go Baat), Lalung Gaon, Betkuchi Shiva Shakti Nagar, NPS Road,
Guwahati-781040, Assam, India.
E-mail: bhaskardas314jan15@gmail.com

AUTHOR DECLARATION:

- Financial or Other Competing Interests: None
- Was Ethics Committee Approval obtained for this study? Yes
- Was informed consent obtained from the subjects involved in the study? Yes
- For any images presented appropriate consent has been obtained from the subjects. Yes

PLAGIARISM CHECKING METHODS: [\[Jain H et al.\]](#)

- Plagiarism X-checker: Sep 20, 2022
- Manual Googling: Nov 15, 2022
- iThenticate Software: Nov 22, 2022 (7%)

ETYMOLOGY: Author Origin

Date of Submission: **Sep 14, 2022**
Date of Peer Review: **Oct 21, 2022**
Date of Acceptance: **Nov 23, 2022**
Date of Publishing: **Dec 01, 2022**