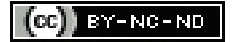

# A Rare Presentation of Controlled Chaos: Spontaneous Pneumothorax Under General Anaesthesia

S MANO PRAVEEN<sup>1</sup>, S AJANTH<sup>2</sup>, MANGESH S GORE<sup>3</sup>, LIPIKA A BALIARSING<sup>4</sup>, SNEHA B MINIYAR<sup>5</sup>, CHARULATA M DESHPANDE<sup>6</sup>



## ABSTRACT

Perioperative pneumothorax is a potentially dangerous and rare complication during general anaesthesia. Hereby, the authors report a case of 25-year-old female, who was posted for a dental procedure, and developed spontaneous pneumothorax under general anaesthesia. The patient had no co-morbidities or risk factors during the perioperative period and classified as American Society of Anaesthesiologist's (ASA) class I. She was planned under general anaesthesia with an orotracheal intubation with controlled positive pressure ventilation. At the end of the surgery, she developed significant respiratory changes, which rose the suspicion of pneumothorax and later, it was confirmed radiologically. This early suspicion and early intervention by tube thoracostomy in Postanaesthesia Care Unit (PACU) stabilised the patient and resolved eventually. Early recognition and appropriate intervention can mitigate the perioperative outcome and reduce morbidity. Positive pressure ventilation, Positive End Expiratory Pressure (PEEP) and airway handling being the major predisposing factors for the development of pneumothorax. This further reiterates the need for keen perioperative vigilance for early recognition and appropriate management. Although rare, pneumothorax should be considered as differential diagnosis in crisis scenarios like tight bag.

**Keywords:** Anaesthetic challenges, Bronchospasm, Positive pressure ventilation, Positive end expiratory pressure

## CASE REPORT

A 25-year-old female weighing 45 kg, was scheduled for a surgery to treat her cleft lip and palate. She was operated for cleft lip and palate at 10 months of age and revision cleft palate surgery at 15 years of age under general anaesthesia and both were uneventful. She was planned for transport distraction of the left cleft alveolus under general anaesthesia, in view of persistent nasal regurgitation through the remnant cleft palate. On examination, the patient had fair physical status, effort tolerance of more than three flights of stairs and no co-morbidities/addictions.

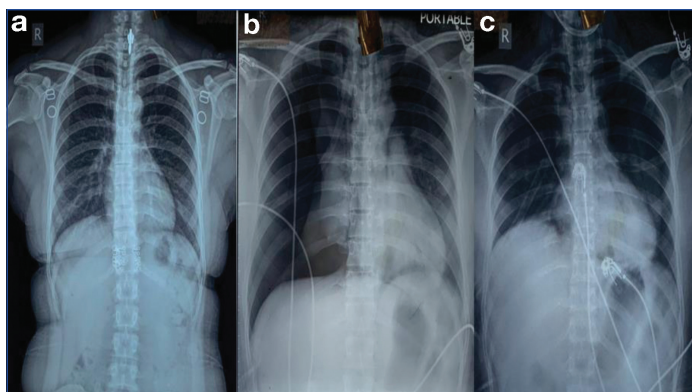
The vitals were, heart rate was 76/min, blood pressure was 100/60 mmHg and respiratory rate was 12/min. Cardiovascular and respiratory system examination were not significant. Airway examination revealed three fingers mouth opening, modified Mallampatti grade I, adequate neck movements, thyromental distance >6 cm, normal dentition with braces on both jaws. A small cleft of size 1x1.2 cm was noted in the hard palate. Bilateral nasal patency was confirmed (right>left). Blood investigations, chest X-ray and 12-lead Electrocardiogram (ECG) were within normal limits.

On the day of the surgery, an informed consent was taken after confirming preoperative fasting and it was planned to do orotracheal intubation. After establishing a 20 Gauge intravenous line and standard American Society of Anaesthesiologists (ASA) monitoring, the patient was premedicated with Inj. glycopyrrolate 0.2 mg i.v and Inj. midazolam 1 mg i.v. Anaesthetic induction was done after preoxygenation for three minutes, with Inj. fentanyl 100 mcg i.v and Inj. propofol 100 mg i.v. Muscle relaxation was achieved with Inj. atracurium 30 mg i.v. After confirming bag and mask ventilation, orotracheal intubation was achieved with the flexometallic 6.5 mm cuffed Endotracheal Tube (ETT) and secured at 20 cm mark after confirming bilateral air entry. Maintenance of anaesthesia was achieved with Oxygen:Air (50:50), sevoflurane (1-2%) with target Minimum Alveolar Concentration (MAC) of 1.0 and connected to mechanical ventilation using the volume-controlled ventilation with settings of Tidal Volume (VT) was 380 mL, respiratory rate

was 14/min. The surgery was in supine position and the patient's haemodynamic and respiratory markers were within normal limits throughout the procedure. It lasted for approximately 150 minutes and went uneventfully.

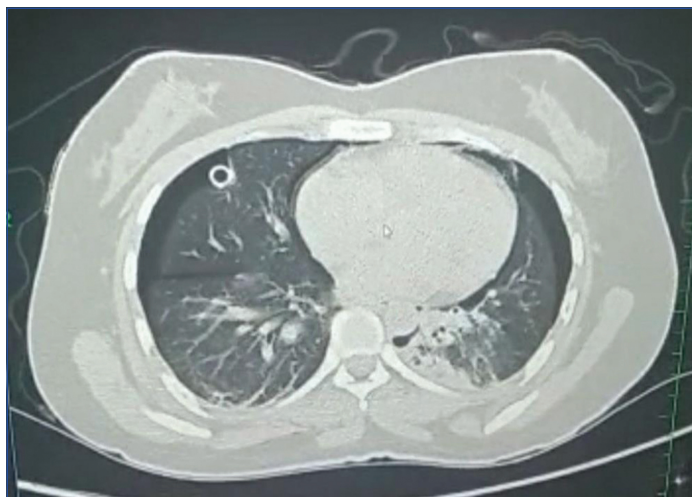
While closure, the patient developed high peak airway pressure (>40 cm H<sub>2</sub>O), rise in End-tidal Carbon Dioxide (EtCO<sub>2</sub>) (>50 mmHg), rise in concentration of inspired carbon dioxide (FiCO<sub>2</sub>) (>0.1) transiently, fall in SpO<sub>2</sub> till 85% and rise in heart rate (110/min). She was ventilated using 100% oxygen, significant resistance was appreciated. On auscultation, signs of bronchospasm were detected. Bronchodilator (salbutamol) puffs were given and ventilated with 100% oxygen and 2% sevoflurane and Inj. aminophylline 125 mg i.v. was given over five minutes. Eventually, the patient's respiratory parameters were settled and it was decided to extubate the patient. Prior to reversal, a thorough oropharyngeal suctioning was done and extubated on achieving adequate spontaneous respiratory efforts and the patient satisfying all criteria of extubation. After 10 minutes, the patient became restless, tachypnoeic (rate >30/min) and started complaining of left hypochondriac chest pain and SpO<sub>2</sub> fell down to 90%. She was given head elevation and oxygenated using 100% oxygen. On auscultation, there was reduced air entry on the right-side significantly. It was decided to shift the patient to Postanaesthesia Care Unit (PACU) for postoperative monitoring and further management [Table/Fig-1].

At PACU, 12-lead ECG, chest X-ray, Arterial Blood Gas (ABG) and Troponin-T were sent immediately. ABG values were, pH-7.413, PCO<sub>2</sub>-32.5, PO<sub>2</sub>-84.9, HCO<sub>3</sub>-20. Chest X-ray revealed right pneumothorax, Pneumomediastinum with right lung collapse. Right tube thoracostomy was performed by cardiothoracic surgeons promptly. Patient vitals were maintained throughout and oxygenation continued with oxygen 10 L/min using Non-Rebreather Mask (NRBM). High Resolution Computed Tomography (HRCT) thorax was done on the next day after stabilisation and revealed bilateral pneumothorax (Right>Left) and pneumomediastinum with right intercostal Drainage (ICD) tube in-situ and left lower zone atelectasis [Table/Fig-2]. Left small pneumothorax and pneumomediastinum



**[Table/Fig-1]:** a) Preoperative chest X-ray film; b) Right pneumothorax and lung collapse; c) Post-intercostal drainage insertion.

was diagnosed after HRCT and treated conservatively on chest physician's advice. Chest physiotherapy, deep breathing exercises, incentive spirometry and bronchodilator nebulisation was initiated post-ICD insertion. Patient was mobilised early on 4<sup>th</sup> day and chest X-ray was repeated on the same day. Right ICD tube was clamped on 5<sup>th</sup> day after confirming complete re-expansion of the lung. Chest X-ray was repeated after 12 hours and ICD was removed on 7<sup>th</sup> day. The patient was shifted to ward and discharged on 9<sup>th</sup> day successfully and advised for follow-up after two weeks, with a chest X-ray with the chest physician.



**[Table/Fig-2]:** High Resolution Computed Tomography (HRCT) thorax showing bilateral pneumothorax with right ICD in-situ.

## DISCUSSION

Spontaneous pneumothorax under general anaesthesia is one of the rarest and detrimental critical incidents in the perioperative anaesthetic management [1]. The incidence of pneumothorax is 7.4 to 18/100,000 per annum in males and 1.2 to 6/100,000 per annum in females [2]. The common causes of spontaneous pneumothorax under anaesthesia are iatrogenic ones like laparoscopic procedures and surgeries around the diaphragm or parietal pleura, emphysematous lung diseases, brachial plexus blocks, central venous cannulation, pulmonary tuberculosis, history of smoking, chronic obstructive pulmonary disease, asthma, inexperienced surgeon [1-4].

In Primary Spontaneous Pneumothorax (PSP), where there is no apparent cause, the diagnosis is misdirected/delayed due to the compounding conditions like airway obstruction, bronchospasm, erroneous right endobronchial intubation, inadequate plane of anaesthesia. The most important risk factors for development of pneumothorax under anaesthesia and in the mechanically ventilated ICU patients are, the usage of Positive Pressure Ventilation and Positive End Expiratory Pressure (PEEP) [3].

The presence of emphysematous bullae and pleural blebs may predispose to the condition. Coughing also may increase intrapleural and intrathoracic pressures up to 400 cm H<sub>2</sub>O [4]. The signs and

symptoms include sharp thoracic pain, dyspnoea, tachycardia, hypotension, decreased or absent lung sounds, reduced excursion of the affected lung and reduced pulmonary compliance. The clinical presentations under anaesthesia are elevated peak airway pressure, changes in the EtCO<sub>2</sub> and SpO<sub>2</sub> with the auscultatory changes [5]. The diagnosis of the same is generally masked by the effects of the general anaesthesia, which might lead to delayed diagnosis and additional morbidity.

In the present case, there was no risk factors for the development of pneumothorax and the suspicion was based on the clinical signs perioperatively. Even though, postoperative CT does not reveal any bullae or blebs in the present case, this would not exclude the presence of undetected small blebs or bullae [1]. The presence of the bullae would have warranted against the use of controlled positive pressure ventilation in the preoperative stage [6]. Alternatively, excess airway manipulation during the intubation can increase the risk of developing pneumothorax [1]. The pneumothorax may have developed in the present case due to acute severe bronchospasm with air trapping, causing over-pressurisation of alveoli or tension pneumothorax while manual ventilation with resistance [6]. Either of these situations can be impacted by the positive pressure ventilation, resulting in similar cardiorespiratory complications. Tidal volume (VT) of 8 mL/kg used was within the acceptable range, but it can not rule out the possibility of bullae rupture while ventilating manually or even airway handling. Irrespective of the cause, keen perioperative vigilance, early diagnosis and treatment can prevent the dangerous complications of the worsening pneumothorax.

The left small pneumothorax and pneumomediastinum in the patient was managed conservatively following a chest physician's advice and it resolved gradually within a week. Ennis SL and Dobler CC [7] and Brown SGA et al., [8] demonstrated in a multicentric study of moderate to large pneumothorax that the conservative management of PSP is a safer alternative to interventional management with fewer adverse effects, less hospital stay and early discharge. The British Thoracic Society describes that, certain asymptomatic patients with PSP can be considered for conservative management with initiation of 100% oxygen via a non rebreather mask and cardiopulmonary monitoring [2].

Pneumothorax is a potentially dangerous complication for patients with mechanical ventilation, more often in the setting of Acute Respiratory Distress Syndrome (ARDS), interstitial lung diseases, Chronic Obstructive Pulmonary Disease (COPD) and asthma. These patients are prone to develop pulmonary barotrauma, ultimately ending in pneumothorax, pneumomediastinum and subcutaneous emphysema. Optimisation of ventilator settings is the efficient strategy to prevent barotrauma and ARDS network group suggests that the goal plateau pressure to be below 35 cm H<sub>2</sub>O and ideally, below 30 cm H<sub>2</sub>O in patients with mechanical ventilation [3].

Though, the cause may not be obvious always readily, it should not exclude the presence of rare causes. Sharma M et al., described a young male with history of electronic cigarettes use, presenting with vape induced bilateral pneumonitis which progressed to right pneumothorax and was treated with right ICD insertion. He underwent bleb removal and right pleurectomy due to the presence of multiple thin walled bullae [9]. Larger PSP can be managed with Video Assisted Thoracoscopic Surgery (VATS) or thoracotomy to perform bullectomy, pleurectomy and mechanical pleurodesis [2].

The significant haemodynamic collapse during the event necessitate the need for emergency needle thoracostomy, at the second intercostal space, followed by tube thoracostomy at the fifth intercostal space and should not be delayed for the radiological confirmation. The haemodynamic stability of the patient allowed us time to do confirmation, by radiological diagnosis and treated with tube thoracostomy, later. The diagnosis of pneumothorax under anaesthesia is usually by clinical signs and symptoms, which is confirmed by chest X-ray and chest CT scans [2]. Point of Care ultrasonography (POCUS)

can be used as a portable bedside assessment tool to enhance perioperative clinical decision making [10]. The use of the structured core critical incident algorithm like cover ABCD a swift check [1] and high degree of clinical suspicion can help in early diagnosis and appropriate management. As per this algorithm, the clinical diagnosis and patient management go hand in hand.

## CONCLUSION(S)

In conclusion, despite the rare presentation, pneumothorax is potentially a dangerous complication which needs early diagnosis, clinical suspicion even without any specific risk factors and appropriate time-bound management to prevent the significant morbidities. Usage of the necessary diagnostic tools along with urgent intervention and proper communication with the team would help in the appropriate management and prevent catastrophic events.

## REFERENCES

- [1] Heyba M, Rashad A, Al-Fadhli AA. Detection and management of intraoperative pneumothorax during laparoscopic cholecystectomy. *Case Rep Anesthesiol.* 2020;2020:9273903.
- [2] Costumbrado J, Ghassemzadeh S. Spontaneous Pneumothorax. [Updated 2021 Jul 26]. In: StatPearls. Treasure Island (FL): StatPearls Publishing; 2022 Jan. Available from: <https://www.ncbi.nlm.nih.gov/books/NBK459302/>.
- [3] Diaz R, Heller D. Barotrauma and Mechanical Ventilation. [Updated 2022 May 1]. In: StatPearls. Treasure Island (FL): StatPearls Publishing; 2022 Jan. Available from: <https://www.ncbi.nlm.nih.gov/books/NBK545226/>.
- [4] Stecka AM, Grabczak EM, Michnikowski M, Zielińska-Krawczyk M, Krenke R, Gólczewski T, et al., The impact of spontaneous cough on pleural pressure changes during therapeutic thoracentesis. *Sci Rep.* 2022;12(1):11502.
- [5] McKnight CL, Burns B. Pneumothorax. 2022. In: StatPearls [Internet]. Treasure Island (FL): StatPearls Publishing; 2022.
- [6] Amaniti E, Provitsaki C, Papakonstantinou P, Tagarakis G, Sapolidis K, Dalakakis I, et al., Unexpected tension pneumothorax-hemothorax during induction of general anaesthesia. *Case Rep Anesthesiol.* 2019;2019:5017082.
- [7] Ennis SL, Dobler CC. Conservative versus interventional treatment for spontaneous pneumothorax. *Breathe (Sheff).* 2020;16(3):200171.
- [8] Brown SGA, Ball EL, Perrin K, Asha SE, Braithwaite I, Egerton-Warburton D, et al. Conservative versus interventional treatment for spontaneous pneumothorax. *N Engl J Med.* 2020;382(5):405-15.
- [9] Sharma M, Anjum H, Bulathsinghala CP, Buch M, Surani SR. A case report of secondary spontaneous pneumothorax induced by vape. *Cureus.* 2019;11(11):e6067.
- [10] Najji A, Chappidi M, Ahmed A, Monga A, Sanders J. Perioperative point-of-care ultrasound use by anesthesiologists. *Cureus.* 2021;13(5):e15217.

### PARTICULARS OF CONTRIBUTORS:

1. Senior Resident, Department of Anaesthesia, Topiwala National Medical College and B.Y.L. Nair Charitable Hospital, Mumbai, Maharashtra, India.
2. Senior Resident, Department of Anaesthesia, Topiwala National Medical College and B.Y.L. Nair Charitable Hospital, Mumbai, Maharashtra, India.
3. Associate Professor, Department of Anaesthesia, Topiwala National Medical College and B.Y.L. Nair Charitable Hospital, Mumbai, Maharashtra, India.
4. Professor, Department of Anaesthesia, Topiwala National Medical College and B.Y.L. Nair Charitable Hospital, Mumbai, Maharashtra, India.
5. Junior Resident, Department of Anaesthesia, Topiwala National Medical College and B.Y.L. Nair Charitable Hospital, Mumbai, Maharashtra, India.
6. Professor and Head, Department of Anaesthesia, Topiwala National Medical College and B.Y.L. Nair Charitable Hospital, Mumbai, Maharashtra, India.

### NAME, ADDRESS, E-MAIL ID OF THE CORRESPONDING AUTHOR:

Dr. S Mano Praveen,  
Nair Hospital, Mumbai Central, Mumbai, Maharashtra, India.  
E-mail: surya390688@gmail.com

### PLAGIARISM CHECKING METHODS: [Jain H et al.]

- Plagiarism X-checker: Jul 23, 2022
- Manual Googling: Sep 23, 2022
- iThenticate Software: Oct 14, 2022 (3%)

### ETYMOLOGY: Author Origin

### AUTHOR DECLARATION:

- Financial or Other Competing Interests: None
- Was informed consent obtained from the subjects involved in the study? Yes
- For any images presented appropriate consent has been obtained from the subjects. Yes

Date of Submission: **Jul 21, 2022**

Date of Peer Review: **Aug 27, 2022**

Date of Acceptance: **Oct 17, 2022**

Date of Publishing: **Dec 01, 2022**