

Undiagnosed Case of Ventricular Septal Defect with Eisenmenger Syndrome and Epistaxis Presentation

RAJESH NARANBHAI PANKHANIYA¹, RAHUL TANDON², BHADRA TRIVEDI³, MEGHA ANANT⁴

ABSTRACT

Eisenmenger syndrome is a rare irreversible cardiac condition as a consequence of increased Pulmonary Arterial Hypertension (PAH). This causes a reversal of flow and cyanosis. This pulmonary arterial condition developed because of unrestricted pulmonary flow. It is seen mostly in unrepaired acyanotic congenital cardiac defects with an initial left to right shunt. The common conditions are large Ventricular Septal Defect (VSD), Patent Ductus Arteriosus (PDA), Atrioventricular Septal Defect (AVSD), and atrial septal defect. The patient presented with cyanosis and worsening exertional dyspnoea due to the reversal of the shunt. It can be prevented with early diagnosis and by successfully repairing the defect. The mode of diagnosis is a good physical examination and two-dimensional (2D) echocardiography. This case report is about an 11-year-old female patient who presented with a complaint of exertional dyspnoea for five years. She had very low oxygen saturation on room air when presented in the paediatric Outpatient Department (OPD). She went for 2D echocardiography as her physical examination and laboratory investigation were not supporting any diagnosis. Her echocardiography (echo) showed large sub-aortic VSD with Eisenmenger complex and prescribed tablet Sildenafil. On the next day of admission, her dyspnoea improved, and maintained saturation without oxygen of 96-97%. She was successfully discharged and called for regular follow-up.

Keywords: Congenital heart disease, Left to right shunt, Pulmonary arterial hypertension

CASE REPORT

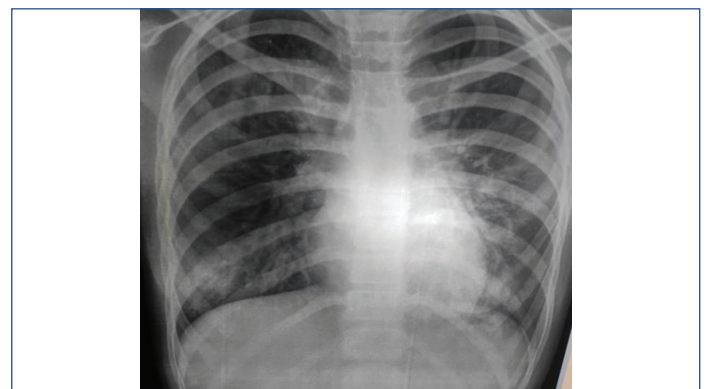
An 11-year-old female patient, presented to the paediatric OPD with a complaint of mild fever and dry cough for 7 days, abdominal pain for 5 days, and one episode of profuse bleeding from the nose 1 day before coming to the hospital. The bleeding stopped by pinching the nose. There was one episode of epistaxis from the same site one year back. It stopped by itself. There was also a complaint of hypopigmented marks in both lower limbs for which certain cream was advised by a local practitioner. There was a significant history of mild exertional dyspnoea in the last 5 years (NYHA Class 2) increase in resting dyspnoea (NYHA Class 4) since the last one year. For this complaint, the patient had not visited any doctor previously. There was also no history of nose-picking. The patient was immunised to date and studying in 6th standard. Her anthropometry was normal. No other significant family or birth history was present.

Her temperature was normal with a pulse rate was 102/min with a normal rhythm, volume, and no radio-femoral delay. Her respiratory rate was 32/min with a capillary refill time of two seconds. The jugular venous pressure was not raised and SpO₂ on room air was 85%. Her blood pressure was 120/80 mm of Hg in the right arm supine position by a manual instrument with an age-appropriate cuff.

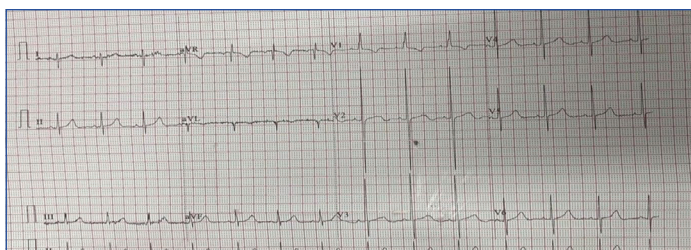
On general examination, grade 1 clubbing was present with mild cyanosis of fingers nails and lips were there. A blood-tinged spot was noticed on the lateral wall of the nose and nasal septum, and posterior pharyngeal wall. She had tachypnoea, no retraction was present, and no adventitious sound. In the cardiovascular system, only S2 in pulmonary was loud in auscultation. Per abdomen and central nervous system examinations were normal.

On admission to the ward, the patient was given supportive treatment in the form of intravenous fluid, and an injection of ceftriaxone after a blood culture. An oxygen mask of 4 litres of oxygen was provided, on which she was maintaining a saturation of 97%. Laboratory investigation showed Haemoglobin (Hb)-14.8 gm%, Total Leucocyte Count (TLC)-14200 mm³, Differential Leucocyte Count (DLC)-76/20/1/3/0, Platelet count-217000 mcL, Urea-30 mg/dL, Serum

creatinine-0.55 mg/dL, Na-135 meq/l, K-4.1 meq/l, Prothrombin Time (PT)/International Normalised Ratio (INR)-15.1/1.28, activated Partial Thromboplastin clotting Time (aPTT)-27.28, Erythrocyte Sedimentation Rate (ESR)-25 mm, C-Reactive Protein (CRP)-13.5 mg/L, Serum Glutamic Pyruvic Transaminase (SGPT)-18 u/L. Postero-anterior (PA) chest radiograph view showed pulmonary vessel congestion in the perihilar region. No active parenchymal lesions in both bilateral lung fields were seen. Initially, it was thought of nasal obstruction due to blood, causing low oxygen saturation, so nasal saline drops were also advised. For this, Ear Nose Throat (ENT) consultant reference was also done to rule out any nasopharyngeal lesion caused for epistaxis or any obstruction. They performed nasal endoscopy which came normal. The ENT surgeon's finding and the chest radiograph were inconclusive [Table/Fig-1] and the patient need oxygen support which was not explained by any lung pathology with Hb of 14.8 gm%, 2D Echo and Electrocardiography (ECG) was planned. A 2D echocardiography showed large sub-aortic VSD shunting bidirectional with a right atrium and right ventricle was dilated. ECG revealed right axis deviation [Table/Fig-2]. There was severe pulmonary artery hypertension. So, a diagnosis of Eisenmenger complex with reversal of shunt through VSD with fixed pulmonary vascular resistance not within an operable range was made.



[Table/Fig-1]: Chest X-ray (PA view) showing perihilar pulmonary vessel congestion.



[Table/Fig-2]: Electrocardiography (ECG) showing right axis deviation.

She was started on Tablet Sildenafil 20 mg thrice a day, advice to avoid exertion, and call for regular follow-up after discharge on the next day. A dermatologist reference was also done for a white spot in both lower limbs, diagnosed as vitiligo advice medicine for it and regular follow-up. After 1 month of discharge, the child came for a follow-up in paediatric OPD. Her exertional dyspnoea had reduced and she maintained a saturation of 96% on room air.

DISCUSSION

This condition was first seen by an Austrian medical doctor named Viktor Eisenmenger in his 32-year-old patient born with a VSD. The patient presented with complaints of cyanosis and dyspnoea. This patient died due to massive haemoptysis [1]. Later another doctor named Paul Wood described this condition in an unrepaired VSD and coined the condition as Eisenmenger complex [1]. In lower middle-income countries like south-east Asian countries, due to a lack of a sufficient number of paediatric cardiologists or not having advance cardiac centres as per population strength may present with late undiagnosed congenital cardiac lesions with elevated pulmonary vascular resistance as in this index case [2]. Eisenmenger syndrome or complex also predisposes bleeding and thrombosis in the patient. It is postulated and seen that there is a platelets and clotting factors dysfunction in this condition [3,4].

The bleeding mostly presents as epistaxis and sometimes in form of haemoptysis [3,4]. The index patient also presented with the complaint of profuse bleeding from the right-side of the nose two times before admission. Not much literature is available about epistaxis in the Eisenmenger complex in the paediatric age group. It may be a coincidental finding. Recently, one case of massive epistaxis in a 35-year-old female with PDA and Eisenmenger syndrome was reported [5]. In mild to moderate VSD, only 3% of patients develop this condition in the long-term as compared to 50% in large VSD patients if untreated [6]. In other conditions like an atrial septal defect, only 10% chances are there. Patients with unrepaired VSD and PDA present early with the symptoms of this condition [6]. Medical management is only supportive by giving treatment for this irreversible condition. The most common drugs used are prostacyclin and endothelin antagonists or phosphodiesterase inhibitors 5 [7-9]. Other managements are avoiding exertion in form of exercise, maintaining hygiene to prevent infection, avoiding high altitudes, and proper vaccination, especially in child age group patients. Also,

proper follow-up of the patient with a paediatric cardiologist once the disease is diagnosed. One review article mentions operative intervention in structural reversible pulmonary vascular disease in Eisenmenger syndrome after giving endothelin receptor antagonists, phosphodiesterase type-5 inhibitors, prostacyclin, and prostacyclin analogs like drugs [10]. In most cases heart lung transplant is needed and those who fail drug treatment. So, this is the case of a patient with atypical presentation as epistaxis not common in this age group for this rare cardiac condition.

CONCLUSION(S)

If exertional dyspnoea is present in children of any age group, then utmost importance should be given to its clinical history, so that the paediatrician does not miss Eisenmenger's complex condition and an early referral can be initiated. The absence of a murmur does not rule out congenital heart disease as in the Eisenmenger complex where pressure equalises in both ventricles. So, need for a good general physical examination along with supportive laboratory investigation and 2D echo for diagnosis of rare heart complications due to undiagnosed Congenital Heart Disease (CHD). Treatment with Sildenafil drug only improves the prognosis and quality of life of those cases with VSD, as the case reported. Despite the treatment, the survival of these patients remains unsatisfactory. Additional therapeutic strategies are to be targeted to improve the symptoms.

REFERENCES

- [1] Hjortshoj CM, Kempny A, Jensen AS, Sorensen K, Nagy E, Dellborg M, et al. Past and current cause-specific mortality in Eisenmenger syndrome. *European Heart Journal*. 2017;38(26):2060-67.
- [2] Ramineni HB, Jammula P, Mukiri S, Suryadevara V. Eisenmenger syndrome in a patient with a ventricular septal defect: A case report. *International Journal of Research in Medical Sciences*. 2015;3(1):376.
- [3] Lui GK, Saidi A, Bhatt AB, Burchill LJ, Deen JF, Earing MG, et al. Diagnosis and management of noncardiac complications in adults with congenital heart disease: A scientific statement from the American Heart Association. *Circulation*. 2017;136(20):e348-92.
- [4] Remkova A, Simkova I, Valkovicova T, Kaldararova M. Platelet abnormalities in adults with severe pulmonary arterial hypertension related to congenital heart defects (Eisenmenger syndrome). *Blood Coagulation & Fibrinolysis*. 2016;27(8):925-29.
- [5] Liu A, Saman H, Pusalkar P. Massive epistaxis in a patient with Eisenmenger syndrome: Illustrating the clot-versus-bleed conundrum. *Case Reports*. 2011;2011:bcr0220113812.
- [6] D'Alto M, Mahadevan VS. Pulmonary arterial hypertension associated with congenital heart disease. *European Respiratory Review*. 2012;21(126):328-37.
- [7] Diller GP, Lammers AE, Oechslin E. Treatment of adults with Eisenmenger syndrome—state of the art in the 21st century: A short overview. *Cardiovascular Diagnosis and Therapy*. 2021;11(4):1190.
- [8] Diller GP, Korten MA, Bauer UM, Miera O, Tutarel O, Kaemmerer H, et al. Current therapy and outcome of Eisenmenger syndrome: Data of the German National Register for congenital heart defects. *European Heart Journal*. 2016;37(18):1449-55.
- [9] Frank DB, Hanna BD. Pulmonary arterial hypertension associated with congenital heart disease and Eisenmenger syndrome: Current practice in pediatrics. *Minerva Pediatrica*. 2015;67(2):169.
- [10] Huang JB, Liang J, Zhou LY. Eisenmenger syndrome: Not always inoperable. *Respiratory Care*. 2012;57(9):1488-95.

PARTICULARS OF CONTRIBUTORS:

1. Assistant Professor, Department of Paediatric, Pramukh Swami Medical College, Bhaikaka University, Karamsad, Anand, Gujarat, India.
2. Senior Resident, Department of Paediatric, Pramukh Swami Medical College, Bhaikaka University, Karamsad, Anand, Gujarat, India.
3. Associate Professor and Paediatric Cardiologist, Department of Paediatric, Pramukh Swami Medical College, Bhaikaka University, Karamsad, Anand, Gujarat, India.
4. Resident (3rd Year), Department of Paediatric, Pramukh Swami Medical College, Bhaikaka University, Karamsad, Anand, Gujarat, India.

NAME, ADDRESS, E-MAIL ID OF THE CORRESPONDING AUTHOR:

Rahul Tandon,
E-702, Sahjanand Status, Opposite GMM, Anand Sojitra Road, Karamsad,
Anand, Gujarat, India.
E-mail: tandonrahul73@gmail.com

AUTHOR DECLARATION:

- Financial or Other Competing Interests: None
- Was informed consent obtained from the subjects involved in the study? Yes
- For any images presented appropriate consent has been obtained from the subjects. Yes

PLAGIARISM CHECKING METHODS: [Jain H et al.]

- Plagiarism X-checker: Aug 13, 2022
- Manual Googling: Oct 15, 2022
- iThenticate Software: Nov 15, 2022 (8%)

ETYMOLOGY: Author Origin

Date of Submission: **Aug 10, 2022**
Date of Peer Review: **Sep 28, 2022**
Date of Acceptance: **Nov 19, 2022**
Date of Publishing: **Jan 01, 2023**