

# Variations in Superficial Veins of Neck among Population of Eastern India in the Light of Embryological Explanation: A Cadaveric Cross-sectional Study

SUSMITA GHOSH<sup>1</sup>, ANUP SHYAMAL<sup>2</sup>, MITHU PAUL<sup>3</sup>, OYNDRILA SENGUPTA<sup>4</sup>, SIBANI MAZUMDAR<sup>5</sup>



## ABSTRACT

**Introduction:** Development of veins of head and neck is complex. Variations in the venous architecture of head and neck includes persistence or complete obliteration of communication between Internal Jugular Vein (IJV) and External Jugular Vein (EJV) and also partial obliteration in EJV. Knowledge of variations in venous architecture is beneficial to avoid injuries to these veins during interventions like EJV cannulation for diagnostic and therapeutic purposes.

**Aim:** To study the variations in the venous architecture of the neck in the cadavers.

**Materials and Methods:** This descriptive cross-sectional study was conducted in the Department of Anatomy, Calcutta National Medical College, Kolkata, West Bengal, India during December 2017 to December 2019. Total 26 specimens of both male and female cadavers were dissected, and variations in the venous

architecture was noted, also each variation was explained in the light of embryology.

**Results:** Retromandibular Vein (RMV) was found to be undivided in all 10 of the variations found in the eight male and two female cadavers. EJV was found to be absent in one specimen among 26 dissected. Communication between IJV and EJV was found in one specimen. In another specimen, EJV was found to be draining into IJV which can be embryologically seen as a communication between IJV and EJV while the caudal part of EJV had degenerated.

**Conclusion:** Undivided RMV, particularly absent posterior division is not very uncommon in male and female in this ethnicity. Absence of common facial vein was more common in male as compared to female. Persistent communication between EJV and IJV were also more in male. Moreover occurrence of facial vein drainage into EJV was also remarkably high.

**Keywords:** Ethnicity, External jugular vein, Facial vein, Retromandibular vein, Vein communication

## INTRODUCTION

During performing dissection of cadavers for undergraduate students it is found that the Facial Vein (FV) joins with the anterior division of RMV to form the Common Facial Vein (CFV) which drains into the IJV. When RMV remains undivided and joins facial vein, then also the vein formed is called the CFV. It is also seen that in cases of undivided RMV, it most often continues as EJV. But, EJV may be absent, when undivided RMV joins with FV to form the common trunk of CFV to drain into IJV [1].

Undivided RMV were found in 0.01% of specimen in a study by Pai M et al., [2]. Bertha A and Suganthy R comments that in cases of RMV without any divisions, RMV mostly continues as EJV [3]. Absence of RMV was reported by Patil J et al., in a specimen instead, the maxillary vein was divided into anterior and posterior divisions [4]. Sometimes communications may persist between CFV and EJV or EJV and IJV. EJV may even be completely absent [5].

Exploring the formation of RMV by dissection is an area not much cultivated. Variations in the termination of Anterior Jugular Vein (AJV) are also area to be explored. Keeping all these variations in mind and also the importance of all these variations in head and neck surgery it is evident that there is huge scope of many more to be explored by dissection. Hence, present study was conducted to study the variations in the venous architecture of the neck in the cadavers.

## MATERIALS AND METHODS

This descriptive cross-sectional study was conducted in the Department of Anatomy, Calcutta National Medical College, Kolkata, West Bengal, India, from December 2017 to December 2019. As the study was carried out on cadavers, from voluntarily

donated bodies in the Department of Anatomy, examination of any organ or, structure for academic purpose is permitted, according to the prevailing laws of the land. Hence, no further consent was necessary.

**Inclusion criteria:** Both male and female adult cadavers, aged above 60 years were included in the study. The dissection was done on both sides of the neck of voluntarily donated preserved cadavers.

**Exclusion criteria:** Cadavers having any neck injury, diseases of neck were excluded from the study.

**Sample size:** A total of 26 specimens were dissected among which, there were 9 male (left-side), 9 male (right-side), 4 female (left-side), 4 female (right-side).

## Data Collection

During routine dissection of voluntarily donated human cadavers for conducting undergraduate class the neck veins were dissected. Neck was extended with support and fixed in position for proper exposure. Wooden block, rope, dissecting toothed and non toothed forceps, scissors, scalpel were used for this purpose. In case of any variation regarding the neck vein formation, tributaries or termination were documented by taking pictures.

## Operational Definitions

- External Jugular Vein (EJV):** Formed by posterior division of RMV and the posterior auricular vein, and drains into the subclavian vein of same side. Receives cervical, suprascapular and AJV [6-8].
- Common Facial Vein (CFV):** Formed by facial vein and the anterior division of RMV and drains into the IJV [7,8].

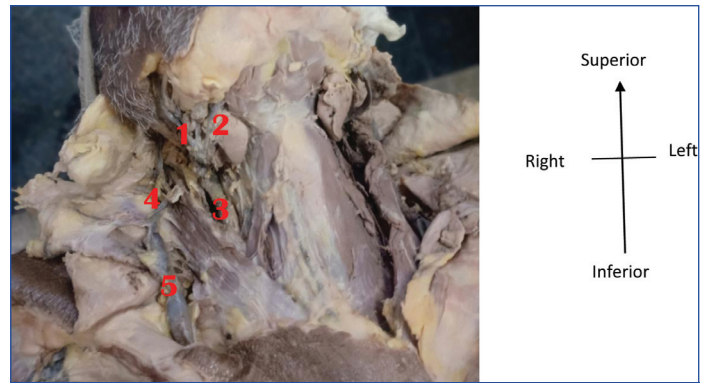
- Retromandibular Vein (RMV):** Formed by union of superficial temporal and maxillary veins and terminates by dividing into anterior and posterior divisions in the anterior triangle of neck [7,8].
- Facial Vein (FV):** Formed by continuity of the angular vein at the medial canthus of the eye and drains into the IJV after forming CFV [7,8].

**STATISTICAL ANALYSIS**

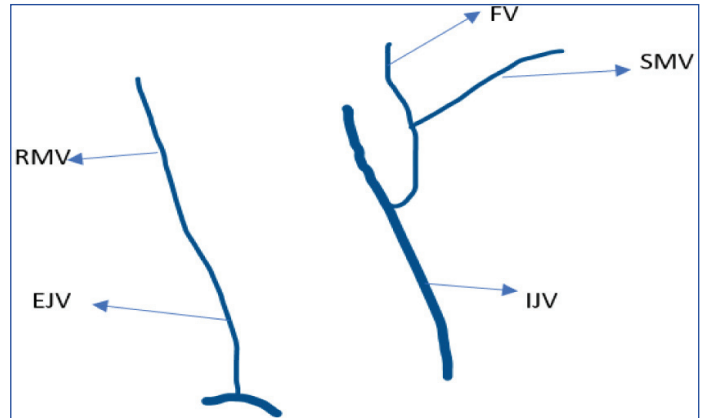
The variations were documented in Microsoft excel sheet and their proportions was calculated in the both male and female subgroups in terms of number and percentage.

**RESULTS**

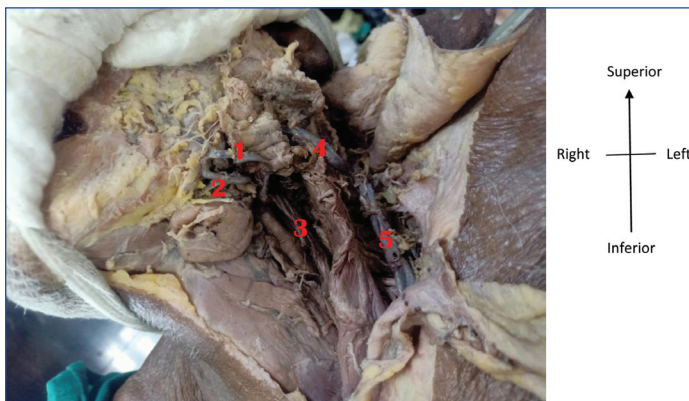A total of 26 specimens were dissected among which variations in venous architecture was found in 10 specimens among which eight were males (4 left, 4 right) and two were female specimen (1 left, 1 right). All had undivided RMV along with other associated variations. One male specimen had bilaterally absent CFV [Table/Fig-1a,b,2a,b]. Presence of communication between EJV and IJV was also found bilaterally in another male specimen [Table/Fig-3a,b,4a,b]. Rest all variations were unilateral. Among all the specimens, in eight male specimens undivided RMV was found to be continuing as EJV, and the CFV was found to be absent in six of them [Table/Fig-5-11].



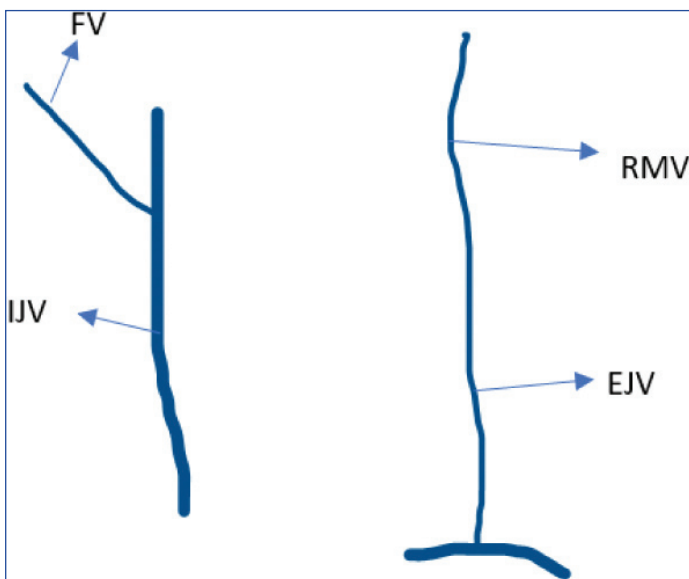
**[Table/Fig-2a]:** Undivided RMV with FV draining into IJV (Male, Right). 1) FV, 2) SMV, 3) IJV, 4) RMV, 5) EJV.



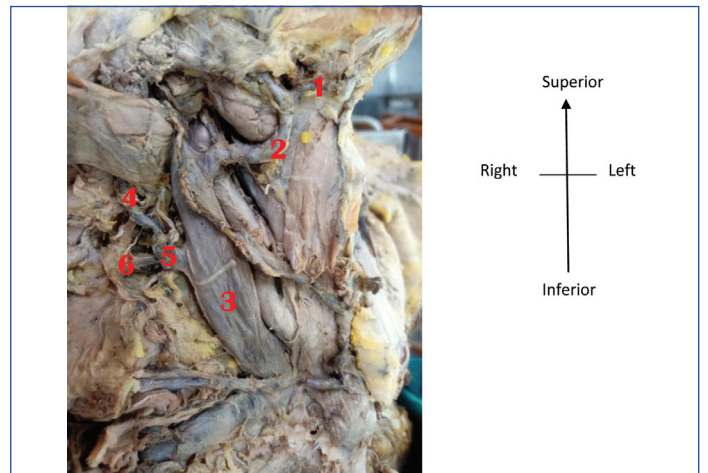
**[Table/Fig-2b]:** Undivided RMV with FV draining into IJV. Anterior division of RMV obliterates on right-side. Posterior division joins EJV. FV drains into IJV and has no communication with anterior division of RMV, this anterior division and communication degenerate



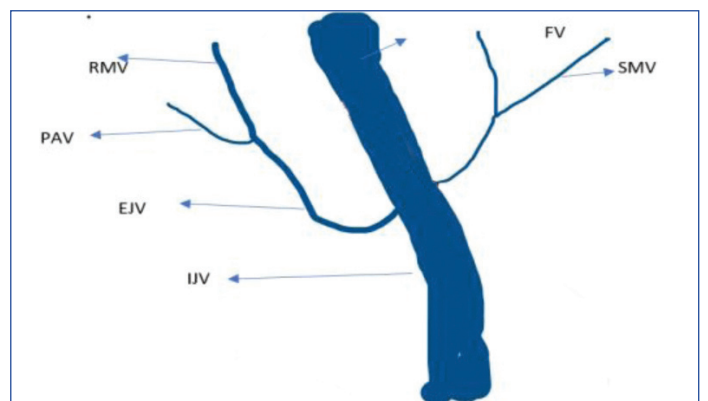
**[Table/Fig-1a]:** Undivided RMV with FV draining into IJV (Male, Left). 1) FV, 2) SMV, 3) IJV, 4) RMV, 5) EJV.



**[Table/Fig-1b]:** Undivided RMV with FV draining into IJV (Schematic representation). Anterior division of RMV obliterates. Posterior division joins EJV. FV communicates IJV, and has no communication with anterior division of RMV, this anterior division degenerates

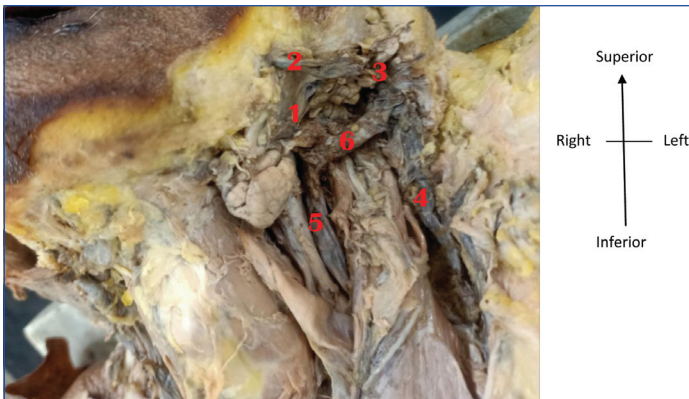


**[Table/Fig-3a]:** EJV draining into IJV (Male, Right). 1) SMV, 2) FV, 3) IJV, 4) RMV, 5) EJV, 6) PAV.

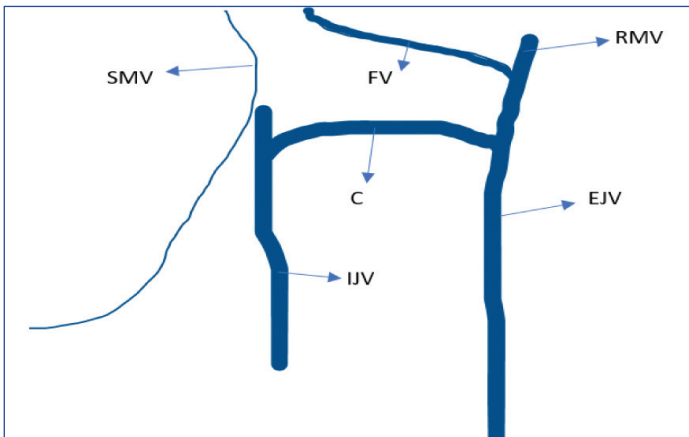


**[Table/Fig-3b]:** EJV draining into IJV (Schematic representation). Caudal part of EJV obliterates. Via the communication, EJV drains into IJV. EJV, in its cephalic part receives posterior division of RMV, which in turn receives PAV. Anterior division of RMV obliterates. So, FV drains into IJV without forming CFV. Communication nc obliterates; nc: New communication

The EJV was absent in one female specimen [Table/Fig-5,10a,12]. In this study 10 (38.5%) undivided RMV was found with equal incidence on either side (5 on left and 5 on right) [Table/Fig-13],



**[Table/Fig-4a]:** Persistent communication between IJV and EJV (Male, Left). 1) FV, 2) RMV, 3) CFV, 4) EJV, 5) IJV, 6) Communication between EJV and IJV.




**[Table/Fig-4b]:** Persistent communication between IJV and EJV (Schematic representation).

Posterior division of RMV and cephalic part of EJV obliterate, hence no PAV. FV joins with anterior division of RMV to form CFV which through communication nc drains into EJV, but loses connection with IJV. However, in the caudal part, EJV is connected with IJV by the communication ac which persists as a transverse communication between IJV and EJV in adult life; ac: Anterior communication, nc: New communication

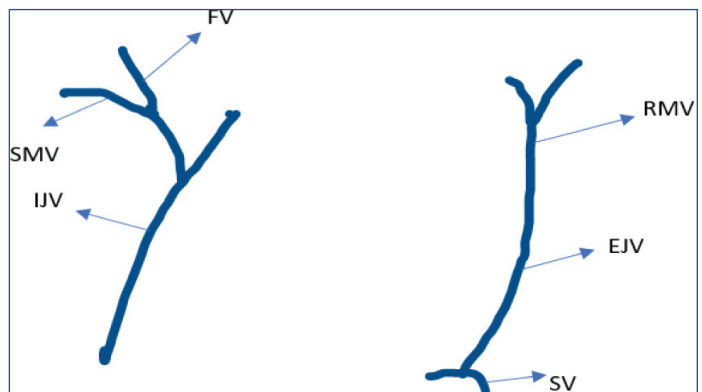
Specimen No.	Gender and side	EJV	RMV	CFV	FV	Communication between IJV and EJV
1. [Table/Fig-6a]	M/Left	Continuation of RMV	Undivided, No Anterior Division	Absent	Drains in IJV	None
2. [Table/Fig-7a]	M/Right	Continuation of RMV	Undivided, No Anterior Division	Absent	Drains in IJV	None
3. [Table/Fig-8a]	M/Left	Continuation of CFV	Undivided, No Posterior Division	Present	Joins with undivided RMV	None
4. [Table/Fig-9a]	F/Left	Continuation of CFV	Undivided, No Posterior Division	Present	Joins with undivided RMV	None
5. [Table/Fig-10a]	F/Right	Absent	Undivided, No Posterior Division	Present	Joins with undivided RMV	None
6. [Table/Fig-11a]	M/Right	Continuation of RMV	Undivided, No Anterior Division	Absent	Drains in IJV	None
7. [Table/Fig-1a]	M/Left	Continuation of RMV	Undivided, No Anterior Division	Absent	Drains in IJV	None
8. [Table/Fig-2a]	M/Right	Continuation of RMV	Undivided, No Anterior Division	Absent	Drains in IJV	None

9. [Table/Fig-3a]	M/Right	Continuation of RMV EJV appears to drain into IJV	Undivided, No Anterior Division	Absent	Drains in IJV	Present
10. [Table/Fig-4a]	M/Left	Continuation of CFV	Undivided, No Posterior Division	Present	Joins with undivided RMV	Present

**[Table/Fig-5]:** Specimens with variations.

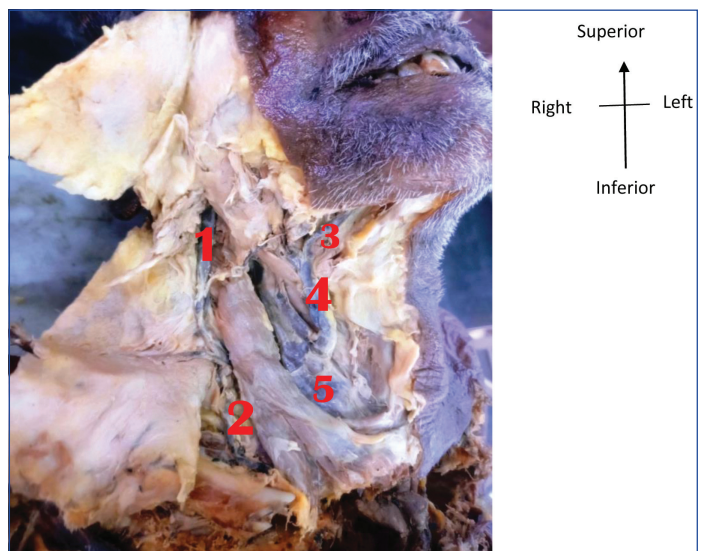


**[Table/Fig-6a]:** Undivided RMV with FV draining into IJV (Male, Left). 1) FV, 2) IJV, 3) RMV, 4) EJV.

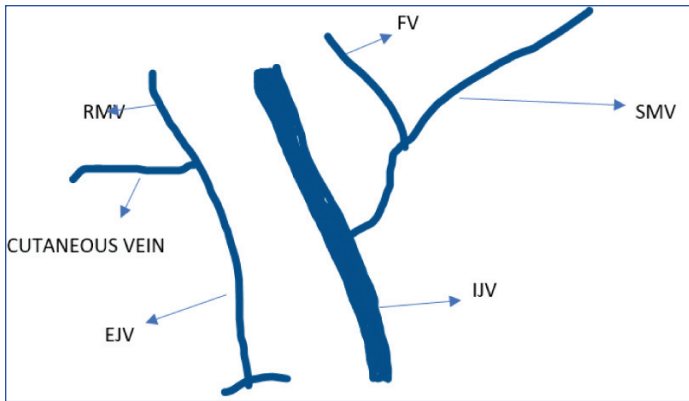


**[Table/Fig-6b]:** Undivided RMV with FV draining into IJV.

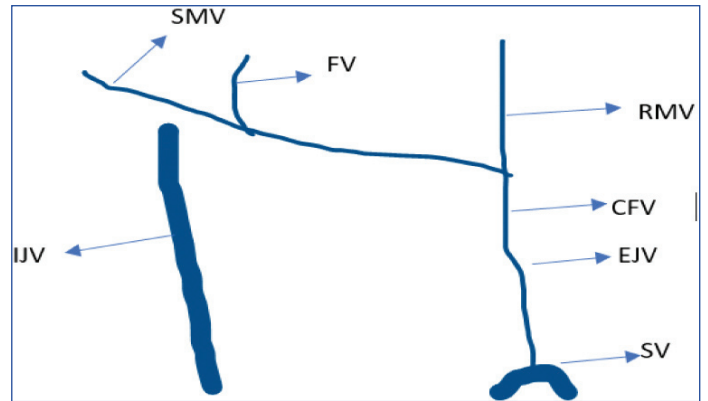
Showing Anterior division of RMV degenerates and posterior division of RMV continues with EJV. PAV is absent and communications between FV or IJV and EJV persist



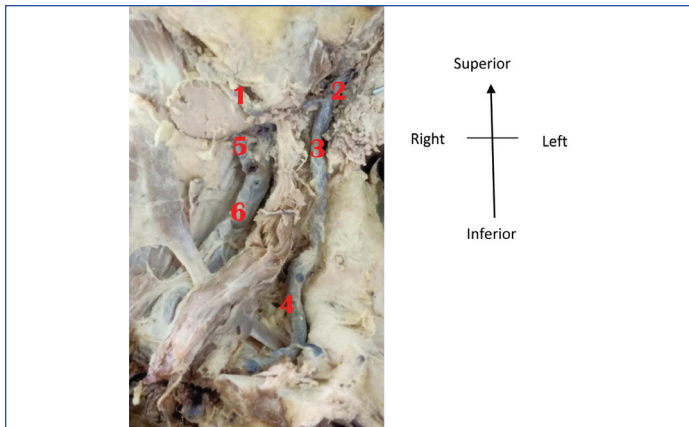
**[Table/Fig-7a]:** Undivided RMV continuing as EJV with FV draining into a thick IJV (Male, Right). 1) RMV, 2) EJV, 3) SMV, 4) FV, 5) IJV.



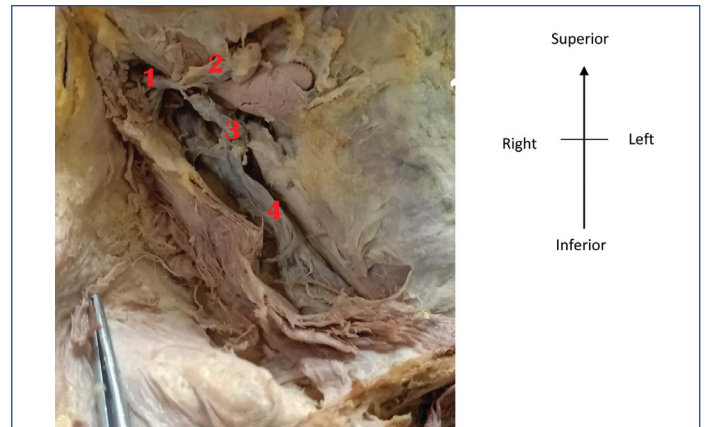
**[Table/Fig-7b]:** Undivided RMV continuing as EJV with FV draining into a thick IJV (Schematic representation). Showing RMV has only posterior division. PAV communication is absent. Anterior division of RMV degenerates, so there is no communication between RMV and FV. Anterior and posterior communications between IJV and EJV degenerate



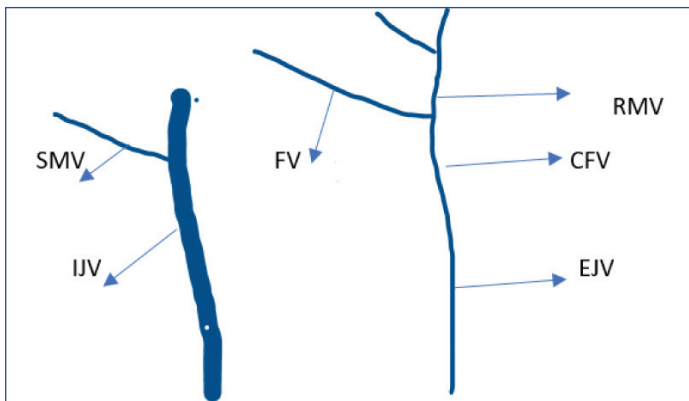
**[Table/Fig-9b]:** FV draining into undivided RMV continuing as EJV (Schematic representation). Anterior division of RMV persists to join FV, to which SMV has already drained. CFV, through new extra communication drains into EJV instead of IJV. CFV loses its contact with IJV. The cephalic part of EJV disappears, having no posterior division of RMV to drain into it



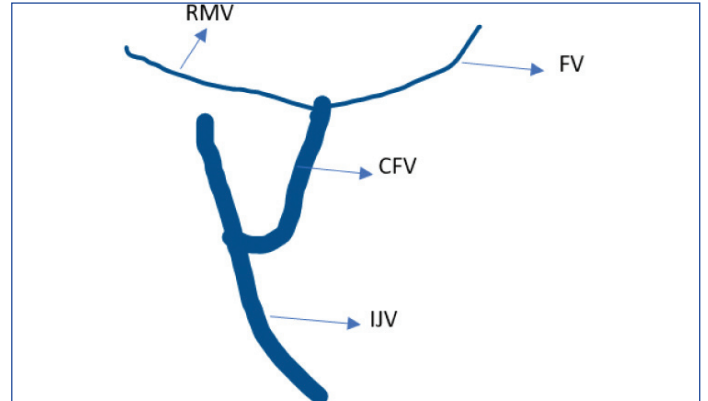
**[Table/Fig-8a]:** FV draining into undivided RMV continuing as EJV (Male, Left). 1) FV, 2) RMV, 3) CFV, 4) EJV, 5) SMV, 6) IJV.



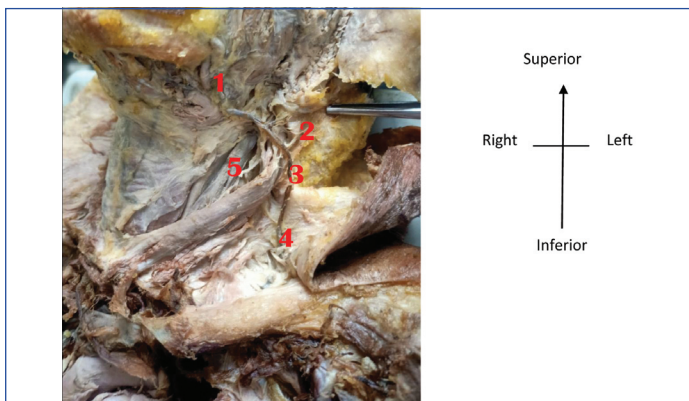
**[Table/Fig-10a]:** Absent EJV undivided RMV continuing as IJV (Female, Right). 1) Undivided RMV, 2) FV, 3) CFV, 4) IJV.



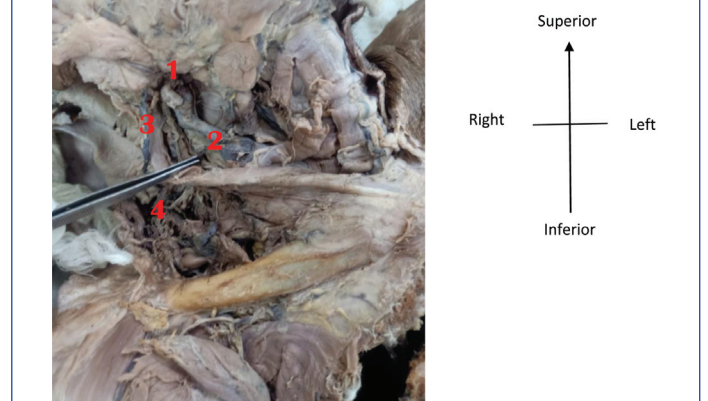
**[Table/Fig-8b]:** FV draining into undivided RMV continuing as EJV (Schematic representation). No PAV communication present as posterior division of RMV is absent. Cephalic part of EJV degenerates. Anterior division of RMV joins with FV to form CFV which communicates with EJV through extra communication. SMV however independently drains into IJV without draining into FV




**[Table/Fig-10b]:** Absent EJV undivided RMV continuing as IJV (Schematic representation). Anterior division of RMV persists; unites with FV to form CFV and IJV. There is no posterior division of RMV. Whole of EJV obliterates



**[Table/Fig-9a]:** FV draining into undivided RMV continuing as EJV (Female, Left). 1) FV, 2) RMV, 3) CFV, 4) EJV, 5) IJV.



**[Table/Fig-11a]:** Undivided RMV with FV draining into IJV (Male, Right). 1) FV, 2) IJV, 3) RMV, 4) EJV.



**[Table/Fig-11b]:** Undivided RMV with FV draining into IJV (Schematic Representation). Posterior division of RMV persists to drain into EJV. Anterior division of RMV fails to communicate with FV and degenerates. No anterior or new communication persists

where FV was not united with anterior division of RMV no CFV was formed. Absence of CFV was found in 6 (23.1%) of this study population (3 left and 3 right) [Table/Fig-14]. EJV was found to be absent in 3.85% of the sample. Communication between EJV and IJV was found in 2 (7.7%) cases (1 left and 1 right) [Table/Fig-4a,5,10a].

Side	EJV present		Absent EJV		EJV connected with IJV	
	RT	LT	RT	LT	RT	LT
Male	9	9	0	0	1 (11.1%)	1 (11.1%)
Female	3	4	1 (25%)	0	0	0
Total	12	13	1(25%)	0	1 (11.1%)	1 (11.1%)

**[Table/Fig-12]:** Different variations in EJV.

Side	RMV present (26)		RMV absent (0)		Number of undivided RMV anterior division (7)		Number of undivided RMV posterior division (3)		Drains into IJV	
	Rt	Lt	Rt	Lt	Rt	Lt	Rt	Lt	Rt	Lt
Male	9	9	0	0	4 (44.4%)	3 (33.3%)	0	1 (22.2%)	0	0
Female	4	4	0	0	0	0	1 (25%)	1 (25%)	1 (25%)	0
Total	13	13	0	0	4	3	1	2	1	0

**[Table/Fig-13]:** Different variations in RMV (variation found in 10 specimen i.e., 38.5%).

Gender	CFV present (20)		CFV absent (6)		Drains in IJV		Drains in EJV	
	Rt	Lt	Rt	Lt	Rt	Lt	Rt	Lt
Male	6 (46.2%)	6 (46.2%)	3 (23.1%)	3 (23.1%)	6 (46.2%)	4 (30.8%)	0	2 (15.4%)
Female	4 (30.8%)	4 (30.8%)	0	0	4 (30.8%)	3 (23.1%)	0	1 (7.7%)

**[Table/Fig-14]:** Different variations in CFV (Total 26 specimens).

The FV joined with undivided RMV to form CFV and continued as EJV in one male specimen [Table/Fig-4a,12]. In 2 (22.2%) of male left-sided specimen FV found to drain into EJV without joining with RMV. In female the same occurred in 1 (25%) but after joining with RMV [Table/Fig-15]. In two male specimens communication between EJV and IJV were found [Table/Fig-3a,4a,5,12]. In one male specimen EJV was found to drain into IJV [Table/Fig-3a]. Embryologically the anterior connection (ac) between EJV and IJV persist while the part of EJV distal to the communication obliterates. Hence, EJV has drained into IJV through its communication.

Gender	FV Present		FV Absent		Does not join With RMV		Drains into EJV		Drains into IJV	
	Rt	Lt	Rt	Lt	Rt	Lt	Rt	Lt	Rt	Lt
Male	9	9	0	0	4 (44.4%)	2 (22.2%)	0	2 (22.2%)	9	7 (77.8%)
Female	4	4	0	0	0	0	0	1 (25%)	4	3 (75%)

**[Table/Fig-15]:** Variations in FV (Total 26 specimen).

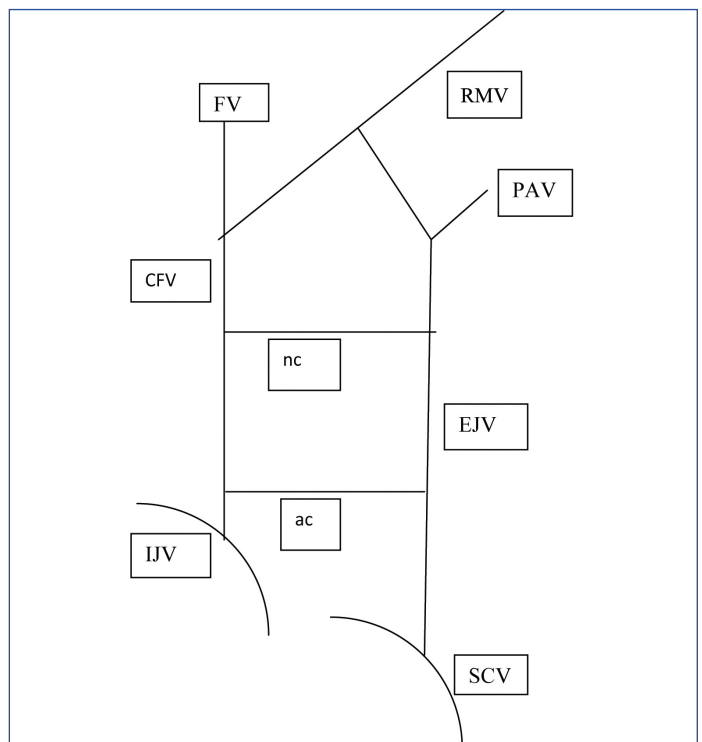
## DISCUSSION

Knowledge of variations and persisting communications help in avoidance of injuries to the veins during interventions like EJV cannulation for diagnostic and therapeutic purposes including monitoring of Central Venous Pressure (CVP) [9]. Transjugular liver biopsy and postsystemic shunts have also been tried through this route. CFV is used as a patch material for carotid angioplasty and in ventriculo-jugular shunts as a treatment of hydrocephalus [10]. Knowledge of superficial veins of neck prevents injuries of interventional procedures or during neck surgeries [11].

Ultrasound-guided venepuncture can avoid trauma related to variations in venous architecture. Grafting of these veins is also utilised in microvascular anastomosis in oral reconstruction surgeries [8]. Venous segments are used as patches in carotid endarterectomies. The superficial course of EJV makes it easier than the IJV to be accessed with a venous manometer [9]. EJV is also used in catheterisation for performing haemodialysis [10]. RMV can be used as a guide to identify the facial nerve branches during parotid surgeries and open reductions of mandibular condylar fractures [11]. The RMV is an important anatomical guide in radiology where it is used to localise a tumour in the parotid gland in relation to the facial nerve and in surgery as a landmark to dissect the facial nerve and its branches [11].

**Embryological explanation:** Development of the veins of head and neck undergo a complex pattern and are only apparent after the development of skull [3]. The ventral pharyngeal vein, which opens into the precardinal vein (the future IJV) develops early. Then, it receives a tributary called linguo-facial vein (finally becoming the facial vein), draining face and tongue. RMV, which is considerably large vein, develops draining blood from the temporal region into the linguo-facial vein. The common trunk called CFV drains into the precardinal vein. The preaxial vein of the upper limb which in future will form the cephalic vein, receives EJV, draining tissues of the neck. The finally formed EJV drains into the SCV [7].

The EJV communicates in front (ac in [Table/Fig-16]) with terminal part of the developing CFV or into the precardinal vein and posteriorly (new communication (nc) in [Table/Fig-16]) with the RMV. PAV opens in the posterior communication which in future appears



**[Table/Fig-16]:** Schematic representation of the embryological basis of the superficial neck veins and their communications. FV: Facial vein; RMV: Retromandibular vein; PAV: Posterior auricular vein; EJV: External jugular vein; IJV: Internal jugular vein; SCV: Subclavian vein; ac: Anterior communication, nc: New communication

to be the posterior division of the RMV, thus in future forming the EJV. The initially formed RMV becomes the anterior division of future RMV, which joins with the FV, to form CFV. Sometimes, if in early developmental stages, cephalic part of EJV may disappear [3], an extra communication arises between CFV and caudal part of EJV. Then there may be no posterior communication with RMV, and PAV has to open in the undivided RMV. The pathway of venous drainage then is as follows: undivided RMV → joins with FV → CFV → opens into caudal part of EJV (segment of CFV draining into precardinal or IJV disappears) via the extra communication (nc) → SV. All the variations cited in this article are cited in the light of this embryological explanation.

From above explanation by the term undivided RMV, authors thus assume, developmentally in due course of time, either anterior or posterior division got obliterated. The presence of anterior or posterior division as mentioned in the specimens of variation, are embryological explanations where undivided RMVs are detected. Authors assume that where RMV has joined with FV, it may be considered to persist its anterior division (as anterior division meets FV to form CFV), irrespective of its drainage into either EJV or IJV. But undivided RMVs which have no connection with FV, may be considered to persist with posterior divisions with anterior divisions obliterated (as posterior division of RMV joins with PAV), which drain into EJV mostly but may drain into IJV through persisting communication between IJV and EJV [12,13].

All 10 specimen had undivided RMV along with other associated variations [Table/Fig-1b-4b,6b-11b]. The possible embryological explanation of the 10 cases that were found with variations are:

Specimen 1-SMV drains into FV which does not communicate with anterior division of RMV. The anterior division of RMV thus degenerates. Posterior division of RMV continues with the EJV. PAV is absent and FV drains into IJV. Communications between FV or IJV and EJV do not persist [Table/Fig-6b].

Specimen 2-RMV has only posterior division which joins with EJV. PAV is absent. Anterior division of RMV degenerates, so communication between RMV and FV, CFV is not formed. FV drains directly into IJV. Anterior and posterior communications between IJV/CFV (which is not formed at all) and EJV degenerate [Table/Fig-7b].

Specimen 6-Posterior division of RMV drains into EJV. Anterior division of RMV does not communicate with FV and degenerates. FV drains into IJV and no anterior or new communication persists [Table/Fig-11b].

Specimen 7 and 8-Anterior division of RMV obliterates and posterior division joins EJV. FV drains into IJV and has no communication with anterior division of RMV. This anterior division degenerates [Table/Fig-2b].

So in present study anterior division of RMV was absent in 44.4% and 33.3% of male specimen on right and left-sides, respectively. On the other hand posterior division of RMV were absent in 22.2% of left-side in male and 25% on either sides of female specimen. Bertha A and Suganthy R comments that in cases of RMV without any divisions, RMV mostly continues as EJV [3]. Rao YL et al., had cited undivided RMV associated with absence of EJV and common trunk of RMV and FV draining into IJV [1]. CFV was absent in

23.1% of either side of male specimen. On left-side CFV drain into EJV in 7.7% of female and 15.4% of male [Table/Fig-14]. Arquez HF and Torres SIG in their study during 2013 to 2017 found that right common facial vein (3%) was draining into the contralateral pericardiophrenic vein and internal thoracic vein on one side. They also found remarkable communications with the EJV, the IJV, the anterior jugular vein, and left brachiocephalic vein [13].

Specimen 3-PAV does not drain as posterior division of RMV. Thus, cephalic part of EJV degenerates and anterior division of RMV joins with FV to form CFV which communicates with EJV through extra communication. SMV however independently drains into IJV without draining into FV [Table/Fig-8b].

Specimen 4-The anterior division of RMV persists to join FV, to which SMV has already communicated. CFV, which is formed of joining to FV and anterior division of RMV, through extra communication (nc) drains into EJV instead of IJV. CFV loses its contact with IJV. The cephalic part of EJV disappears, having no posterior division of RMV to drain into it [Table/Fig-9b].

Specimen 10-Posterior division of RMV and cephalic part of EJV obliterate. FV joins with anterior division of RMV to form CFV which through new communication drains into EJV, but loses connection with IJV. However, in the caudal part, EJV is connected with IJV by the communication which persists as a transverse communication between IJV and EJV in adult life [Table/Fig-4b].

Unusual drainage of the CFV into the EJV on left-side in two specimen and right-side in one specimen were observed by Bertha A and Suganthy R [3]. Among male specimen 44.4% on right-side and 22.2% on left-side FV did not join with RMV, drained into IJV. A 22.2% on left-side of male and 25% on left-side of female specimen the FV drained into EJV [Table/Fig-15].

Specimen 5-Anterior division of RMV unites with FV to form CFV which drains into IJV. There is no posterior division of RMV and in this case the whole of EJV obliterates as no vein drains into it [Table/Fig-10b].

Among all the specimen from female EJV was absent in 25% on right-side. Balachandra N et al., in their case report, described absent EJV on right-side of a male cadaver aged about 50 years. The RMV was not dividing into anterior and posterior divisions [14]. Rao YL et al., also found absent EJV [1].

Specimen 9-The caudal part of EJV obliterates. So, via the communication, EJV drains into IJV. EJV, in its cephalic part receives posterior division of RMV, which in turn receives PAV. Anterior division of RMV obliterates. So, FV drains into IJV without forming CFV. Communication nc obliterates [Table/Fig-3b].

A 38.5% of all specimens under study had shown undivided RMV unlike the finding of Pai M et al., study where it was 0.01%. 11.1% of male specimen show persistence of communication between external and IJV, unlike the female specimen where no such thing could be found [Table/Fig-17] [2]. In 25% of female specimen the RMV was found to drain into IJV in present study [Table/Fig-12]. But absence of RMV was not found which was reported by Patil J et al., found a specimen with no RMV formed, instead, the maxillary vein divided into anterior and posterior divisions [4].

Author name	Place of the study	Sample size	Undivided RMV	CFV absent	FV draining in IJV	Communication between IJV and EJV	Absent EJV	Absent RMV
Bertha A and Suganthy R [3] (2011)	Vellore	35	✓	X	X	X	X	X
Rao YL et al., [1] (2018)	Karnataka	1	✓	X	✓	X	✓	X
Arquez HF and Torres SIG [13] (2018)	Spain	34	X	X	X	✓	X	X
Balachandra N et al., [14] (2012)	Raipur	1	✓	X	✓	X	✓	X
Patil J et al., [4] (2014)	Karnataka	1	X	X	X	X	X	✓
Present study	West Bengal	26	✓	✓	✓	✓	✓	X

[Table/Fig-17]: Comparison of the results of previous similar studies [1,3,4,13,14].

## Limitation(s)

Limitations of present study was less sample size as prosection was not allowed at Calcutta National Medical College, and cadavers required for classes are only allowed to get dissected. Moreover, there was less scope of exploration of parotid region as the existing cadavers were being used for undergraduate classes.

## CONCLUSION(S)

In present study, the prevalence of variations in venous architecture was found to be 38.5%. Undivided RMV was encountered in all the specimens. Absence of EJV is a rarity, which was found in one specimen in present study. Communication between IJV and EJV was found in two specimens, which can be explained by the persistence of the embryological communications between these two veins of the neck. In future studies, exploration of parotid region with meticulous dissection of infratemporal fossa must be carried out to study the variations of RMV and communications among superficial and deep venous systems of neck region. RMV is used as a guide to expose the branches of facial nerve during superficial parotidectomy. So, variation of the division of RMV or its absence may affect such procedures, prior knowledge will definitely help practicing alternative skill during such surgeries.

## Acknowledgement

Authors express gratitude to those who donated their bodies for academic purpose.

## REFERENCES

- [1] Rao YL, Ballal V, Murlimanju VB, Pai MM, Tonse M, Krishnamurthy A. Undivided retromandibular vein leading to the absence of external jugular vein. *J Morphol Sci.* 2018;35:225-28.
- [2] Pai M, Vadgaonkar R, Prabhu L, Shetty P. The different termination patterns of the facial vein: A cadaveric study. *First Tip Dergisi.* 2008;13:32-34.
- [3] Bertha A, Suganthi R. Anatomical variations in termination of common facial vein. *J Clin Diag Res.* 2011;5(1):24-27.
- [4] Patil J, Kumar N, Swamy RS, D'Souza MR, Guru A, Nayak SB. Absence of retromandibular vein associated with atypical formation of external jugular vein in the parotid region. *Anat Cell Biol.* 2014;47(2):135-37.
- [5] Cvetko E. A case of left-sided absence and right-sided fenestration of the external jugular vein and a review of literature. *Surg Radiol Anat.* 2015;37(7):883-86.
- [6] Dalip D, Iwanga J, Loukas M, Oskouian RJ, Tubbs RS. Review of the variations of the superficial veins of the neck. *Cureus.* 2018;10(6):2826.
- [7] Standing SM. *Grays Anatomy.* 42<sup>nd</sup> ed. London: Elsevier Churchill Livingstone, 2021. Pp. 590-93.
- [8] Richard S. Snell. *Clinical Anatomy by Regions,* 8<sup>th</sup> Ed. India, Wolter Kluwer India, 2007. Pp. 752.
- [9] Siegel EA, Caresio J, Eckard DA. Use of the external jugular vein approach for transvenous liver biopsy. *JVIR.*1992;3:371-74.
- [10] Gogolev MP. The treatment of hydrocephalus by ventriculojugular shunting. *Zh Vopr Neirokhir Im N N Burdenko.*1993;(3):24-26.
- [11] Nagase T, Kobayashi S, Sekiya S, Ohmori K. Anatomic evaluation of the facial artery and vein using colour doppler ultrasonography. *Ann Plast Surg.* 1997;39:64-67.
- [12] Ghosh S, Mandal L, Roy S, Bandyopadhyay M. Two rare anatomical variations of external jugular vein-An embryological overview. *IJM.* 2012;30:821-24.
- [13] Arquez HF, Torres SIG. Unusual venous drainage of the common facial vein. A morphological study. *Arch Int Med.* 2018;11:1-12.
- [14] Balachandra N, Kadirappa P, Prakash BS, Bindinganavile RR. Variation of the veins of the head and neck-external jugular vein and facial vein. *IJAV.* 2012;5:99-101.

### PARTICULARS OF CONTRIBUTORS:

1. Assistant Professor, Department of Anatomy, Calcutta National Medical College, Kolkata, West Bengal, India.
2. Associate Professor, Department of Anatomy, Calcutta National Medical College, Kolkata, West Bengal, India.
3. Demonstrator, Department of Anatomy, Calcutta National Medical College, Kolkata, West Bengal, India.
4. Assistant Professor, Department of Anatomy, Murshidabad Medical College, Berhampore, Murshidabad, West Bengal, India.
5. Professor, Department of Anatomy, Calcutta National Medical College, Kolkata, West Bengal, India.

### NAME, ADDRESS, E-MAIL ID OF THE CORRESPONDING AUTHOR:

Dr. Oyndrila Sengupta,  
58/1B, Raja Ram Mohan Sarani, Kolkata-700009, West Bengal, India.  
E-mail: sanskritabrata@gmail.com

### PLAGIARISM CHECKING METHODS: [Jain H et al.]

- Plagiarism X-checker: May 11, 2022
- Manual Googling: Aug 26, 2022
- iThenticate Software: Oct 18, 2022 (7%)

### ETYMOLOGY: Author Origin

### AUTHOR DECLARATION:

- Financial or Other Competing Interests: None
- Was Ethics Committee Approval obtained for this study? NA
- Was informed consent obtained from the subjects involved in the study? No
- For any images presented appropriate consent has been obtained from the subjects. No

Date of Submission: **May 01, 2022**  
Date of Peer Review: **Jun 15, 2022**  
Date of Acceptance: **Oct 20, 2022**  
Date of Publishing: **Mar 01, 2023**