


Cervical Epidural Anaesthesia in a Patient with Ebstein's Anomaly requiring Total Thyroidectomy

GEETHA SOUNDARYA UDAYAKUMAR¹, HANNAH MOUNIKA NUNNA²

ABSTRACT

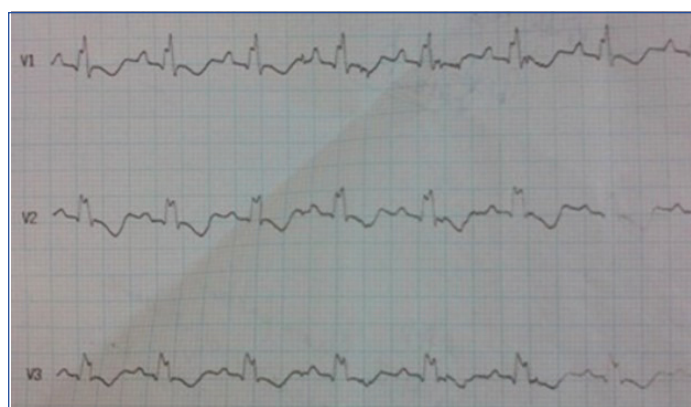
Ebstein's anomaly is a congenital malformation of the tricuspid valve with myopathy of the right ventricle leading to dilatation and atrialisation of the right ventricle, with varying degrees of malformation along with restriction of diastolic filling of ventricles. Disease severity in Ebstein's anomaly can range from asymptomatic patients to severe debilitating disease. These patients are at increased risk of developing ventricular and supraventricular tachycardia, congestive cardiac failure and death. This case report is about a 37-year-old female with Ebstein's anomaly who presented with atrial fibrillation and right-sided heart failure. She successfully underwent total thyroidectomy under cervical epidural anaesthesia.

Keywords: Adult congenital heart disease, Arrhythmia, Tricuspid valve

CASE REPORT

A 37-year-old female patient presented with the chief complaints of gradually progressive swelling over the front of the neck for the past three years. She was diagnosed with Ebstein's anomaly before 12 years. She was on warfarin 4 mg, digoxin 0.0625 mg, and verapamil 240 mg for the past eight years. She also had hypothyroidism for the past five years, for which she was on Eltroxin 50 µg. She developed ascites due to congestive cardiac failure for that she was taking torsemide 10 mg for the past five years. She had exertional dyspnoea of New York Heart Association Class 2 and palpitations. There was no history of chest pain, or recurrent chest infections.

On general examination, she had grade 2 clubbing. Bilateral pitting pedal oedema, and raised jugular venous pulsation. Her heart rate was 94/minute, blood pressure was 135/94 mmHg, and SpO₂ was 100% on room air. On cardiovascular examination, parasternal heave, and raised jugular venous pulsations was noticed. On auscultation widely split S₁, a holosystolic murmur over the tricuspid was observed. Electrocardiography showed right bundle branch block and right ventricular hypertrophy with right axis deviation [Table/Fig-1]. Chest radiograph showed cardiomegaly.



[Table/Fig-1]: Showing electrocardiography findings.

Echocardiography revealed grossly dilated right atrium, small right ventricle, low-pressure severe tricuspid regurgitation, and compressed left ventricle with normal contractility. Ultrasound abdomen revealed dilatation of inferior vena cava and hepatic vein, minimal right-sided pleural effusion, and mild ascites. Her haemogram, thyroid function test, renal function test, and liver

function test were normal. Thyroid function tests were within normal limits-T₃-1.25 ng/mL; T₄-7.78 µdL; TSH-1.2 micro IU/mL.

The patient was posted for total thyroidectomy. She was advised to stop warfarin and to start intravenous (i.v.) unfractionated heparin four days before surgery and to stop heparin six hour before the surgery. Infective endocarditis prophylaxis was given as per the cardiologist's advice. Cervical epidural anaesthesia was planned for total thyroidectomy after obtaining informed consent and explaining about the merits and demerits of all anaesthetic techniques. In the operating room, monitors including an electrocardiogram, pulse oximeter, and non invasive blood pressure were attached. Peripheral i.v. access was obtained. Invasive blood pressure was monitored in the right-sided radial artery.

The patient was placed in the left lateral position. Under sterile aseptic technique, at the level of C7-T1 interspace 20 G epidural catheter was inserted after confirming by loss of resistance technique. Catheter was inserted 4 cm into epidural space. A test dose of 3 mL of 0.25% bupivacaine was given. After observing the patient for 10 minutes, 7 mL of 0.25% was given to achieve sensory blockade upto the C3 dermatome level. The patient was sedated with midazolam (0.04 mg/kg i.v.). The patient had minimal hypotension which was managed with a bolus dose of 50 µg of phenylephrine. Vocal cord functions were monitored intermittently by verbal contact with the patient. A continuous epidural infusion was given with 0.25% bupivacaine 4 mL per hour. The catheter was removed at the end of surgery to avoid any accidental removal after restarting anticoagulation. Patient recovered from sensory blockade within four hours and after that analgesia was maintained with the help of i.v. tramadol and paracetamol. The i.v. heparin restarted after four hours of catheter removal. The patient was discharged on the 7th postoperative day.

DISCUSSION

Ebstein's anomaly is a congenital malformation of the tricuspid valve with myopathy of the right ventricle. It is characterised by displacement of the tricuspid valve leaflets, apical descent of the functional tricuspid orifice, right ventricular dilatation and atrialisation, and right atrioventricular junction dilation. Apical displacement of septal leaflets is more significant (>8 mm/m² body surface area) when compared to other congenital regurgitant lesions [1]. Right ventricle function is impaired, and regurgitation of the tricuspid valve retards the forward flow of blood through right-side of the heart

[2]. In addition, interatrial communication through a patent foramen ovale might be associated with the condition resulting in the right to left shunting [1]. The anticipated complications are cyanosis, pulmonary hypertension, supraventricular tachycardia [3], pulmonary and systemic emboli, congestive cardiac failure, and sudden death.

The goal of anaesthesia in these patients is to maintain sinus rhythm and both preload and afterload [4]. Right to left cardiac shunt worsened in general anaesthesia as there is a sudden decrease in systemic vascular resistance [5]. Intracardiac shunt increases during general anaesthesia due to increased catecholamine levels as well as increased intrathoracic pressure [5]. During induction hypotension, supraventricular arrhythmias, sudden pulmonary oedema, and cardiac arrest can occur [6]. Epidural anaesthesia is preferred in Ebstein's anomaly as there is minimal intravascular volume shift as well as stable catecholamine levels [5].

Anaesthetic management of surgical correction of Ebstein's anomaly has been described and a few case reports are available about anaesthetic management of such patients for non cardiac surgeries under different techniques. Continuous epidural, single-dose caudal epidural and general anaesthesia was successfully administered in pregnant patients [7] with Ebstein's anomaly, while general anaesthesia was safely administered for laparoscopic cholecystectomy [8]. General anaesthesia was successfully administered in Ebstein's anomaly patient for hemithyroidectomy [9] using etomidate as an induction agent, maintained with isoflurane 0.8% and oxygen and nitrous oxide 50:50 as there is no pulmonary artery hypertension and superficial cervical plexus block for postoperative analgesia. No case has been reported so far that has described cervical epidural anaesthesia for thyroidectomy in a patient with Ebstein's anomaly.

General anaesthesia with intubation could be deleterious in the case of right heart failure due to a decrease in preload and an increase in pulmonary artery pressure. Since, this patient had right heart failure, cervical epidural anaesthesia would be safer than general anaesthesia. After explaining to the patient about the merits and demerits of all anaesthetic techniques, cervical epidural anaesthesia was planned for total thyroidectomy. While formulating the anaesthetic plan, both patient safety and preference were considered. Since the patient had atrial fibrillation, she was on tablets digoxin, verapamil, and warfarin. Patient was advised to discontinue warfarin four days before surgery and to switch over to i.v. heparin. To use neuraxial blockade, unfractionated heparin was discontinued six hours before the procedure. Antiarrhythmic drugs and Eitroxin should be continued till the day of surgery. Infective endocarditis prophylaxis is recommended for patients with Ebstein's anomaly [10]. Central venous catheterisation was avoided as patients with Ebstein's anomaly are more prone to arrhythmias [11]. The patient tolerated epidural placement and the surgery went well. Hypotension should be treated with vasopressors rather than i.v. fluids because the routine treatment with fluids might lead to congestive heart failure, increasing the magnitude of the right to the left shunt leading to hypoxemia. Ephedrine, a commonly used vasopressor, may precipitate supraventricular tachycardia in these patients [7], better to be avoided. Phenylephrine a pure alpha agonist would be the drug of choice. This patient had minimal

hypotension which was well managed with a bolus dose of 50 µg of phenylephrine. Phenylephrine can be used in case of reversal of shunt if occurs intraoperatively. The i.v. fluid administration was restricted as there is a risk of right ventricular failure. After the surgery, epidural catheter was removed to avoid epidural haematoma formation if it gets dislodged accidentally after restarting heparin postoperatively. Analgesia was provided with i.v. tramadol and paracetamol. The i.v. heparin restarted four hours after epidural catheter removal.

Patients with Ebstein's anomaly are prone to cardiac arrhythmias mainly supraventricular tachycardia. Patients should be maintained in a deep plane of anaesthesia and acid-base balance to be maintained to avoid arrhythmias [3]. Bedside echocardiography need to be kept available in the operating room which is an ideal cardiac monitor for intraoperative cardiac status assessment in such cases [11].

CONCLUSION(S)

Anaesthetic management of a patient with Ebstein's anomaly undergoing non cardiac surgery should be based on the patient's baseline cardiac status. This is a case report of successful anaesthetic management of a patient with Ebstein's anomaly undergoing total thyroidectomy, using cervical epidural technique with better haemodynamic stability and good perioperative outcome.

REFERENCES

- [1] Attenhofer Jost CH, Connolly HM, Edwards WD, Hayes D, Warnes CA, Danielson GK. Ebstein's anomaly-review of a multifaceted congenital cardiac condition. *Swiss Med Wkly*. 2005;135(19-20):269-81.
- [2] Attenhofer Jost CH, Connolly HM, Dearani JA, Edwards WD, Danielson GK. Ebstein's anomaly. *Circulation*. 2007;115(2):277-85.
- [3] Macfarlane AJ, Moise S, Smith D. Caesarean section using total intravenous anesthesia in a patient with Ebstein's anomaly complicated by supraventricular tachycardia. *Int J Obstet Anesth*. 2007;16(2):155-59.
- [4] Rathna R, Tejesh CA, Manjunath AC, Mathew KT. Anesthesia for incidental surgery in a patient with Ebstein's anomaly. *SAARC J Anesth*. 2008;1:85-87.
- [5] Qu DM, Jin YF, Ye TH, Cui YS, Zhang ZY. The effects of general anaesthesia combined with epidural anaesthesia on the stress response in thoracic surgery. *Zhonghua Yi Xue Za Zhi*. 2003;83(5):408-11. Chinese. PMID:12820919.
- [6] Subramanian S, Padmanabhan SH, Raghuraman MS, Nayak MR. Anesthetic management of a patient with Ebstein's anomaly for obstructed inguinal hernia. *J Cell Mol Anesth*. 2022;7(2):128-30.
- [7] Halpern S, Gidwaney A, Gates B. Anaesthesia for cesarean section in a pre-eclamptic patient with Ebstein's anomaly. *Can Anaesth Soc J*. 1985;32(3 Pt 1):244-47.
- [8] Choudhuri AH, Uppal R, Khaitan M. Laparoscopic cholecystectomy in a patient with Ebstein's anomaly: Anesthetic considerations. *Saudi J Anaesth*. 2012;6(3):301-02.
- [9] Bhashyam S, Krishna Prasad P, Sowbhagya Lakshmi B, Bramhaji Rao KVP. Anesthetic management of a known case of Ebstein's anomaly posted for hemithyroidectomy: A case report. *JEMDS*. 2014;3(50):11860-65.
- [10] Wilson W, Taubert KA, Gewitz M, Lockhart PB, Baddour LM, Levison M, et al. Prevention of infective endocarditis: Guidelines from the American Heart Association: A guideline from the American Heart Association Rheumatic Fever, Endocarditis, and Kawasaki Disease Committee, Council on Cardiovascular Disease in the Young, and the Council on Clinical Cardiology, Council on Cardiovascular Surgery and Anesthesia, and the Quality of Care and Outcomes Research Interdisciplinary Working Group. *Circulation*. 2007;116:1736-54.
- [11] Horishita T, Minami K, Koga K, Ogata J, Sata T. Anesthetic management using echocardiography for surgery of lower extremity in a patient with Ebstein's malformation. *Anesth Analg*. 2005;101:606-15.

PARTICULARS OF CONTRIBUTORS:

1. Assistant Professor, Department of Anaesthesiology, Sree Balaji Medical College and Hospital, Chennai, Tamil Nadu, India.
2. Junior Resident, Department of Anaesthesiology, Sree Balaji Medical College and Hospital, Chennai, Tamil Nadu, India.

NAME, ADDRESS, E-MAIL ID OF THE CORRESPONDING AUTHOR:

Dr. Geetha Soundarya Udayakumar,
Assistant Professor, Department of Anaesthesiology, Sree Balaji Medical College and Hospital, Chromepet, Chennai-600044, Tamil Nadu, India.
E-mail: gsound15@gmail.com

AUTHOR DECLARATION:

- Financial or Other Competing Interests: None
- Was informed consent obtained from the subjects involved in the study? Yes
- For any images presented appropriate consent has been obtained from the subjects. Yes

PLAGIARISM CHECKING METHODS: [Jain H et al.]

- Plagiarism X-checker: Aug 30, 2022
- Manual Googling: Nov 04, 2022
- iThenticate Software: Feb 11, 2023 (5%)

ETYMOLOGY: Author Origin

Date of Submission: **Aug 25, 2022**

Date of Peer Review: **Oct 11, 2022**

Date of Acceptance: **Dec 23, 2022**

Date of Publishing: **Mar 01, 2023**