

Omental Herniation through Uterine Perforation due to Unsafe Abortion: A Case Report

IMRAN AHMED KHAN¹, VEENA SHAHI², NAJMA MALIK³, MD ABU BASHAR⁴, RAJEEV SHAHI⁵

ABSTRACT

Post-abortion complications are a significant cause of maternal morbidity and mortality when conducted by untrained persons in sub-standard settings, which are commonly seen in Low and Middle-Income Countries (LMICs). The presentation depends on the type and extent of the injury but at times may be misleading and delayed recognition resulting in fatal complications. Uterine perforation is one of the uncommon complications of unsafe abortion. The authors report a case of 26-year-old female patient, gravida 2, para 1 admitted with a history of bleeding per vaginum for the past five days. A detailed Ultrasonography (USG) was done by an ultrasonologist who confirmed the presence of a small rent in the uterine wall and the intrauterine product as a continuation of the omentum. An emergency laparotomy was performed and intraoperative findings showed uterine perforation located at the scar line of the previous uterine incision, through which omentum has entered the uterine cavity and traversed through the cervical canal into the vagina. That part of the omentum which had come into the uterine cavity was removed after ligating all feeding vessels, and the rest of the omentum was placed back into the peritoneal cavity. The uterus was preserved and the patient was discharged in stable condition. Uterine perforation sometimes may present with minimal symptoms and a thorough history and physical examination is key in diagnosing it. Unsafe abortions in hands of quacks and unqualified practitioners leading to life-threatening complications still remain a major problem in developing countries like India and require the immediate attention of policymakers.

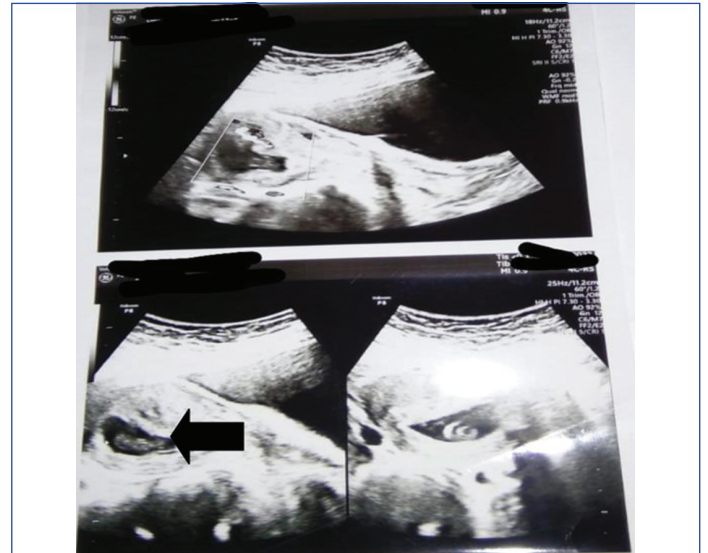Keywords: Dilatation and curettage, Maternal morbidity, Mortality, Postabortion complications

CASE REPORT

A 26-year-old female patient, gravida 2, para 1, with nine weeks of gestation, presented with the complaint of bleeding per vaginum for the past five days to present hospital. On arrival, she had a mild pain in the lower abdomen with no fever or vomiting. Four days ago, she presented as a case of missed abortion of nine weeks gestation at a private clinic and was posted for uterine Dilatation and Curettage (D&C) by the private practitioner but the procedure could not be performed as the cervix was not adequately dilated to perform the procedure and was, therefore, referred to our tertiary care centre. Her past medical, family and personal histories were uneventful. On physical examination, the patient was fully conscious, and in good general condition. Her abdomen was soft, non tender with normal bowel movement. Her pulse rate was 78/minute, blood pressure was 118/76 mmHg, respiratory rate was 14/minute with normal temperature. Routine surgical profile was normal. An Ultrasonography (USG) was performed by the gynaecologist showing some retained products of conception.

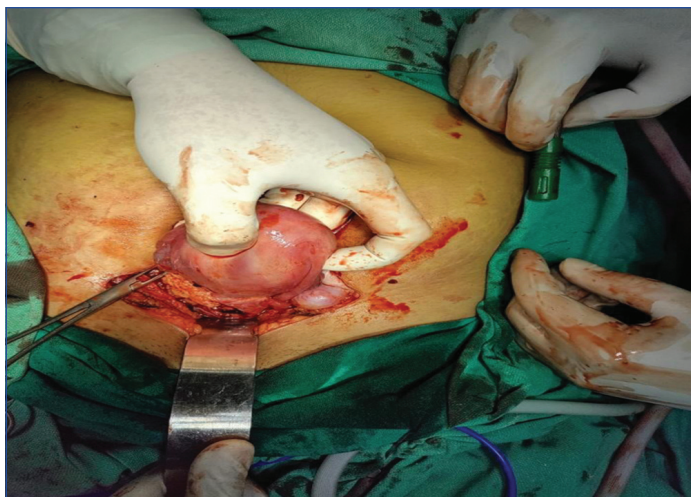
Cervix was ripened and D&C was planned under general anaesthesia as per the presentation of incomplete abortion. The procedure was abandoned because of suspicion of omentum herniation during the pervaginal examination under general anaesthesia. The patient was allowed to reverse spontaneously, to be posted later after completion of thorough investigation. A detailed USG was done by an ultrasonologist who confirmed the presence of a small rent in uterine wall and the intrauterine product as continuation of omentum [Table/Fig-1].

The patient and attendants were explained about the condition and were advised a laparotomy to manage the case with the consent of hysterectomy, if required. After obtaining informed consent, a laparotomy was performed under subarachnoid block in view of the stable hemodynamics of the patient and having no contraindication of spinal anaesthesia. The intraoperative findings



[Table/Fig-1]: Ultrasonography (USG) showing a small rent in the uterine wall with omental herniation inside the uterine cavity.

were as follows: uterine perforation was located at the scar line of the previous uterine incision, through which omentum has entered the uterine cavity and traversed through the cervical canal into the vagina and was lying just at the verge of the vaginal opening. That part of the omentum which had come into the uterine cavity was removed after ligating all feeding vessels and the rest of the omentum was placed back into the peritoneal cavity. Curettage of the uterine cavity was done and products of conception were removed followed by suturing of the uterine perforation with vicryl no 1 [Table/Fig-2]. The uterus was preserved. Thorough lavage of the peritoneal cavity was done with warm normal saline and metronidazole was instilled at the end of the lavage. An Intraperitoneal Abdominal Drain Kit (ADK) was placed in the pelvis.



[Table/Fig-2]: Intraoperative image of the repair of the uterine perforation by suturing with vicryl.

The postoperative course was uneventful. She was allowed liquid oral feeding on the first postoperative day and a soft diet on the second postoperative day followed by a normal diet which she tolerated well. The drain was removed on postoperative day third. Sutures were removed on the eighth postoperative day and she was discharged in stable condition. She was also provided psychological support as well as counseling on the need for contraceptive measures.

DISCUSSION

Post-abortion complications are a significant cause of maternal morbidity and mortality worldwide, particularly in low-income countries [1]. In fact, abortion accounts for approximately 8% of all maternal deaths across the world, and 99.5% of these deaths take place in low-income countries [2]. Unsafe abortion also called “clandestine abortion” is a procedure for terminating an unintended pregnancy performed by people who do not possess the necessary skill or in an environment that does not fulfill required medical standards, or both [3]. Unsafe abortion carries more risks of serious maternal complications or death as compared to safe abortion. Complications after unsafe abortion may be due to direct procedure related injury, incomplete evacuation leading to uterine atony and haemorrhage and failure to comply with universal precautions leading to infection [4]. In this case report, the authors presented a referred case of omentum prolapse through the uterine perforation which occurred following D&C performed by an uncertified medical practitioner.

Iatrogenic uterine perforation, defined as a breakdown of the entire full thickness of the uterine wall following a gynaecological procedure, usually by a sharp instrument, is a fairly frequent and serious complication of intrauterine procedure that can be life-threatening as well as compromising a woman's future fertility [5]. The reported incidence of uterine perforation varies between 0.4 and 15 per 1000 abortions across the Globe [6]. In a study conducted by Chawla S et al., the incidence of intestinal injury was found to be between 5-18% [7]. However, studies suggest underestimation and under-reporting of uterine perforations [8]. In developing countries like India, though abortion is legalised, it is still inaccessible to women living in remote areas. Consequently, they approach local dais or untrained persons lacking the required knowledge, skill and facilities for the termination of unwanted pregnancies [9]. The risk factors associated with increased chances of uterine perforation are previous D&C, prior caesarean section, advanced maternal age, greater parity, and lack of proper training of the persons carrying out the procedure [10].

The case discussed here was a previous caesarean delivery and was attempted D&C by an untrained and uncertified person. Intraabdominal content may be traumatised during the D&C procedure

by a curette, ovum forceps, plastic cannula, or even by a uterine sound. Injury can result in perforation, contusion, haematoma, or complete transection of the bowel and pneumoperitoneum [11]. If left untreated, it may lead to peritonitis, septic shock and even death [12]. At times bowel can prolapse through the uterine rent into the vagina and can be seen outside the vulva requiring emergency laparotomy [13]. The minimal clinical findings and normal laboratory investigations in the present case may be due to small uterine rent with no bowel involvement and early presentation. Uterine perforation should be suspected when there is a sudden loss of resistance while performing the procedure. A defect in the uterine wall can be easily detected by USG by an expert operator. More accurate and detailed information can be obtained by Computed Tomography (CT) and Magnetic Resonance Imaging (MRI) in non conclusive reports [14]. This case highlights the challenges that Indian women face regarding lack of awareness and access to quality health.

In the present case, omentum was seen per vaginum in the absence of abdominal signs, mimicking retained product of conception. Similarly, Chandhi A et al., found omentum herniation with clinical features of mild pain abdomen and a soft abdomen on palpation [6]. D&C should always be performed under USG guidance, wherever possible [15]. Service providers should also have adequate knowledge about the latest guidelines of the Medical Termination of Pregnancy (MTP) act to avoid any legal issues. The MTP (Amendment) Bill 2020 stresses dignity, autonomy, confidentiality, and justice for women who need to terminate pregnancy [16].

The D&C should be performed under USG guidance wherever possible. The attending gynaecologist should always have a high suspicion of serious pathology in referred cases, especially when returned from operation theatre from elsewhere. A thorough clinical examination gives a better idea about underlying pathology, but one should think beyond the clinical presentation as in the present case, where there were no clinical signs of peritonitis in presence of uterine perforation and omental herniation through the uterus and the patient complaint of only mild abdominal pain. One should always post cases in the operation theatre only after appropriate work-up and should be more cautious in redo procedures.

CONCLUSION(S)

A good history is essential to make a timely and correct diagnosis. Prompt recognition of uterine perforation and early intervention are the two most important steps in management. Adequate health education of the target population should be conducted so that they do not opt for illegal methods of termination of pregnancy. The local practitioners should also be given basic training, so that they can diagnose and refer the patient earliest to a tertiary care centre if any untoward complication occurs during the procedure. Healthcare providers should have updated knowledge regarding the current prevailing rules of the state.

REFERENCES

- [1] Trends in maternal mortality 2000 to 2017; Estimates by WHO, UNICEF, UNFPA. World Bank Group and the United Nations Population Division. World Health Organization; 2019.
- [2] Say L, Chou D, Gemmill A, Tunçalp Ö, Moller AB, Daniels J, et al. Global causes of maternal death: A WHO systematic analysis. *Lancet Glob Health*. 2014;2(6):e323-33.
- [3] Ganatra B, Tunçalp Ö, Johnston HB, Johnson BR Jr, Gülmezoglu AM, Temmerman M. From concept to measurement: Operationalizing WHO's definition of unsafe abortion. *Bull World Health Organ*. 2014;92(3):155.
- [4] Sajadi-Ernazarova KR, Martinez CL. Abortion complications. *InStatPearls [Internet]* 2021 May 24. StatPearls Publishing.
- [5] Shakir F, Diab Y. The perforated uterus. *The Obstetrician & Gynaecologist*. 2013;15(4):256-61.
- [6] Chandhi A, Jain S, Yadav S, Gurawalia J. Vaginal evisceration as rare but a serious obstetric complication: A case series. *Case Rep Womens Health*. 2016;10:04-06. Doi: 10.1016/j.crwh.2016.05.001. eCollection 2016 Apr.
- [7] Chawla S, Jain S, Suneja A, Guleria K. Degloving injury of bowel: An unheard complication of surgical abortion. *J Clin Diagn Res*. 2016;10(5):QD01-02.

- [8] Kaali SG, Szigetvari IA, Bartfai GS. The frequency and management of uterine perforations during first-trimester abortions. *Am J Obstet Gynecol.* 1989;161(2):406-08.
- [9] Samantray SR, Mohapatra I. Small bowel prolapse a rare complication following unsafe abortion. *Cureus.* 2020;12(10):e11260.
- [10] Augustin G, Majerović M, Luetić T. Uterine perforation as a complication of surgical abortion causing small bowel obstruction: A review. *Arch Gynecol Obstet.* 2013;288(2):311-23.
- [11] Raol K, Kuppusamy N, Sanghavi NA, Kaur N, Rajendran K. Detrimental pneumoperitoneum and bowel necrosis secondary to dilatation and curettage: Necessitating the importance of healthcare awareness. *Cureus.* 2021;13(10):e18594.
- [12] Chang HM, Shen CJ, Lin CY, Tsai EM. Uterine perforation and bowel incarceration following surgical abortion during the first trimester. *Taiwan J Obstet Gynecol.* 2008;47(4):448-50.
- [13] Tchienkam LW, Mbonda AN, Tochie JN, Mbem-Ngos PP, Noah-Ndzie HG, Bang GA. Transvaginal strangulated bowel evisceration through uterine perforation due to unsafe abortion: A case report and literature review. *BMC Womens Health.* 2021;21(1):98.
- [14] Koshiba A, Koshiba H, Noguchi T, Iwasaku K, Kitawaki J. Uterine perforation with omentum incarceration after dilatation and evacuation/curettage: Magnetic resonance imaging findings. *Arch Gynecol Obstet.* 2012;285(3):887-90.
- [15] Chaikof M, Lazer T, Gat I, Quach K, Alkudmani B, Zohni K, et al. Lower complication rates with office-based D&C under ultrasound guidance for missed abortion. *Minerva Ginecol.* 2017;69(1):23-28.
- [16] Barua A, Rastogi A, Deepa V, Jain D, Gupte M, Mallik R, et al. The MTP 2020 amendment bill: Anti-rights subjectivity. *Sexual and Reproductive Health Matters.* 2020;28(1):1795447.

PARTICULARS OF CONTRIBUTORS:

1. Senior Resident, Department of Community Medicine, BRD Medical College, Gorakhpur, Uttar Pradesh, India.
2. Consultant, Department of Obstetrics and Gynaecology, Neelkanth Hospital, Gorakhpur, Uttar Pradesh, India.
3. Associate Professor, Department of Obstetrics and Gynaecology, BRD, Medical College, Gorakhpur, Uttar Pradesh, India.
4. Assistant Professor, Department of Community Medicine and Family Medicine, All India Institute of Medical Sciences, Gorakhpur, Uttar Pradesh, India.
5. Consultant, Department of Surgery, Neelkanth Hospital, Gorakhpur, Uttar Pradesh, India.

NAME, ADDRESS, E-MAIL ID OF THE CORRESPONDING AUTHOR:

MD Abu Bashar,
Assistant Professor, Department of Community Medicine and Family Medicine,
All India Institute of Medical Sciences, Gorakhpur, Uttar Pradesh, India.
E-mail: imback20006@yahoo.in

PLAGIARISM CHECKING METHODS: [\[Lain H et al.\]](#)

- Plagiarism X-checker: Dec 13, 2022
- Manual Googling: Jan 18, 2023
- iThenticate Software: Feb 07, 2023 (10%)

ETYMOLOGY: Author Origin**AUTHOR DECLARATION:**

- Financial or Other Competing Interests: None
- Was informed consent obtained from the subjects involved in the study? Yes
- For any images presented appropriate consent has been obtained from the subjects. Yes

Date of Submission: **Dec 12, 2022**Date of Peer Review: **Jan 21, 2023**Date of Acceptance: **Feb 16, 2023**Date of Publishing: **Apr 01, 2023**