

Dengue Fever Presenting as Ischaemic Stroke: A Case Report

RAJASEKHAR PUTTA¹, K VALI BASHA², K NEWTON ISSAC³ PRANEETH PERUMALLA⁴

(CC) BY-NC-ND

ABSTRACT

Several neurological manifestations are common in dengue fever. They are encephalitis, encephalopathy, Guillain Barre Syndrome (GBS), Intracranial haemorrhage, but, ischaemic stroke is a rare complication. This is a case report of ischaemic stroke in a patient with dengue fever. A 39-year-old female patient presented to the emergency department with the chief complaints of fever, retro orbital pain since four days, and one episode of seizure on the day of presentation. Examination revealed left homonymous hemianopia. Diagnosis of dengue was made based on Immunoglobulin M (IgM) Enzyme-Linked Immunosorbent Assay (ELISA) positive for dengue. Magnetic Resonance Imaging (MRI) brain showed acute infarcts in right temporal, right occipital and right hippocampal region. Severity of hemianopia decreased as the days progressed and platelet count gradually improved to normal limits within five days. Adequate fluid management was given and the patient was discharged once stable. Anti-platelets were started after two weeks during the follow-up. Examination during follow-up showed decrease in hemianopia to just mild blurring of vision on left gaze. Ischaemic stroke is rarer entity and clinicians should be made aware of this complication.

Keywords: Coagulopathy, Encephalitis, Thrombocytopenia, Vasculitis

CASE REPORT

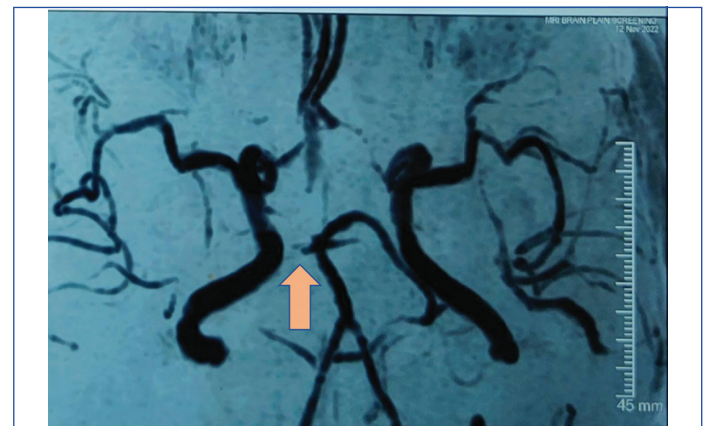A 39-year-old female patient presented to the emergency department with the chief complaints of fever, headache since four days and one episode of seizure on the day of presentation to the hospital. History of presenting illness revealed high grade fever of 101 degree Fahrenheit which was intermittent and was not associated with chills and rigours. History of headache and retro-orbital pain was from four days. On the day of presentation to the hospital, there was an episode of generalised tonic clonic seizure and decreased vision on left gaze. There was no significant past history or family history. On examination the general condition of the patient was good and vitals were stable. Neurological examination revealed left sided homonymous hemianopia. Initially there was a complete loss of vision in left sided visual field which gradually improved from day four of admission. Rest of the neurological examination was normal. Other systemic examination was normal. Investigations revealed IgM positive dengue associated with leukopaenia and thrombocytopenia which showed a decline in count initially followed by gradual rise as shown here (11700-72000-57000-89000-147000/ μ L). Other investigations have been tabulated below [Table/Fig-1].

| Investigations | Results |
|---------------------|---------------------------|
| Malaria | Negative |
| Leptospira | Negative |
| Weil-Felix | Negative |
| Fundus | Normal |
| ECG | Normal |
| ECHO | Normal |
| Neck vessel doppler | Normal |
| Homocysteine | Normal (14.3 μ mol/L) |
| Protein C | Normal (103%) |
| Protein S | Normal (123%) |
| Anti thrombin III | Normal (112%) |

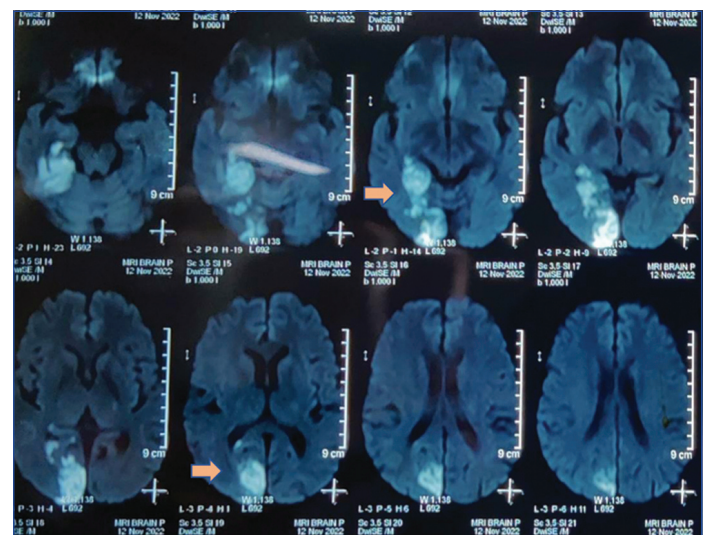
[Table/Fig-1]: Investigations and results.

MRI brain showed acute infarcts in right temporal, occipital and right hippocampal region with MR angiography showing absent flow in right posterior cerebral artery [Table/Fig-2,3]. Adequate fluid

therapy was given after two weeks during follow-up as the main stay of treatment and the patient was discharged once stable. The platelets improved to the normal limits. During the follow-up visit she



[Table/Fig-2]: MR Angiograph- Arrow showing absence of flow in right posterior cerebral artery.



[Table/Fig-3]: Showing MRI Brain - Arrow showing acute infarcts in right temporal, right occipital and right hippocampal region.

showed an improvement in the field of vision from complete loss of vision on left gaze to just blurring of vision. Antiplatelet agents were started during follow-up visit.

DISCUSSION

The prevalence of neurological manifestations in a dengue fever is rare. In a study, conducted among patients admitted with dengue fever 2.64% patients developed neurological manifestations [1]. Headache is very common in dengue which was also one of the complaint of the patient in this study and seen in >97% patients but not included in neurological manifestations [1]. The relationship between dengue and neurological manifestations is very difficult to establish and dengue may be a co-incident or precipitating factor and many investigations need to be done to rule out other causes of these manifestations as done in the present patient before attributing the present neurological manifestations to dengue [2]. Encephalopathy is considered to be the most common neurological manifestation of dengue [3]. It was reported in many studies to be present in 19.4% of patients with neurological manifestations as stated by Koshy JM et al., study, 22% as stated by Sahu R et al., study [4,5].

The pathophysiology of dengue encephalopathy is multifactorial and is due to cerebral oedema, hypoxia, haemorrhage and associated systemic dysfunction like shock, hyponatraemia, liver and kidney failure [2,3]. Encephalitis is also seen in dengue. It is an illness with altered sensorium, fever, seizures and focal deficits usually occurring with viral illness. Dengue is an uncommon cause of encephalitis [6]. The term encephalitis has been used in different contexts in various studies, hence the prevalence of it changes. In the latest study by Kulkarni R et al., its incidence was 15.6% [1]. It is diagnosed by CSF pleocytosis, radiological and serological features. The radiological pattern of dengue encephalitis is also very variable [7]. Seizures can also occur in dengue patients, as seen in the present case and seizures can also occur without any radiological abnormality but the patient had radiological abnormality in the form of infarct which was the cause for seizures. Its incidence varies from 43-70% [8,9]. Opsoclonus myoclonus syndrome can also occur in dengue but has a rare incidence [1]. It occurs as a postinfectious complication of dengue. Posterior Reversible Encephalopathy Syndrome (PRES) usually seen with elevated blood pressure and having a characteristic MRI findings of bilateral white matter hyperintensities more commonly seen posteriorly. It has also been described in infections like dengue [10]. Capillary endothelial dysfunction seen in dengue leads to loss of cerebral autoregulation and vasogenic oedema leading to PRES. For attributing PRES to dengue there should be absence of accelerated hypertension or drugs precipitating PRES. Syncope can occur in dengue due to hypotension, high grade fever or myocarditis. It is a common finding seen in 27.3% patients [1]. Intracranial haemorrhage occurs in dengue secondary to thrombocytopenia and vasculitis. Haemorrhage can be subdural, subarachnoid and intra parenchymal [11]. Surgical intervention can be challenging as there is associated thrombocytopenia. GBS is an acute neuropathy due to antecedent infection. GBS has been reported in few cases following dengue infection [12-14]. Dengue antigens may mimic antigens in peripheral nerves and cell mediated immunological response to viral antigens may target peripheral nerves in dengue associated GBS [1]. Brachial plexopathy has also been reported in dengue [15,16]. Hypokalemic paralysis has been described with dengue in various case series [4,5,17]. The mechanism postulated is transient renal tubular acidosis with increased urinary potassium wasting secondary to stress related increase in catecholamines in dengue [1]. Dengue usually causes intense myalgias but myositis and rhabdomyolysis have been rarely reported [18,19]. Dengue can also cause a large number of ophthalmological manifestations in the convalescent phase suggesting an immunological basis. Optic neuropathy is the most common among the ophthalmological manifestations [12,13].

Ischaemic stroke is a very rare entity in dengue and only a few cases have been reported across the globe [20]. One among those rare cases seen with dengue causing ischaemic stroke is this case. The pathogenic mechanism for the occurrence of dengue is thought to be due to meningo-vasculitis. Other mechanisms postulated were deranged haemostasis, hypotension, severe volume depletion leading to transient hypercoagulable state during dengue [1]. The most probable cause among these in present case might be the meningo-vasculitis and transient hyper coagulable state as this ischaemic stroke occurred during the peak of thrombocytopenia. Both arterial and venous thrombosis can occur in dengue but they are very rare. Only few cases have been recorded of dengue causing ischaemic stroke. The cause for this low incidence of dengue causing ischaemic stroke can be due to the decreased awareness of dengue presenting as ischaemic stroke and the difficulty in establishing the causative relation between dengue and ischaemic stroke.

CONCLUSION(S)

Neurological manifestations of dengue are a serious entity and utmost importance has to be given for it. Ischaemic stroke which is not very common in dengue, must be looked for in suspected cases, as early recognition and management can reduce both mortality and morbidity. Delayed recognition of ischaemic stroke can lead to increased risk of death. Thus, it is a priority to identify ischaemic stroke and other neurological manifestations in dengue as early as possible to enhance neurological recovery. Physicians should be made aware of these rare complications of dengue fever so as their early recognition is possible and strict intensive care management can be provided to such cases.

REFERENCES

- [1] Kulkarni R, Pujari S, Gupta D. Neurological manifestations of dengue fever. *Annals of Indian Academy of Neurology*. 2021;24:693-702.
- [2] Carod-Artal FJ, Wichmann O, Farrar J, Gascón J. Neurological complications of dengue virus infection. *Lancet Neurol*. 2013;12:906-19.
- [3] Murthy JMK. Neurological complication of dengue infection. *Neurol India*. 2010;58:581-84.
- [4] Koshy JM, Joseph DM, John M, Mani A, Malhotra N, Abraham GM, et al. Spectrum of neurological manifestations in dengue virus infection in Northwest India. *Trop Doct*. 2012;42:191-94.
- [5] Sahu R, Verma R, Jain A, Garg RK, Singh MK, Malhotra HS, et al. Neurologic complications in dengue virus infection: A prospective cohort study. *Neurology*. 2014;83:1601-09.
- [6] Soares C, Puccioni-Sohler M. Diagnosis criteria of dengue encephalitis. *Arq Neuro-Psiquiatr*. 2014;72:263.
- [7] Vyas S, Ray N, Maralakunte M, Kumar A, Singh P, Modi M, et al. Pattern recognition approach to brain MRI findings in patients with dengue fever with neurological complications. *Neurol India*. 2020;68:1038-47.
- [8] Pancharoen C, Thisyakorn U. Neurological manifestations in dengue patients. *Southeast Asian J Trop Med Public Health*. 2001;32:341-45.
- [9] Aradhya GH, Kumar S. Central nervous system manifestations and its outcome in Dengue fever. *RGUHS J Med Sci*. 2015;5:152-54.
- [10] Mai NTH, Phu NH, Nghia HDT, Phuong TM, Duc DT, Chau NVV, et al. Dengue-associated posterior reversible encephalopathy syndrome, Vietnam. *Emerg Infect Dis*. 2018;24:402-04.
- [11] Kumar R, Prakash O, Sharma BS. Intracranial hemorrhage in dengue fever: Management and outcome: A series of 5 cases and review of literature. *Surg Neurol*. 2009;72:429-33.
- [12] Prabhat N, Ray S, Chakravarty K, Kathuria H, Saravana S, Singh D, et al. Atypical neurological manifestations of dengue fever: A case series and mini review. *Postgrad Med J*. 2020;96:759-65.
- [13] Sanjay S, Wagle AM, Au Eong KG. Optic neuropathy associated with dengue fever. *Eye (Lond)*. 2008;22:722-24.
- [14] Soares CN, Cabral-Castro M, Oliveira C, Faria LC, Peralta JM, Freitas MR, et al. Oligosymptomatic dengue infection: A potential cause of Guillain Barré syndrome. *Arq Neuropsiquiatr*. 2008;66:234-37.
- [15] Verma R, Sahu R, Holla V. Neurological manifestations of dengue infection: A review. *J Neurol Sci*. 2014;346:26-34.
- [16] Verma R, Sharma P, Garg RK, Atam V, Singh MK, Mehrotra HS. Neurological complications of dengue fever: Experience from a tertiary center of north India. *Annals of Indian Academy of Neurology*. 2011;14:272-78.
- [17] Jha S, Ansari MK. Dengue infection causing acute hypokalemic quadriplegia. *Neurol India*. 2010;58:592-94.
- [18] Misra UK, Kalita J, Syam UK, Dhole TN. Neurological manifestations of dengue virus infection. *J Neurol Sci*. 2006;244:117-22.

- [19] Verma R, Holla W, Kumar V, Jain A, Husain N, Malhotra KP, et al. Astudy of acute muscle dysfunction with particular reference to dengue myopathy. Annals of Indian Academy of Neurology. 2017;20:13-22.
- [20] Verma R, Sahu R, Singh AS, Atam V. Dengue infection presenting as ischemic stroke: An uncommon neurological manifestation. Neurol India. 2013;61:317-18.

PARTICULARS OF CONTRIBUTORS:

1. Professor, Department of Internal Medicine, Kurnool Medical College and General Hospital, Kurnool, Andhra Pradesh, India.
2. Assistant Professor, Department of Internal Medicine, Kurnool Medical College and General Hospital, Kurnool, Andhra Pradesh, India.
3. Assistant Professor, Department of Internal Medicine, Kurnool Medical College and General Hospital, Kurnool, Andhra Pradesh, India.
4. Postgraduate, Department of Internal Medicine, Kurnool Medical College and General Hospital, Kurnool, Andhra Pradesh, India.

NAME, ADDRESS, E-MAIL ID OF THE CORRESPONDING AUTHOR:

Dr. Praneeth Perumalla,
21/225-4, 1st Road Extension, SKD Colony, Adoni-518301, Andhra Pradesh, India.
E-mail: praneethperumalla2@gmail.com

PLAGIARISM CHECKING METHODS: [Jain H et al.]

- Plagiarism X-checker: Dec 13, 2022
- Manual Googling: Feb 11, 2023
- iThenticate Software: Mar 16, 2023 (8%)

ETYMOLOGY: Author Origin**AUTHOR DECLARATION:**

- Financial or Other Competing Interests: None
- Was informed consent obtained from the subjects involved in the study? Yes
- For any images presented appropriate consent has been obtained from the subjects. Yes

Date of Submission: **Dec 10, 2022**Date of Peer Review: **Jan 20, 2023**Date of Acceptance: **Mar 24, 2023**Date of Publishing: **Apr 01, 2023**