

# Prevalence of Deep Vein Thrombosis among COVID-19 Patients using Colour Doppler Ultrasound in a Tertiary Care Centre of Central India: A Prospective Cohort Study

AMIT SHANKHWAR<sup>1</sup>, ALKA AGRAWAL<sup>2</sup>, AKSHA TANWANI<sup>3</sup>, VASUDEV LODHI<sup>4</sup>

## ABSTRACT

**Introduction:** Acute respiratory disease, Coronavirus Disease 2019 (COVID-19) is an infectious and potentially fatal respiratory disease. Increase in the inflammatory response, hypoxia, immobilisation are suggested mechanisms of procoagulant state. Deep Vein Thrombosis (DVT) and pulmonary emboli are common and often silent. Venous duplex ultrasound help in determination of the presence, extent, age of the thrombus and its attachment to venous wall.

**Aim:** To evaluate the prevalence of DVT by colour doppler ultrasound in lower limbs of mild to severe clinical categories of COVID-19 patients.

**Materials and Methods:** A time-bound, hospital-based prospective cohort study was conducted in the Department of Radiodiagnosis, MY Hospital, Indore, Madhya Pradesh, India, between March 2021 and February 2022. Study comprised 2200 cases of COVID-19 positive patients with elevated D-dimer levels i.e., >0.5 ng/mL and colour doppler imaging for lower limb. The clinical (co-morbidities,

clinical severity) and radiological data (compressibility, colour flow) were studied and analysed using Statistical Package for the Social Sciences (SPSS) software version 25.0.

**Results:** In the present study, there were 1144 (52%) males and 1056 (48%) females. Out of 2200 patients, 792 (36%) patients showed presence of DVT. The most prevalent age group was 36-55 years having 506 (63.9%) patients. Majority of DVT positive patients were suffering with hypertension and diabetes i.e., 261 (33%) and 372 (47%) patients, respectively. Most commonly affected vein in DVT was Common Femoral Vein (CFV) in 704 (88.9%) patients. Superficial veins thrombosis was also associated with DVT affecting Short Saphenous Vein (SSV) in 439 (55.4%) patients and Great Saphenous Vein (GSV) in 221 (27.9%) patients.

**Conclusion:** There was a high prevalence of DVT among COVID-19 positive patients. Colour doppler ultrasound has provided an excellent aid in the diagnosis of DVT.

**Keywords:** Coronavirus disease 2019, Femoral vein, Pulmonary emboli, Ultrasonography

## INTRODUCTION

Coronavirus Disease 2019 (COVID-19), an infectious and potentially fatal acute respiratory disease caused by the Severe Acute Respiratory Syndrome Coronavirus 2 (SARS-CoV-2) virus and was the cause of the worldwide pandemic. It causes an increase in inflammation, hypoxia, immobilisation, and disseminated intravascular coagulation, which is suggested mechanisms for a procoagulant state leading to microthrombosis, and angiogenesis [1]. The triggers of venous thrombosis are frequently multifactorial, with the different parts of the triad of Virchow i.e., damage to the vessel wall, blood flow turbulence, and hypercoagulability contributing in varying degrees in each patient, but all result in early thrombus interaction with the endothelium [2]. As blood flow slows, oxygen tension declines with a coincident increase in haematocrit [3]. The hypercoagulable microenvironment that ensues may downregulate certain antithrombotic proteins that are preferentially expressed on venous valves including thrombomodulin and Endothelial Protein C Receptor (EPCR) [4]. In addition to reducing important anticoagulant proteins, hypoxia drives the expression of certain procoagulants. Among these is P-selectin, an adhesion molecule which attracts immunologic cells containing tissue factor to the endothelium [5,6]. It is part of the venous thromboembolic disorders which represent the third most common cause of death [7]. Severe COVID-19 patients are found to have the consistent haemostatic abnormalities like mild thrombocytopenia and increased D-dimer level, which together with the higher rate of mortality, indicate some form of underlying coagulopathy [8]. Therefore, severe COVID-19 positive patients are more prone for venous thromboembolic events and the same was perceived by clinicians on the field.

Deep Vein Thrombosis (DVT) and pulmonary emboli are common and often silent and thus go undiagnosed, therefore the incidence and prevalence is often underestimated. Morbidity can be reduced only through early diagnosis and treatment. Venous duplex ultrasound examination not only helps in determination of the presence of a thrombus but also evaluation of the extent of the thrombus (particularly its upper limit), its age (of prognostic interest), and its attachment to the venous wall (partially or totally occlusive thrombus, attached or free floating thrombus [9]). The primary diagnostic US criteria for acute DVT remains non compressibility of the vein with secondary diagnostic criteria being echogenic thrombus within the vein lumen, venous distention, complete absence of spectral or colour Doppler signal within the vein lumen, loss of flow phasicity, and loss of response to valsalva or augmentation [10]. US can also be used to differentiate acute from chronic thrombus. In acute thrombosis, vein is distended by hypoechoic thrombus and shows partial or no compressibility without collaterals. In chronic thrombosis, the vein is incompressible, narrow and irregular and shows echogenic thrombus attached to the venous walls with development of collaterals.

Advantages of lower extremity venous duplex US are that it is readily available, quick, cost-effective, non invasive, devoid of ionising radiation, lacks need for intravenous contrast and can be portable for critically ill patients prone for developing DVT. The present study aimed to evaluate the prevalence of DVT in lower limbs of COVID-19 patients with high levels of D-dimer by colour doppler ultrasound.

## MATERIALS AND METHODS

A time-bound, hospital-based prospective cohort study was conducted in the Department of Radiodiagnosis, MY Hospital, Indore, Madhya Pradesh, India from March 2021 to February 2022. Institutional Scientific and Ethical Committee approval was obtained (EC/MGM/June-21/21).

**Inclusion criteria:** Clinically mild to severe COVID-19 positive patient diagnosis made by Reverse Transcription-Polymerase Chain Reaction (RT-PCR), patients with elevated D-dimer level >0.5 ng/mL by fragment D-dimer test, patients of age between 18 years and 90 years and patients who gave informed consent were included in the study.

**Exclusion criteria:** Patients having history of DVT of lower limbs, pregnant females and patients receiving therapeutic dose of anticoagulants for DVT were excluded from the study.

### Study Procedure

Mild category included patients with various COVID-19 symptoms but no dyspnea or abnormal chest imaging, Moderate category included patients with abnormal chest imaging but SpO<sub>2</sub> >94% on room air and severe category included patients with SpO<sub>2</sub> <94% on room air and respiratory rate >30/min or respiratory failure or multiorgan dysfunction [11].

Lower extremity venous duplex US combines two components to assess for DVT i.e., B-mode or gray-scale imaging with transducer compression maneuvers and Doppler evaluation consisting of colour flow doppler imaging.

The patient was appropriately positioned and gel was applied to the groin. A high frequency linear-array transducer (7-13 MHz) that provides adequate penetration and high resolution image was used and scanning was done both in transverse and longitudinal planes. The probe was laid transversely at the inguinal ligament, identifying the common femoral artery and Common Femoral Vein (CFV). The veins were compressed at this site to assist in identification. Colour mode and doppler mode was used to differentiate between arterial and venous flow. Veins were followed distally, compressing every one centimetre.

The popliteal vein was assessed by placing the transducer transversely on the posterior knee. The popliteal vein can be identified in the proximal popliteal fossa with the knee flexed at 10 degrees to 30 degrees.

## STATISTICAL ANALYSIS

Data recorded were tabulated in Microsoft Excel sheet for analysis. Statistical Package for the Social Sciences (SPSS) software version 25.0 was used to analyse the data. Mean and standard deviation of the quantitative variables were calculated.

## RESULTS

A total of 2200 COVID-19 positive patients with elevated D-dimer levels were included, out of which 1144 (52%) were males and 1056 (48%) were females [Table/Fig-1].

Gender	n	Percentage
Male	1144	52%
Female	1056	48%
Total	2200	100%

[Table/Fig-1]: Distribution of patients according to gender.

Most of the patients were in 36-55 year age group. The mean age of the patient was 51.4±17.8 years [Table/Fig-2]. Among all DVT positive patients 52% were males and 48% were females, showing slight male predominance [Table/Fig-3]. The mean age for DVT positive patients was 56.0±12.9 years. The most prevalent age

group was 36-55 years while least prevalent between 19-35 years age [Table/Fig-4]. Fever was seen in 2090 (95%) patients followed by cough in 1166 (53%) patients [Table/Fig-5].

Age (in years)	n	Percentage
19-35	328	15%
36-55	946	43%
56-75	794	36%
>75	132	6%
Total	2200	100%

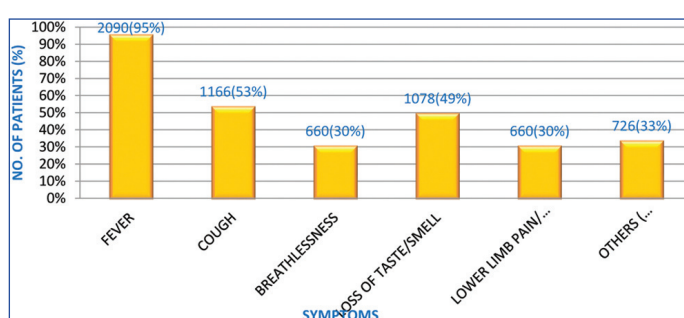
[Table/Fig-2]: Distribution of patients according to age.

Gender	Number of DVT positive patients (n)	Percentage
Male	418	53%
Female	374	47%
Total	792	100%

[Table/Fig-3]: Distribution of DVT positive patients according to gender.

Age (in years)	Patients with positive DVT scan (n)	Percentage
19-35	53	6.7%
36-55	506	63.9%
56-75	176	22.2%
>75	57	7.2%
Total	792	100%

[Table/Fig-4]: Distribution of DVT positive patients according to age.



[Table/Fig-5]: Distribution of patients according to symptoms.

Many of the patients in the present study had co-morbidities, most common of which were diabetes i.e., 770 (35%) patients and hypertension i.e., 522 (23.7%) patients [Table/Fig-6].

Variables	Number of patients (n)	Percentage
Diabetes	770	35%
Hypertension	522	23.7%
CAD	243	11%
COPD	176	8%
CKD	43	2%
CVA	55	2.5%

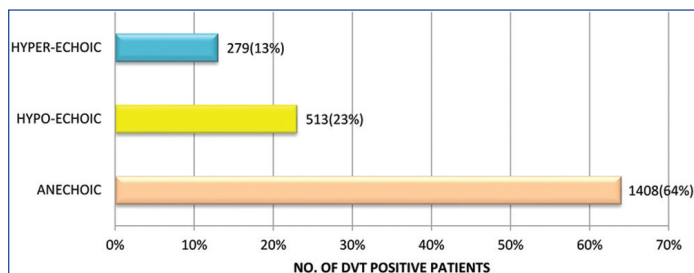
[Table/Fig-6]: Distribution of patients according to co-morbidities.

Majority of the present study group i.e., 992 (45%) patients belong to moderate category followed by 773 (35%) patients to severe category [Table/Fig-7]. Majority i.e., 497 (62.7%) DVT positive patients belong to severe category followed by 286 (36.1%) patients to moderate category and only 9 (1.2%) patients to mild category.

Clinical severity	Total no. of patients	Percentage
Mild	435	20%
Moderate	992	45%
Severe	773	35%
Total	2200	100%

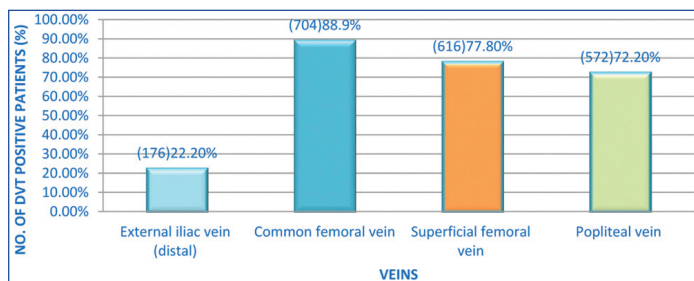
[Table/Fig-7]: Distribution of patients according to clinical severity.

Deep veins of 662 (30%) patients were non compressible whereas, deep veins of 130 (6%) patients were partially compressible and remaining 1408 (64%) showed normal compressibility and partial or absent colour flow was not noted in 792 (36%) patients of the study [Table/Fig-8]. Hypo-echoic thrombus was more common than hyper-echoic thrombus and phasic variation and distal augmentation were absent in thrombosed veins on colour mode.

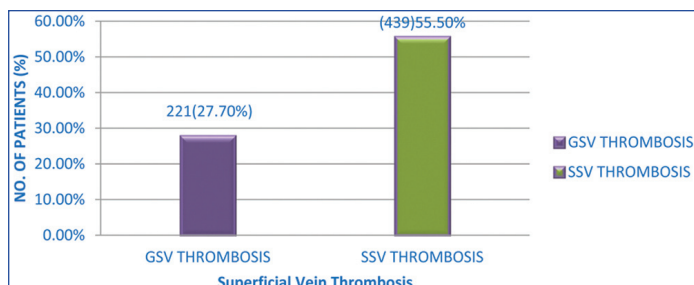


[Table/Fig-8]: Distribution of patients according to gray-scale USG findings.

Out of 2200 patients, 792 (36%) patients showed presence of DVT. Most commonly affected vein in DVT was CFV, 704 (88.9%) [Table/Fig-9]. Superficial veins thrombosis is also associated with DVT, Short Saphenous Vein (SSV), 439 (55.4%) more than Great Saphenous Vein (GSV), 221 (27.9%) [Table/Fig-10].

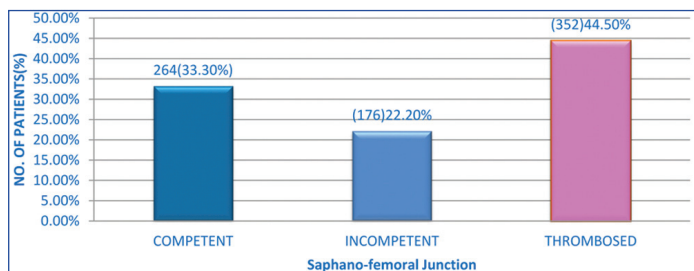


[Table/Fig-9]: Distribution of patients according to thrombosed veins.



[Table/Fig-10]: Distribution of patients according to thrombosed superficial veins.

Saphenofemoral Junction (SFJ) thrombosis was commonly seen in 352 (44.5%) DVT positive patients [Table/Fig-11]. Lower limb oedema was seen in 453 (57%) DVT positive patients. Collaterals were noted in very few i.e., 24 (3%) DVT positive patients.

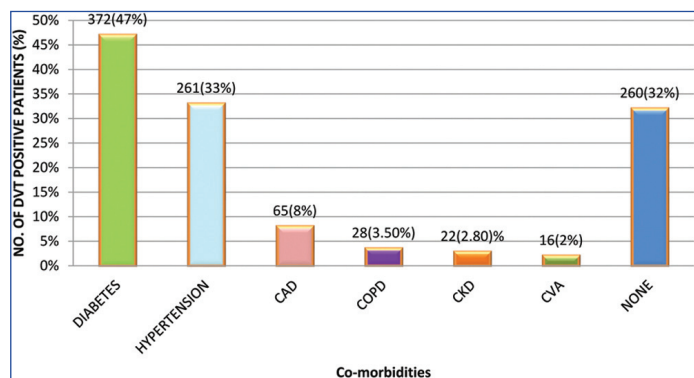


[Table/Fig-11]: Distribution of patients according to Saphenofemoral Junction (SFJ).

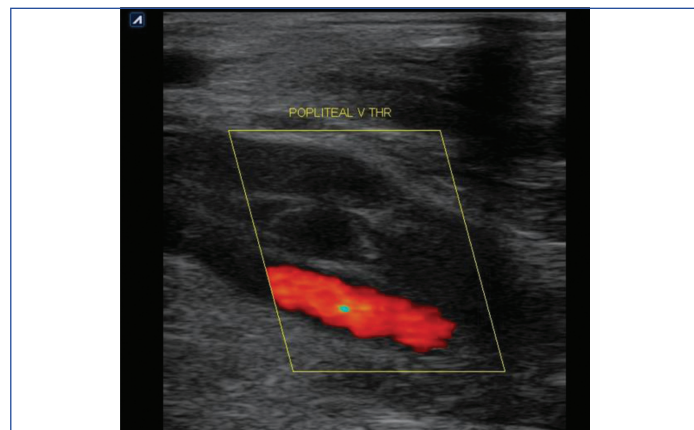
Majority of DVT positive patients were suffering with hypertension 261 (33%) and diabetes 372 (47%) [Table/Fig-12].

Colour doppler mode longitudinal scan showing partially occluding hypoechoic (acute) thrombus in the popliteal vein with increased vein diameter [Table/Fig-13]. Transverse colour mode scan showing

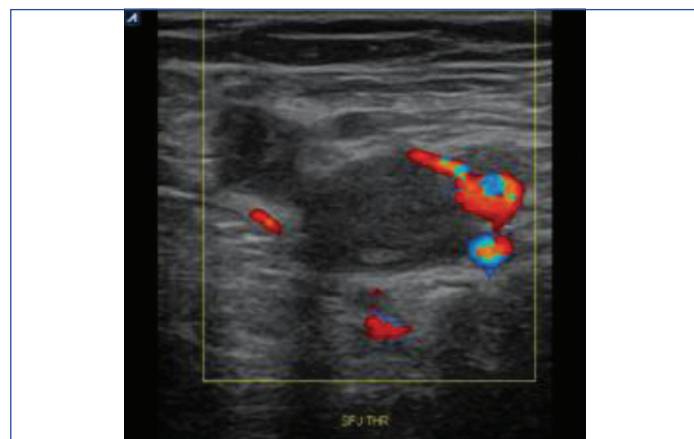
echogenic lumen (subacute thrombus) and complete absent colour flow in CFV and GSV involving saphenofemoral junction [Table/Fig-14].



[Table/Fig-12]: Distribution of DVT positive patients according to co-morbidities.



[Table/Fig-13]: A 55-year-old male presented with lower limb pain and swelling. Longitudinal colour mode image shows hypoechoic thrombus in the popliteal vein with increased vein diameter- partially occluding acute thrombus.



[Table/Fig-14]: A 49-year-old female presented with tender leg swelling. Transverse colour mode image showing echogenic lumen and complete absent colour flow in Common Femoral Vein (CFV) and Great Saphenous Vein (GSV) involving saphenofemoral junction- subacute thrombus.

## DISCUSSION

A total of 2200 COVID-19 positive adults were included in the present study comprising 1144 (52%) males and 1056 (48%) females, males were affected with COVID-19 slightly more than females. This might be as a result of the X chromosome's protection and sex hormones [12].

The total mean age for the subjects was 51.4±17.8 years. The mean age of population in present study was less than those conducted by Nopp S et al., and Weinberg I et al., in which mean age was found to be 62.6 years and 62±15 years, respectively [13,14].

Current study shows that the most experienced symptoms in COVID-19 patients were fever and cough due to cytokine storm. Fever was seen in 2090 (95%) patients followed by cough in 1166 (53%) patients. This was in accordance with study done by Alimohamadi

Y et al., who also found that most common symptoms in COVID-19 patients were fever in 81.2% and cough in 58.5% patients [15].

Many of the patients in the present study had co-morbidities, the most common of which were diabetes i.e., 770 (35%) patients, and hypertension i.e., 522 (23.7%) patients. The diabetic population is more susceptible to infection, due to the associated lymphopenia and to the exaggerated inflammatory response associated with an increased Renin-Angiotensin System (RAS) activation in several tissues [16]. It is possible for hypertensives to have lower ACE2 expression, which, when bound by SARS-CoV-2, attenuates any remaining ACE2 and causes angiotensin-II levels to rise, causing COVID-19 [17].

On gray-scale ultrasound, lumen was found anechoic in 1408 (64%) patients, hypoechoic in 513 (23%) patients and hyperechoic in 279 (13%) patients. It is possible to distinguish between acute and chronic thrombus using US. In acute thrombosis, the vein exhibits partial or no compressibility in the absence of collaterals and is engorged by a hypoechoic thrombus. Chronic thrombosis results in a vein that is incompressible, uneven, and narrow, as well as an echogenic thrombus adhered to the venous walls [18].

In the present study, deep veins were completely compressible in 662 (83.5%) patients, partially compressible in 130 (16.5%) patients, and the remaining 1408 (64%) patients showed normal compressibility. The basic US diagnostic standard for acute DVT is still the vein's non compressibility. A vein with acute thrombosis exhibits limited or no compressibility and is dilated by a hypoechoic thrombus. The vein with chronic thrombosis is incompressible, uneven, and narrow. Additional diagnostic criteria include venous distention, loss of flow phasicity, echogenic thrombus inside the vein lumen, total absence of spectral or colour doppler signal within the vein lumen, and loss of responsiveness to valsalva or augmentation [19].

Normal colour flow was noted in 1408 (64%) patients and partial colour flow noted in 130 (6%) patients and absent colour flow was not noted in 662 (30%) patients of the present study. Lower limb DVT typically manifests in the acute stage with venous distension and absent or partial colour flow depending on the extent of the thrombus and vessel lumen obstruction [19,20]. Oedema was noted in 638 (29%) COVID-19 patients, out of which 462 (21%) patient were associated with thrombosis. In the weeks following a DVT, the process of vein recanalisation, related mediators of inflammation and damage to venous valves cause valvular incompetence (reflux). Venous hypertension brought on by prolonged venous blockage and valvular incompetence causes oedema in a study by Meissner MH et al., [21].

In current study, isolated DVT was found in 132 (16.7%) patients, most commonly affecting CFV in 704 (88.9%) patients followed by Superficial Femoral Vein (SFV) in 616 (77.7%) patients and popliteal vein in 572 (72.2%) patients. Alshoabi SA and Mothanna A found in his study that CFV and SFV were the most common affected veins [19]. Khaladkar SM et al., also found in their study that thrombosis was localised to the SFV in 69 (85.2%) patients, CFV in 57 (70.3%) patients, popliteal vein in 54 (66.66%) patients [22].

Along with DVT, superficial vein involvement was seen in 660 (83.3%) patients most commonly affecting SSV in 439 (55.4%) patients followed by GSV in 221 (27.9%) patients. In many of them, thrombus seem extending from the femoral vein into the GSV and from the popliteal vein into the SSV. Leon L et al., found that the presence of DVT in association with saphenous thrombosis ranges from 6% to 53%. Thrombus propagation can occur in a contiguous and in a non contiguous fashion [23].

Thrombosis of SFJ was noted in 352 (44.5%) patients. DVT can develop contiguously with superficial thrombosis via the SFJ. It can also develop independently in a deep vein without direct extension from the superficial vein, in a non contiguous manner. Ascer E

et al., results demonstrated a 40% incidence of DVT occurring synchronously with SFJ thrombosis [24].

DVT was detected in 792 of 2200 patients. The prevalence of DVT in the present study was found to be 36%. The prevalence in the present study is comparable to the studies of Rouyer O et al., i.e., 38.5% [25]. It came out to be less than the studies of Trigonis RA et al., i.e. 42.2%, while it was more than those conducted by Riyahi S et al., i.e. 14%, Demelo-Rodríguez P et al., i.e., 14.7%, Weinberg I et al., i.e., 20%, Tan BK et al., i.e., 14.7% and Boonyawat K et al., i.e., 28% [14,26-30]. Various studies were compared with the present study [Table/Fig-15] [14,25-30]. This difference could be because of ethnic and racial differences, socio-economic disparities, vaccination coverage, healthcare facilities, etc.

Studies	Prevalence
Present study	36%
Rouyer O et al., (2020) [25]	38.5%
Trigonis RA et al., (2020) [26]	42.2%
Riyahi S et al., (2020) [27]	14%
Demelo-Rodríguez P et al., (2020) [28]	14.7%
Weinberg I et al., (2020) [14]	20%
Tan BK et al., (2020) [29]	14.7%
Boonyawat K et al., (2020) [30]	28%

**[Table/Fig-15]:** Prevalence of DVT in various studies [14,25-30].

In present study, the mean age for DVT positive patients was 56.0±12.9 years. Age-specific risk factors of thrombosis, i.e., presence of co-morbidities, endothelial dysfunction and frailty may be important in the explanation of the increased incidence of DVT in the elderly. It is proposed by Cushman M that venous thrombosis is a disease of aging, with a low rate before the fourth decade of life, rising rapidly after age 45 years [31].

Among DVT positive patients, males (53%) were affected slightly more than females (47%). Venous thrombosis rates are slightly higher in men than women due to various reasons the most potent of these are genetic factors, co-morbidities and smoking as mentioned in a study by Previtali E et al., [32].

Many patients with DVT were co-morbid, most common of which were diabetic i.e., 372 (47%) patient and hypertensive i.e., 261 (33%) patients. The risk of venous thromboembolism appears to be elevated in diabetic patients. Increased thrombin generation and higher concentration of procoagulant cell-derived circulating microparticles in patients with diabetes suggest that hypercoagulability may play an important pathogenic role in the increased frequency of venous thromboembolism. A study by Piazza G et al., stated 2-fold increase risk of venous thromboembolism in patients with diabetes identifies the diabetic population as being particularly vulnerable to initial venous thromboembolism and disease recurrence [33]. Du Y et al., stated 3.12-fold increase risk of venous thromboembolism in old age with hypertension [34].

Prevalence of DVT among COVID-19 positive patients was found to be 36%. Patients having severe clinical grade, Diabetes mellitus and hypertension were most common to develop DVT.

### Limitation(s)

The results cannot be generalised to the whole population as the study was carried out in a single-centre.

### CONCLUSION(S)

With decreased immobility, there is sharp increase in incidence of DVT among severe COVID-19 positive patients. Therefore, it becomes important to provide such patients a non invasive and accurate method which allows early diagnosis. Current study showed significant improvement in the diagnosis of DVT in COVID-19 positive patients by ultrasound using compression and colour doppler technique.

## REFERENCES

- [1] Hansen AT, Juul S, Knudsen UB, Hvas AM. Low risk of venous thromboembolism following early pregnancy loss in pregnancies conceived by IVF. *Hum Reprod.* 2018;33(10):1968-72.
- [2] Carroll BJ, Piazza G. Hypercoagulable states in arterial and venous thrombosis: When, how, and who to test? *Vasc Med.* 2018;23(4):388-99.
- [3] Hamer JD, Malone PC, Silver IA. The PO2 in venous valve pockets: Its possible bearing on thrombogenesis. *Br J Surg.* 1981;68:166-70. Doi: 10.1002/bjs.1800680308.
- [4] Brooks EG, Trotman W, Wadsworth MP, Taatjes DJ, Evans MF, Littleman FP, et al. Valves of the deep venous system: An overlooked risk factor. *Blood.* 2009;114:1276-79. Doi: 10.1182/blood-2009-03-209981.
- [5] Myers DD, Hawley AE, Farris DM, Wroblewski SK, Thanaporn P, Schaub RG, et al. P-selectin and leukocyte microparticles are associated with venous thrombogenesis. *J Vasc Surg.* 2003;38:1075-89. Doi: 10.1016/S0741-5214(03)01033-4.
- [6] Closse C, Seigneur M, Renard M, Pruvost A, Dumain P, Belloc F, et al. Influence of hypoxia and hypoxia-reoxygenation on endothelial P-selectin expression. *Thromb Res.* 1997;85:159-64. Doi: 10.1016/S0049-3848(96)00233-2.
- [7] Naringrekar H, Sun J, Ko C, Rodgers SK. It's not all deep vein thrombosis: Sonography of the painful lower extremity with multimodality correlation. *J Ultrasound Med.* 2019;38(4):1075-89.
- [8] Lippi G, Favaloro EJ. D-dimer is associated with severity of coronavirus disease 2019 (COVID-19): A pooled analysis. *Thromb Haemost.* 2020;120(5):876-78.
- [9] Twigg SJ, McCrirrick A, Sanderson PM. A comparison of post mortem findings with post hoc estimated clinical diagnosis of patients who die in a United Kingdom intensive care unit. *Intensive Care Med.* 2001;274:706-10.
- [10] Forbes K, Stevenson AJ. The use of power Doppler ultrasound in the diagnosis of isolated deep venous thrombosis of the calf. *Clin Radiol.* 1998;53:752-54. Doi: 10.1016/S0009-9260(98)80318-8 pmid:9817093.
- [11] COVID-19 Treatment Guidelines Panel. Coronavirus Disease 2019 (COVID-19) Treatment Guidelines. National Institutes of Health. Available at: <https://www.covid19treatmentguidelines.nih.gov/>. Accessed [9 December 2020].
- [12] Patanavanich R, Glantz SA. Smoking is associated with COVID-19 progression: A meta-analysis. *Nicotine Tob Res.* 2020;22:1653-56.
- [13] Nopp S, Moik F, Jilma B, Pabinger I, Ay C. Risk of venous thromboembolism in patients with COVID-19: A systematic review and meta-analysis. *Research and Practice in Thrombosis and Haemostasis.* 2020;4(7):1178-91.
- [14] Weinberg I, Fernández-Capitán C, Quintana-Díaz M, Demelo-Rodríguez P, De Casasola Gg, Fidalgo Á, et al. Systematic testing for venous thromboembolism in hospitalized patients with COVID-19 and raised D-dimer levels. *Thrombosis Update.* 2021;2:100029.
- [15] Alimohamadi Y, Sepandi M, Taghdir M, Hosamirudsari H. Determine the most common clinical symptoms in COVID-19 patients: A systematic review and meta-analysis. *Journal of Preventive Medicine and Hygiene.* 2020;61(3):E304.
- [16] Candido R, Jandeleit-Dahm KA, Cao Z, Nesteroff SP, Burns WC, Twigg SM, et al. Prevention of accelerated atherosclerosis by angiotensin-converting enzyme inhibition in diabetic apolipoprotein E-deficient mice. *Circulation.* 2002;106(2):246-53.
- [17] Henry BM, Vikse J. Clinical characteristics of COVID-19 in China. *N Engl J Med.* 2020;382(19):1860-61.
- [18] Tapson VF, Carroll BA, Davidson BL, Elliott CG, Fedullo PF, Hales CA, et al. The diagnostic approach to acute venous thromboembolism, clinical practice guideline American thoracic society. *Am J Respir Crit Care Med.* 1999;160:1043-66. Doi: 10.1164/ajrccm.160.3.16030.
- [19] Alshoabi SA, Mothanna A. Deep venous thrombosis: Commonly affected veins in the lower limbs. *Journal of Biosciences and Medicines.* 2019;7(3):12-19.
- [20] Kassai B, Boissel JP, Cuherat M, Sonie S, Shah NR, Leizorovicz A. A systematic review of the accuracy of ultrasound in the diagnosis of deep venous thrombosis in asymptomatic patients. *Thromb Haemost.* 2004;91:655-66.
- [21] Meissner MH, Wakefield TW, Ascher E, Caprini JA, Comerota AJ, Eklof B, et al. Acute venous disease: Venous thrombosis and venous trauma. *Journal of Vascular Surgery.* 2007;46(6):S25-53.
- [22] Khaladkar SM, Thakkar DK, Shinde K, Thakkar DK, Shrotri H, Kulkarni VM. Deep vein thrombosis of the lower limbs: A retrospective analysis of doppler ultrasound findings. *Medical Journal of Dr. D.Y. Patil Vidyapeeth.* 2014;7:612-19.
- [23] Leon L, Giannoukas AD, Dodd D, Chan P, Labropoulos N. Clinical significance of superficial vein thrombosis. *European Journal of Vascular and Endovascular Surgery.* 2005;29(1):10-17.
- [24] Ascer E, Lorensen E, Pollina RM, Gennaro M. Preliminary results of a nonoperative approach to saphenofemoral junction thrombophlebitis. *Journal of Vascular Surgery.* 1995;22(5):616-21.
- [25] Rouyer O, Pierre-Paul IN, Balde AT, Jupiter D, Bindila D, Geny B, et al. High prevalence of deep venous thrombosis in non severe COVID-19 patients hospitalized for a neurovascular disease. *Cerebrovascular Diseases Extra.* 2020;10(3):174-80.
- [26] Trigonis RA, Holt DB, Yuan R, Siddiqui AA, Craft MK, Khan BA, et al. Incidence of venous thromboembolism in critically ill coronavirus disease 2019 patients receiving prophylactic anticoagulation. *Critical Care Medicine.* 2020 Jun 6.
- [27] Riyahi S, Hectors SJ, Prince MR, Sweeney EM, Lane EG, Honya R, et al. Predictors of acute deep venous thrombosis in patients hospitalized for COVID-19. *Medicine.* 2021;100(38):e27216.
- [28] Demelo-Rodríguez P, Cervilla-Muñoz E, Ordieres-Ortega L, Parra-Virto A, Toledano-Macías M, Toledo-Samaniego N, et al. Incidence of asymptomatic deep vein thrombosis in patients with COVID-19 pneumonia and elevated D-dimer levels. *Thrombosis Research.* 2020;192:23-26.
- [29] Tan BK, Mainbourg S, Friggeri A, Bertolotti L, Douplat M, Dargaud Y, et al. Arterial and venous thromboembolism in COVID-19: A study-level meta-analysis. *Thorax.* 2021;76(10):970-79.
- [30] Boonyawat K, Chantrathammachart P, Numthavaj P, Nanthatanti N, Phusanti S, Phuphuakrat A, et al. Incidence of thromboembolism in patients with COVID-19: A systematic review and meta-analysis. *Thrombosis Journal.* 2020;18(1):01-02.
- [31] Cushman M. Epidemiology and risk factors for venous thrombosis. *In Seminars in Hematology.* 2007;44(2):62-69. WB Saunders.
- [32] Previtali E, Bucciarelli P, Passamonti SM, Martinelli I. Risk factors for venous and arterial thrombosis. *Blood Transfusion.* 2011;9(2):120.
- [33] Piazza G, Goldhaber SZ, Kroll A, Goldberg RJ, Emery C, Spencer FA. Venous thromboembolism in patients with diabetes mellitus. *The American Journal of Medicine.* 2012;125(7):709-16.
- [34] Du Y, Zhou N, Zha W, Lv Y. Hypertension is a clinically important risk factor for critical illness and mortality in COVID-19: A meta-analysis. *Nutrition, Metabolism and Cardiovascular Diseases.* 2021;31(3):745-55.

### PARTICULARS OF CONTRIBUTORS:

1. Associate Professor, Department of Radiodiagnosis, MGM Medical College, Indore, Madhya Pradesh, India.
2. Professor and Head, Department of Radiodiagnosis, MGM Medical College, Indore, Madhya Pradesh, India.
3. Postgraduate Resident, Department of Radiodiagnosis, MGM Medical College, Indore, Madhya Pradesh, India.
4. Postgraduate Resident, Department of Radiodiagnosis, MGM Medical College, Indore, Madhya Pradesh, India.

### NAME, ADDRESS, E-MAIL ID OF THE CORRESPONDING AUTHOR:

Dr. Aksha Tanwani,  
Postgraduate Resident, Department of Radiodiagnosis, MGM Medical College,  
Indore, Madhya Pradesh, India.  
E-mail: akshatanwani@gmail.com

### PLAGIARISM CHECKING METHODS: [Jain H et al.]

- Plagiarism X-checker: Dec 26, 2022
- Manual Googling: Feb 11, 2023
- iThenticate Software: Mar 03, 2023 (20%)

### ETYMOLOGY: Author Origin

### AUTHOR DECLARATION:

- Financial or Other Competing Interests: None
- Was Ethics Committee Approval obtained for this study? Yes
- Was informed consent obtained from the subjects involved in the study? Yes
- For any images presented appropriate consent has been obtained from the subjects. Yes

Date of Submission: **Dec 24, 2022**

Date of Peer Review: **Feb 01, 2023**

Date of Acceptance: **Mar 09, 2023**

Date of Publishing: **Apr 01, 2023**