


Focal Nodular Hyperplasia of the Liver without a Central Scar: A Rare Case Report

GYANENDRA SINGH¹, ANURAG SINGH², MANOJ JAIN³, TUSHAR KALONIA⁴



ABSTRACT

Focal Nodular Hyperplasia (FNH) is most frequent benign tumour of liver just after the haemangioma, which makes about 3-5% of all primary hepatic tumours. It occurs frequently in females during their middle age group. This is case report of 48-year-old female patient having complaints of upper abdominal pain since last one year. Using abdominal ultrasonography and a CT scan, it was discovered that segment four of the liver contained a tumour measuring 11 cm in maximum diameter without a central scar, which made preoperative imaging scans for FNH difficult to diagnose. Lobectomy of left lobe was done. The gross specimen on cut section revealed a lesion with nodular appearance and absence of any central stellate scar. On the basis of histopathological finding the diagnosis of FNH without central stellate scar was made. To ensure adequate therapy, it is essential to differentiate between FNH and other hyper vascular liver lesions and metastases. Therefore, it is difficult to diagnose FNH before surgery if there are no typical radiological findings. This case report focused on FNH without the usual radiological findings and emphasised its importance to distinguish it from other malignant hyper vascular liver entities.

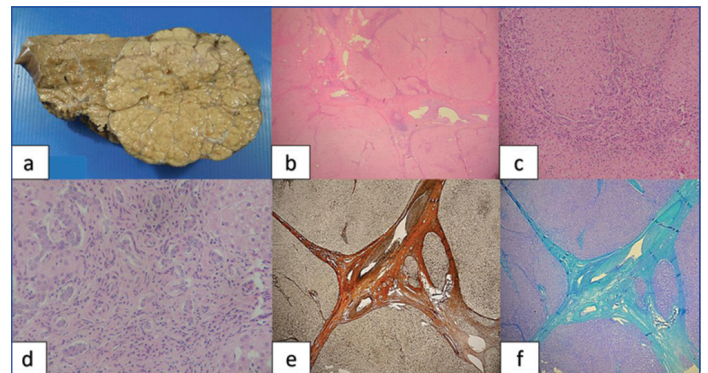
Keywords: Benign lesion, Liver tumour, Special stains

CASE REPORT

A 48-year-old female patient came to the Surgery Outpatient Department (OPD) with the chief complain of upper abdominal pain, which was moderate in intensity, non colicky and continuous with distended abdomen, associated with vomiting and nausea, since last one year. She has been receiving Ayurvedic treatment for the past one year; nevertheless, while some of her symptoms have subsided, she has not seen a full recovery. After one year she was admitted to the hospital. Her blood coagulation index, basic blood tests, alpha fetoprotein, liver function, viral markers were within normal range. Using abdominal ultrasonography and a CT scan, it was discovered that fourth segment of the liver contained a tumour measuring 11 cm in maximum diameter. The lack of central scars or a spoke-wheel appearance made preoperative imaging scans for FNH difficult to diagnose and differential diagnosis of hepatic adenoma and hepatocellular carcinoma were considered on imaging. The left lobe of the liver underwent lobectomy and specimen was sent for histopathological examination.

The gross specimen received was measuring 12.0×7.3×4.9 cm in dimension and 1000 gm in weight. On cut section specimen revealed a lesion with nodular appearance without any central stellate scar [Table/Fig-1a].

On histopathological examination the biopsy shows variable sized nodule separated with fibrovascular septae with interspersed variable sized dilated blood vessels, bile ductules proliferation with presence of fibrous stroma and absence of portal tract within the lesion [Table/Fig-1b-d]. [Table/Fig-1b] shows the hepatic parenchyma with nodular appearance and these parenchymal nodules were separated by bands of fibrous tissue with interspersed variable size dilated blood vessels (2X); c) increase proliferation of bile ductules in fibrous stroma, without any cellular atypic and absence of portal tract (10X); d) increase ductal proliferation displayed at higher magnification (40X). The fibrous septae were highlighted by reticulin stain and Masson trichrome stain as shown in [Table/Fig-1e-f] Reticulin stain highlight the fibrous band (20X); f) Masson's trichrome stain highlight the fibrous senate (20X). The histopathological finding favours the diagnosis of FNH without central stellate scar. A follow-up examination was



[Table/Fig-1]: a) Gross specimen with nodular appearance, b-d) H&E staining showing FNH and e-f) special stains showing fibrous bands.

performed after an interval of three and six months, respectively. After further examination, the patient was found to be in remission, asymptomatic, and free of any recurrence.

DISCUSSION

After cavernous haemangioma, FNH is considered the most common benign, non neoplastic lesion of liver [1]. FNH is a hyperplastic hepatocyte proliferation in response to vascular abnormalities, such as congenital vascular malformations, dystrophic arteries, or damage to the portal system [2]. FNH can be divided into typical and atypical FNH because it typically shows the presence of central stellate scar which is constitute of fibrous connective tissue on histology and Magnetic Resonance Imaging (MRI) [3,4].

In this case report, there was atypical presentation of FNH on imaging study and absence of central scar or other distinctive imaging finding, preoperative identification of localised nodular hyperplasia in the authors instance was challenging. FNH is broadly classified into classical and non classical type. Telangiectatic, hyperplastic and adenomatous, big cell atypia are considered subgroups of classical type. The non classical forms exhibit peculiar traits such cholestasis, Mallory bodies, massive cell alterations, and steatosis. In non classical forms, abnormal architecture or vascular abnormalities may not be present, but the proliferation of bile ductules is consistent finding. The central scar typically consists of mature collagen and

a large number of blood vessels, many of which are medium and large-sized thick-walled arteries that frequently exhibit fibromuscular hyperplasia, myointimal proliferation, and myxomatous change, occasionally with significant luminal narrowing [1].

The authors report a case of FNH which has absence of “central scar” on imaging study and further diagnosis is confirmed by histopathology. FNH is predicted to occur in 0.9% of the general population and accounts for around 8% of all primary hepatic tumors [5]. Although both sexes and all age groups are affected by FNH. Previously published reports find out that FNH is common in women in their third to fifth decades, particularly those in reproductive age and using oral contraceptives [6,7]. This findings are similar to the present case report.

The underlying developmental problem that caused the hyperplasia of the liver parenchyma and the disordered proliferation of the hepatocytes and ducts in response to a localised aggravation of blood in arterial system brought on by an existing vascular anomaly may be the cause of FNH [8]. The condition usually has no symptoms, and it typically manifests as a palpable mass, abdominal pain, or hepatomegaly discovered by accident or during an imaging test ordered for another cause.

Typically, alpha fetoprotein levels are normal and liver function is not hampered. All tests conducted on the current case came back within normal ranges. Findings from imaging tests may help with the diagnosis. For the exact diagnosis of FNH MRI offers the highest percentage of sensitivity and specificity [9]. Histologically, FNH is made up of hyperplastic hepatocyte units that have been cemented together abnormally with dense fibrous tissue. Additionally, the mass has presence of Kupffer cells along with connective tissue, proliferating bile ducts, and a central scar with a stellate layout. A sizable artery that runs through the stellate scar causes sinusoids to become arterialized and hyperperfused [10].

In the present case report, histopathology shows multi-nodular appearance and absence of central scar with hepatic parenchyma showed nodular appearance and these parenchymal nodules were separated by bands of fibrous tissue with interspersed variable size dilated blood vessels, increase proliferation of bile ductules in fibrous stroma, which is highlighted by Masson's trichrome stain. These findings were similar to the previously published study of FNH [11]. One of the key indicators of FNH is the presence of fibrous bands, and Masson's trichrome staining is crucial in making the diagnosis. The dye gives collagen a blue hue against the red of hepatocytes and other structures. It also emphasises the existence and location of reactive fibrosis which could be a consequence of liver injury; this helps to differentiate the patterns of injury and fibrosis such as whether it is perisinusoidal and periductal. Type 1 collagen, which is generally seen in the portal tracts and walls of the blood vessels is also stained [12].

Other hepatic tumours that typically show as single solid lesions are included in the differential diagnosis of FNH, and their differentiation is important due to the variety of therapy options and prognosis. Hepatic adenoma, hepatocellular carcinoma, fibrolamellar hepatocellular carcinoma, hypervascular metastases, haemangiomas, and even focal steatosis should be included in the differential diagnosis. Microscopically, three characteristics are often required to distinguish FNH from other differential diagnosis of hepatic masses: 1) the presence of a central stellate scar; 2) increased in bile ductules proliferation; and 3) the absence of minor cell changes inside the mass [13].

Because FNH is considered a benign lesion, it is best to avoid surgery wherever possible, with individual decisions taken. Although the tumour reduced or even regress spontaneously in some circumstances, most cases of FNH stay stable over time [14]. In the present study case, the preoperative diagnosis of FNH was difficult

with imaging studies because of absence of their characteristic imaging findings such as of central scar. An indication for surgical treatment is the presence of a significant growth in tumour size (when tumour size ≥ 3 -4 cm, or the growth of tumour is >0.5 cm/year). Several studies have found that surgical resection is a successful therapeutic option with high patient satisfaction and a low chance of symptom recurrence [15]. Literature search suggests that in last 10 years two cases reported of same, as depicted in [Table/Fig-2] [16,17].

S. No.	Reference	Age, sex and chief complaints	Follow-up
1	Yoon JH and Kim JY [16]	39-year-old man with a 5-year-history of alcoholism visited hospital presenting with fatigue and dizziness.	FNH showed no change over the 25 months of follow-up on CT.
2.	Yang ZY and Bao GQ [17]	48-year-old woman have complained of intermittent upper abdominal discomfort for >1 year on July 25, 2016. The patient presented with a feeling of distension, no obvious abdominal pain, nausea and vomiting, accompanied by yellowing of the skin and sclera.	According to the results of preoperative pathological examination, the anterior approach was selected to perform partial hepatectomy of the left lobe. The operation was successful, and the patient recovered well after the operation without any recurrence with 4 years follow-up.

[Table/Fig-2]: Cases of FNH without central scar diagnosed in last 10 years [16,17].

CONCLUSION(S)

In the clinical context of an urgent surgical approach and the presence of diagnostic ambiguity, histological investigation is especially helpful in the exact diagnosis of FNH. It is critical to distinguish between FNH and other hypervascular liver lesions such as hepatocellular adenoma and carcinoma, and hypervascular metastases for ensuring adequate treatment. This case report highlighted the significance of differentiating a localised nodular hyperplasia from other malignant hypervascular liver lesions by focusing on it without the normal radiographic signs.

Acknowledgement

We highly acknowledged the support of Department of Pathology and Radiology, SGPGI, Lucknow, India, for their support.

REFERENCES

- Geller SA, de Campos PPF. Focal nodular hyperplasia of the liver. *Autops Case Rep.* 2014;4(4):05-08.
- Oldhafer KJ, Habel V, Horling K, Makridis G, Wagner KC. Benign liver tumors. *Visceral Med.* 2020;36(4):292-303.
- Khanna M, Ramanathan S, Fasih N, Schieda N, Virmani V, McInnes MD. Current updates on the molecular genetics and magnetic resonance imaging of focal nodular hyperplasia and hepatocellular adenoma. *Insights Imaging.* 2015;6(3):347-62.
- Cross S. *Underwood's Pathology: A Clinical Approach*, 7th Edition, Elsevier/Churchill Livingstone, 2019.
- Vilgrain V. Focal Nodular Hyperplasia. *Eur J Radiol.* 2006;58(2):236-45.
- Assy N, Nasser G, Djibre A, Beniashvili Z, Elias S, Zidan J. Characteristics of common solid liver lesions and recommendations for diagnostic workup. *World J Gastroenterol.* 2009;15(26):3217-27.
- Herman P, Pugliese V, Machado MA, Montagnini AL, Salem MZ, Bacchella T, et al. Hepatic adenoma and focal nodular hyperplasia: Differential diagnosis and treatment. *World J Surg.* 2000;24(3):372-76.
- Perrakis A, Vassos N, Grutzmann R, Croner RS. What is changing indications and treatment of focal nodular hyperplasia of the liver. Is there any place for surgery? *Ann Hepatol.* 2017;16(3):333-41.
- Ramírez Fuentes C, Martí-Bonmati L, Torregrosa A, del Val A, Martínez C. Variation in size of focal nodular hyperplasia by magnetic resonance imaging. *Radiology.* 2013;55:499-504.
- Li T, Qin L, Ji Y, Sun HC, Ye QH, Wang L, et al. Atypical hepatic focal nodular hyperplasia presenting as acute abdomen and misdiagnosed as hepatocellular carcinoma. *Hepatol Res.* 2007;37(12):1100-05.
- Balabaud C, Al-Rabih WR, Chen PJ, Evason K, Ferrell L, Hernandez-Prera JC, et al. Focal nodular hyperplasia and hepatocellular adenoma around the world viewed through the scope of the immunopathological classification. *Int J Hepatol.* 2013;2013:268625.
- Krishna M. Role of special stains in diagnostic liver pathology. *Clinical Liver Disease.* 2013;2(1):S8-S10.

- [13] Bonney G, Gomez D, Al-Mukhtar A, Toogood GJ, JPA Lodge, Prasad R. Indication for treatment and long-term outcome of focal nodular hyperplasia. *HPB*. 2007;9(5):368-72.
- [14] Lautz T, Tantemsapya N, Dzakovic A, Superina R. Focal nodular hyperplasia in children: clinical features and current management practice. *J Pediatr Surg*. 2010;45(9):1797-2180.
- [15] Navarro AP, Gomez D, Lamb CM, Brooks A, Cameron IC. Focal nodular hyperplasia: A review of current indications for and outcomes of hepatic resection. *HPB (Oxford)* 2014;16(6):503-11.
- [16] Yoon JH, Kim JY. Atypical findings of focal nodular hyperplasia with gadoxetic acid (Gd-EOB-DTPA)-enhanced magnetic resonance imaging. *Iran J Radiol*. 2014;11(1):e9269.
- [17] Yang ZY, Bao GQ. Focal nodular hyperplasia misdiagnosed as hepatocellular carcinoma: A case report and literature review, 2021 March 30. *Dig Med Res* 2021;4:17.

PARTICULARS OF CONTRIBUTORS:

1. Assistant Professor, Department of Pathology, AIIMS, Rajkot, Gujarat, India.
2. Senior Resident, Department of Pathology, KGMC, Lucknow, Uttar Pradesh, India.
3. Professor, Department of Pathology, SGPGI, Lucknow, Uttar Pradesh, India.
4. Assistant Professor, Department of Pathology, Sharda Hospital, Noida, Uttar Pradesh, India.

NAME, ADDRESS, E-MAIL ID OF THE CORRESPONDING AUTHOR:

Gyanendra Singh,
Assistant Professor, Department of Pathology, AIIMS, Rajkot, Gujarat, India.
E-mail: gyanendra002@gmail.com

PLAGIARISM CHECKING METHODS: [Jain H et al.]

- Plagiarism X-checker: Oct 28, 2022
- Manual Googling: Jan 31, 2023
- iThenticate Software: Feb 11, 2023 (10%)

ETYMOLOGY: Author Origin**AUTHOR DECLARATION:**

- Financial or Other Competing Interests: None
- Was informed consent obtained from the subjects involved in the study? Yes
- For any images presented appropriate consent has been obtained from the subjects. Yes

Date of Submission: **Oct 27, 2022**Date of Peer Review: **Jan 16, 2023**Date of Acceptance: **Feb 13, 2023**Date of Publishing: **Apr 01, 2023**