

Bilateral Congenital Macular Coloboma: A Case Report

MANISHA NADA¹, KIRANMAI GARG², JITENDER PHOGAT³, ANJALI KHAROLIA⁴, SURENDER KUMAR⁵



ABSTRACT

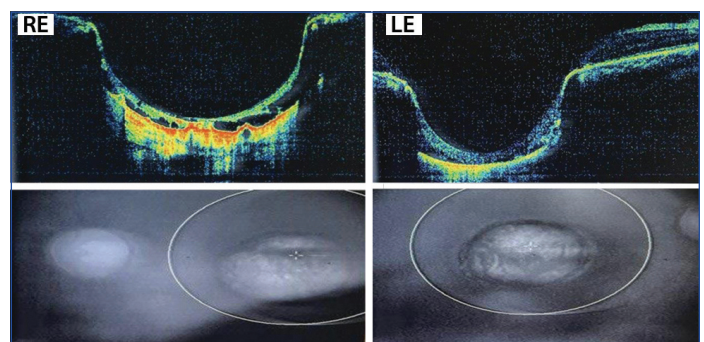
Macular coloboma is a rare disorder with congenital retinochoroidal defect. It has been divided into three categories- Pigmented macular coloboma, non pigmented macular coloboma and macular coloboma with abnormal vessels. Here, the authors present two cases of bilateral congenital macular coloboma. The first case was a 25-year-old male with diminution of vision in both eyes since childhood with no associated family history and no history of any systemic illness. His serological investigations were unremarkable. Case-2 was a nine-year-old male who was accompanied by his mother with vague history of rubbing of both eyes since two months with no significant medical and family history. Patient was found to have diminished vision bilaterally during ophthalmological examination. No evidence of infectious disease could be found on laboratory investigations. Paediatric consultation of the patient was unremarkable. Diagnosis was made after correlating the clinical and Ocular Computed Tomography (OCT) findings. Case-1 is on regular follow-up since three years while Case-2 was lost to follow-up. It is very important to reach at a diagnosis in such cases as there are many conditions which can mimic macular coloboma and treatment modalities vary accordingly. Although visual prognosis in cases of macular coloboma is poor, regular follow-up of the patient is of utmost importance in order to monitor visual acuity and posterior segment for any retinal breaks at the edge of coloboma.

Keywords: Barrage laser, Macular scars, Non pigmented macular coloboma, Pigmented macular coloboma

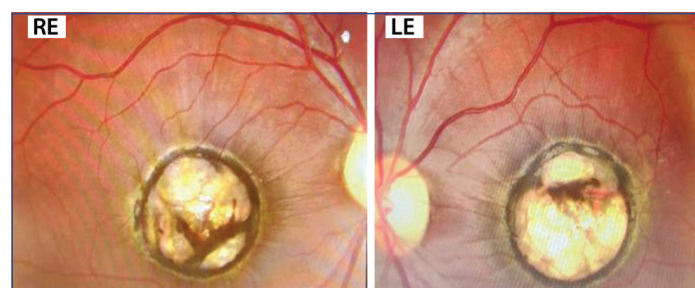
CASE-1

A 25-year-old male presented to ophthalmology department with the chief complaint of diminution of vision in both eyes since childhood. There was no significant history of perinatal infections, trauma or any developmental delay. Family history was not significant. Patient had consultations in the past regarding his complaints but no records were available with the patient. General and systemic examination of the patient was unremarkable. Ocular examination showed best corrected visual acuity of 4/60 in Right Eye (RE) and 5/60 in Left Eye (LE). His eye position was orthophoric and ocular movements were within normal limits. His pupils were isocoric and pupillary reaction to light was prompt in both eyes. Anterior segment was within normal limits bilaterally. Axial length in RE and LE measured 22.48 mm and 22.57 mm, respectively. Posterior segment examination showed a round punched out lesion of around 2DD with line of pigmentation and choroidal vessels at the base in both eyes without scleral ectasia [Table/Fig-1]. Intraocular pressure was 16 mmHg in both eyes. Colour vision of patient was within normal limits. Provisional diagnosis of bilateral macular coloboma was made. Results of laboratory tests which included serum IgG and IgM titres for Toxoplasma, Rubella, Cytomegalovirus and Herpes simplex measured by enzyme linked immunosorbent assay were negative. Treponema pallidum

hemagglutinin test was within normal limits. OCT findings revealed bilateral punched out morphology at the macula with atrophy of neurosensory retina, thus confirming the diagnosis of bilateral pigmented macular coloboma [Table/Fig-2]. Patient was counseled about the poor visual prognosis. No active intervention was done but patient was kept on six monthly follow-up in order to monitor the status of visual acuity and posterior segment. No deterioration of visual acuity or posterior segment status including retinal breaks was noted at 3rd year of follow-up visits.



[Table/Fig-2]: Ocular Computed Tomography (OCT) image of Right Eye (RE) and Left Eye (LE) showing bilateral punched out morphology and atrophy of neurosensory retina at the macula.

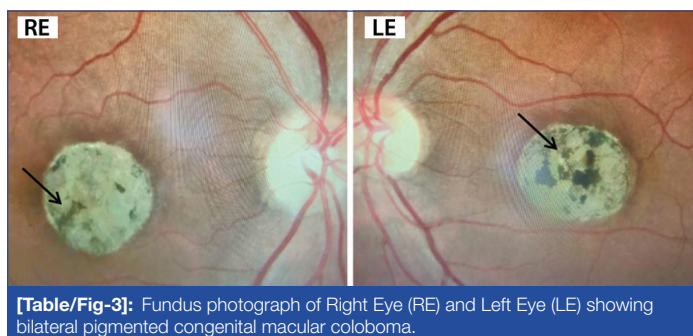


[Table/Fig-1]: Fundus photograph of Right Eye (RE) and Left Eye (LE) showing bilateral pigmented congenital macular coloboma.

CASE-2

A nine-year-old male child presented to outpatient department of ophthalmology with chief complaint of constant rubbing of both eyes since two months. It was associated with history of difficulty in viewing the blackboard in class. No history of deviated eye or abnormal eye movements was reported. The child was born out of non-consanguineous marriage and there was no history of any ocular disease in the family. Perinatal and postnatal period of the child was uneventful with normal developmental milestones. No significant medical and surgical history was reported. General and systemic examination of the patient was

within normal limits. The patient underwent complete ocular examination which showed that his best corrected visual acuity in RE was 6/24 with refractive correction of -3DS -1.5DC at 180° and in LE was 6/60 with refractive correction of -5DS -1DC at 100°. His eye position was orthophoric with normal ocular motility and no evidence of nystagmus. Axial length in RE and LE was 21.35 mm and 21.50 mm, respectively. Anterior segment examination was within normal limits with round, regular and reactive pupils. Fundoscopic evaluation revealed a round macular lesion measuring about 1.5DD bilaterally with non-ectatic sclera and pigment clumps at the base [Table/Fig-3]. Intraocular pressure was 14 mmHg in RE and 16 mmHg in LE. Colour vision was found to be within normal limits bilaterally. Provisional diagnosis of bilateral congenital macular coloboma was made. Paediatric consultation of the patient was done which was unremarkable. Patient was subjected to laboratory investigations which included IgG and IgM titres for Toxoplasma, Rubella, Cytomegalovirus and Herpes simplex which were negative. Treponema pallidum hemagglutinin test was within normal limits. On the basis of clinical findings and after ruling out differentials, a provisional diagnosis of bilateral pigmented macular coloboma was made. Patient was prescribed glasses and parents were counseled about the poor visual prognosis but patient was lost to follow-up for OCT.



[Table/Fig-3]: Fundus photograph of Right Eye (RE) and Left Eye (LE) showing bilateral pigmented congenital macular coloboma.

DISCUSSION

Macular coloboma may be defined as congenital retinochoroidal defect of varying sizes at macular region which manifests as rudimentary or absent retina or choroid at macular region [1,2]. Macular coloboma is a rare disorder with incidence of 0.5-0.7/10,000 live births [3,4]. Both the cases described above were diagnosed as bilateral pigmented macular coloboma [Table/Fig-4] [5]. Macular coloboma with excavation at its base on funduscopy have been reported in literature which was not a feature of this case [6].

Type	Classification	Features
1	Pigmented	Macular lesion with irregularly arranged masses of dense pigmentary tissue with normal choroidal vessels at the base without scleral ectasia
2	Non-pigmented	Punched out sclerotic or pearly white lesion with ectatic base. No choroidal vessels are seen at the base. Thin band of pigmentary tissue may or may not be present surrounding the white edged lesion
3	Macular coloboma associated with abnormal vessels	Vascular anomaly in the form of abnormal anastomosis or vessel passing into vitreous may be present in the white circular patch

[Table/Fig-4]: Classification of macular coloboma [5].

There are various conditions that masquerade macular coloboma, namely Leber's congenital amaurosis, central areolar choroidal atrophy, advanced cone dystrophy, posterior staphyloma and macular scars due to infectious choroiditis [7]. These conditions need to be ruled out before establishing a diagnosis of macular coloboma. There was no serological evidence of contact with Toxoplasma gondii in the index cases, thus ruling out congenital toxoplasmosis. Diminution of vision was present since birth

in both the index cases which is in contrast to central areolar choroidal dystrophy in which case vision would have been normal since late childhood. Also, normal colour vision of the patients in this study rules out possibility of advanced cone dystrophy. Severity of vision loss, associated findings and ophthalmoscopic appearance of the lesion in Case-1 and 2 differentiates it from Leber's congenital amaurosis. Visual prognosis in macular coloboma is usually poor and improvement is unpredictable [3].

Regarding the pathogenesis, two schools of theories have been proposed in literature for macular colobomas, which include developmental and pathological theories [5]. Abnormality of localised part or whole optic cup and primary mesodermal defect are possibilities included in developmental theories while pathological theories indicate that colobomas may be not be truly congenital and may have resulted from intrauterine or infantile choroiditis [5]. Macular colobomatous lesions have familial association as reported in literature but no such association was present in Case-1 and 2 [8].

Macular coloboma may co-occur with other systemic and ocular conditions like Down syndrome, familial hypercalciuria, Michaelis-Menz syndrome and short limb dwarfism [9-11]. No systemic association was seen in both the cases in present manuscript. Macular coloboma was found to associated with cataract in a 11-year-old boy where cataract surgery improved visual acuity to some extent [12].

It is of utmost importance to reach at the diagnosis because the treatment strategies vary accordingly. Barrage laser can be considered in colobomas not involving the macula and papillomacular bundle but has a limited role in preserving vision. Low vision rehabilitation services are to be kept in mind during the rehabilitative management. Regular follow-up is of paramount importance. The visual status in index cases discussed in this manuscript remained unchanged which was comparable to similar cases published earlier [4-6].

CONCLUSION(S)

Macular coloboma is a rare congenital disorder with poor prognosis. Macular coloboma should be suspected whenever any punched out lesion is noted at macular region. Apart from ophthalmic examination, macular coloboma calls for multi-disciplinary approach for the appropriate management of the associated abnormalities. Such cases should be monitored on regular basis in order to monitor status of visual acuity and fundus for any retinal breaks at the edge of the coloboma.

REFERENCES

- [1] Hornby SJ, Adolph S, Gilbert CE, Dandona L, Foster A. Visual acuity in children with coloboma: Clinical features and a new phenotypic classification system. *Ophthalmology*. 2000;107(3):511-20.
- [2] Muñoz de Escalona Rojas JE, Quereda Castañeda A, García García O. Utility of optical coherence tomography in a case of bilateral congenital macular coloboma. *Indian J Ophthalmol*. 2016;64(9):683-85.
- [3] Chang L, Blain D, Bertuzzi S, Brooks BP. Uveal coloboma: Clinical and basic science update. *Curr Opin Ophthalmol*. 2006;17:447-70.
- [4] Miller SA, Bresnik G. Familial bilateral macular coloboma. *Br J Ophthalmol*. 1978;62:261-64.
- [5] Lezrek O, Zerkaoui N, Elorch H, El Kaddoumi M, Benchekroun Belabess S, Cherkoui O, et al. Bilateral macular coloboma. *J Fr Ophtalmol*. 2018;41(5):472-74.
- [6] Khan AO, Patel N, Ghazi NG, Alzahrani SS, Arold ST, Alkuraya FS. Familial non syndromic macular pseudocoloboma secondary to homozygous CLDN19 mutation. *Ophthalmic Genet*. 2018;39(5):577-83.
- [7] Davenport RC. Bilateral "Macular Coloboma" in mother and son. *Proc R Soc Med*. 1927;21(1):109-10.
- [8] Yamaguchi K, Tamai M. Congenital macular coloboma in down syndrome. *Ann Ophthalmol*. 1990;22:222-23.
- [9] Plaza-Ramos P, Tabuenca-Del Barrio L, Zubicoa-Eneriz A, Goldaracena-Tanco B. Michaelis-Manz syndrome. A case report. *An Sist Sanit Navar*. 2018;41:393-96.
- [10] Loh RC, Tan DS. An unusual case of progeria-like dwarfism with bilateral macular coloboma. *Am J Ophthalmol*. 1970;70(6):968-74.

[11] Khan AO, Patel N, Ghazi NG, Alzahrani SS, Arold ST, Alkuraya FS. Familial non syndromic macular pseudocoloboma secondary to homozygous CLDN19 mutation. *Ophthalmic Genet.* 2018;39(5):577-83.

[12] Zhang C, Wu P, Wang L, Gao J, Huang X, Jiang Y. Bilateral congenital macular coloboma and cataract: A case report. *Medicine (Baltimore).* 2019;98(11):e14803.

PARTICULARS OF CONTRIBUTORS:

1. Professor, Department of Ophthalmology, Pt. B.D. Sharma, PGIMS, Rohtak, Haryana, India.
2. Junior Resident, Department of Ophthalmology, Pt. B.D. Sharma, PGIMS, Rohtak, Haryana, India.
3. Professor, Department of Ophthalmology, Pt. B.D. Sharma, PGIMS, Rohtak, Haryana, India.
4. Senior Resident, Department of Ophthalmology, Pt. B.D. Sharma, PGIMS, Rohtak, Haryana, India.
5. Junior Resident, Department of Ophthalmology, Pt. B.D. Sharma, PGIMS, Rohtak, Haryana, India.

NAME, ADDRESS, E-MAIL ID OF THE CORRESPONDING AUTHOR:

Manisha Nada,
22/9 J, Medical Campus, PGIMS, Rohtak, Haryana, India.
E-mail: manisha_nada@rediffmail.com

PLAGIARISM CHECKING METHODS: [\[Jain H et al.\]](#)

- Plagiarism X-checker: Oct 31, 2022
- Manual Googling: Jan 12, 2023
- iThenticate Software: Mar 03, 2023 (5%)

ETYMOLOGY: Author Origin**AUTHOR DECLARATION:**

- Financial or Other Competing Interests: None
- Was informed consent obtained from the subjects involved in the study? Yes
- For any images presented appropriate consent has been obtained from the subjects. Yes

Date of Submission: **Oct 21, 2022**Date of Peer Review: **Dec 21, 2022**Date of Acceptance: **Mar 07, 2023**Date of Publishing: **May 01, 2023**