

# Assessment of Abdominal Aorta Diameter on Contrast-enhanced Computed Tomography: A MDCT-based Observational Study

RAKHEE SHASHIKANT NAIK<sup>1</sup>, U RAGHURAJ<sup>2</sup>

## ABSTRACT

**Introduction:** The average size of the abdominal aorta is less than 3 cm, which varies over time. An increase in abdominal aortic dimensions of more than 3 cm can result in the presence of ectasia, which can further convert into an aneurysm. The expansion rate can also lead to aortic dissection and rupture. Its increasing dimensions can influence to give rise to numerous other abdominal aortic conditions and be fatal due to the aortic wall stress. Monitoring the variation in the abdominal aorta is now possible with the various advancements in imaging techniques including Computed Tomography (CT).

**Aim:** To measure the Anteroposterior (AP) and Right-Left (RL) diameters of the abdominal aorta on Contrast-enhanced Computed Tomography (CECT) abdomen and to analyse its variation with age and gender.

**Materials and Methods:** A cross-sectional observational study was conducted in the Department of Radiodiagnosis at KS Hegde Charitable Hospital, Deralakatte, Mangaluru, Karnataka, India. The duration of the study was 11 months, from April 2020 to March 2021. A total of 81 patients referred for CECT abdomen divided into two age groups of 20-40 years and 41-80 years. The scan was performed using 16-slice Multidetector Computed Tomography (MDCT). On the reconstructed axial

images, the abdominal aortic diameters were measured at the level of T12-L1. The non parametric Mann-Whitney U test was used to compare the RL and AP diameters with respect to age groups. Unpaired t-test was used to compare the RL and AP diameters with respect to gender. Paired t-test was used to compare AP diameter on contrast and non contrast scans.

**Results:** The mean age of study participants was 47±14.83 years and was divided into two age groups between 20-40 years and 41-80 years. Out of the 81 cases, 31 (38%) were in the age group of 20-40 and 50 (62%) were in the age group of 41-80 years. There was a significant increase in the AP and RL abdominal aortic diameter with age (p-value <0.001) and males were found to have significantly higher abdominal aorta diameter than females (p-value <0.001) in both the age groups of 20-40 and 41-80 years. Also, the abdominal aorta diameter measurements on Non Contrast Computed Tomography (NCCT) and CECT abdomen showed no notable difference.

**Conclusion:** The present study concluded that, there was a remarkable variation in the diameter of the abdominal aorta with age and gender. Besides, the abdominal aorta diameter measurements on NCCT and CECT abdomen showed no notable difference.

**Keywords:** Anteroposterior, Contrast-enhanced computed tomography, Non contrast computed tomography

## INTRODUCTION

The abdominal aorta being the largest artery, supplies the abdomen and both lower limbs. Diameter of the abdominal aorta and the characteristics of its walls changes with time. The normal diameter of the abdominal aorta is foreseen to be less than 3 cm. The enlargement rate is around 2.6 mm per year [1]. Several conditions can lead to changing dimensions of the abdominal aorta including atherosclerosis, aortic dissection, aortic rupture, and the most common being the Abdominal Aortic Aneurysm (AAA). More than 3 cm diameter of the abdominal aorta is regarded as an aneurysm and can be potentially lethal [2]. Monitoring and visualisation of the abdominal aorta is now possible with the various advancements in imaging techniques. CT is the most reliable and widely available imaging modality for the evaluation of AAA. With the help of various reformation techniques, software, and measurement tools available in CT, diameters of the abdominal aorta can be measured accurately [3]. NCCT can be used for the detection of vascular calcification [4]. CECT is useful for evaluating luminal and aortic wall abnormalities. A study established that, the measured suprarenal and infrarenal abdominal aorta diameters increased in size with the increasing age of the subjects [5]. Also, in another study, the authors concluded that, there is a high prevalence of AAA in men traced on CT abdomen [6].

In the present study, both AP and RL diameters of the abdominal aorta were measured. Also, the comparison was made between

different age groups and gender on both, NCCT and CECT whereas, in another study, only transverse diameter was taken into consideration and measured only on NCCT [3].

## MATERIALS AND METHODS

A cross-sectional observational study was conducted in the Department of Radiodiagnosis Justice KS Hegde Charitable Hospital attached to KS Hegde Medical Academy, a unit of NITTE (Deemed to be University) Mangaluru, Karnataka, India. The duration of the study was 11 months, from April 2020 to March 2021. The study was approved by Institutional Ethics Committee (Approval no. INST.EC/EC/045/2020-21).

**Inclusion criteria:** All patients referred for CECT abdomen within the age group of 20-80 years were included.

**Exclusion criteria:** Patients with history of cardiac diseases, abdominal trauma, known cases of vasculitis, AAA and history of previous aortic interventions were excluded.

## Study Procedure

The procedure was explained to the subjects and a written informed consent was obtained from each subject. The participants were divided into two age groups under 20-40 years and 41-80 years and gender. CECT abdomen scan was performed using GE Bright Speed Elite (16-slice MDCT machine) and pressure injector (Medrad Salient). The acquired images in the arterial phase were

reconstructed into the three planes (sagittal, axial, and coronal) via the Multiplanar reformation (MPR) technique to 1.25 mm and with the distance measuring tools, the AP and RL abdominal aortic diameters were measured at the level of T12-L1 on both plain and contrast abdominal scans. The variation in the diameter of the abdominal aorta with age and gender was analysed.

### STATISTICAL ANALYSIS

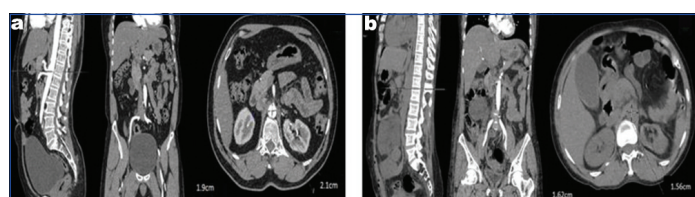
Data collected was analysed by the Statistical Package for Social Science (SPSS) version 20.0 (SPSS-IBM Corporation, New York 2014). The non parametric Mann-Whitney U test was used to compare the RL and AP diameters with respect to age groups. Unpaired t-test was used to compare the RL and AP diameters with respect to gender. Paired t-test was used to compare AP diameter on contrast and non contrast scans. The mean and standard deviation of abdominal aortic measurements were calculated to show the AP and RL diameter variation with age and gender. The p-value<0.001 was considered significant.

### RESULTS

A total of 81 patients with a mean age of 47±14.83 years were divided into two age groups between 20-40 years and 41-80 years. Out of the 81 cases, 31 (38%) were in the age group of 20-40 and 50 (62%) were in the age group of 41-80 years. Also, 48 (59%) were males and 33 (41%) were females in the total. There was a significant difference in the AP and RL diameters measured on both NCCT and CECT between the age groups of 20-40 years and 41-80 years (p-value <0.001). This showed that, the diameter increases with age and was more in the age group of 41-80 years [Table/Fig-1,2a,b].

Abdominal aortic diameter measurements	Age group (years)	Mean (cm)±Standard Deviation (SD)	p-value
AP (NCCT)	20-40	1.42±0.23	<0.001
	41-80	1.72±0.26	
AP (CECT)	20-40	1.41±0.23	<0.001
	41-80	1.7±0.25	
RL (NCCT)	20-40	1.54±0.23	<0.001
	41-80	1.85±0.29	
RL (CECT)	20-40	1.53±0.22	<0.001
	41-80	1.82±0.27	

[Table/Fig-1]: Comparison of AP and RL diameters between the two age categories. Mann-Whitney U test



[Table/Fig-2]: a) AP and RL abdominal aorta diameter measurement on NCCT in the age group of 40-80 years b) and 20-40 years.

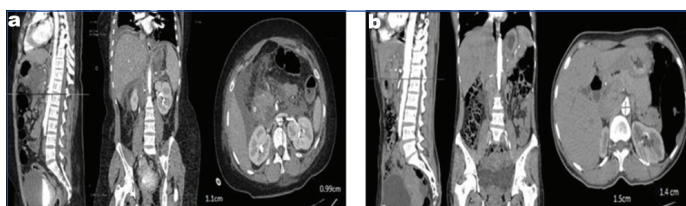
There were 21 males and 10 females in the age group of 20-40 years while there were 27 males and 23 females in the 41-80 years age group. There was a significant difference in the AP and RL abdominal aorta diameter measurements performed on NCCT and CECT abdomen between males and females in the age category of 20-40 years and also, 41-80 years (p-value <0.001). This showed that, males had a larger abdominal diameter than the females of the same age group [Table/Fig-3,4a,b]. Comparing the AP and RL diameters of the abdominal aorta, the authors found that, there was no significant difference in the diameters between the NCCT and CECT measurements (p-value >0.05) [Table/Fig-5].

### DISCUSSION

The CT is a medical imaging modality where digital geometry processing is utilised to create three-dimensional (3D) images

Abdominal aorta diameter measurements	Gender	Mean (cm)±SD (age group 20-40 years)	Mean (cm)±SD (age group 41-80 years)	p-value
AP (NCCT)	Males	1.48±0.18	1.78±0.22	<0.001
	Females	1.30±0.29	1.65±0.30	
AP (CECT)	Males	1.46±0.19	1.78±0.23	<0.001
	Females	1.31±0.28	1.61±0.26	
RL (NCCT)	Males	1.59±0.2	1.93±0.26	<0.001
	Females	1.47±0.27	1.76±0.29	
RL (CECT)	Males	1.56±0.19	1.91±0.25	<0.001
	Females	1.48±0.25	1.73±0.25	

[Table/Fig-3]: Comparison of AP and RL diameters in the two genders in the two age groups of 20-40 and 40-80 years. Unpaired t-test



[Table/Fig-4]: AP and RL abdominal aorta diameter measurement on CECT in a) females b) males.

Abdominal aorta diameter measurements	Mean (cm)±standard deviation	p-value
AP (NCCT)	1.60±0.29	0.82
AP (CECT)	1.59±0.28	
RL (NCCT)	1.74±0.30	0.82
RL (CECT)	1.73±0.29	

[Table/Fig-5]: Comparison of AP and RL diameters on NCCT and CECT abdomen. Paired t-test

of the inner structures of an object. CECT offers radiologists valuable information about not only the abdominal aorta but, also the surrounding structures [3]. Compared to another study, the authors have also measured the abdominal aorta diameters on NCCT, as these images do not have to get interfered with any gastrointestinal gas [7].

In the current study, the authors observed a significant difference in abdominal aorta diameters between the two age groups (p-value <0.001). Similar results were observed in a study by Kumar R et al., consisting of 603 cases in the Nepalese population within the age limit of 21-85 years, the abdominal aorta diameter was measured at three different levels suprarenal, infrarenal and bifurcation and the values were found to be 18.57±2.56, 16.48±2.44 and 15.82±2.29 mm, respectively. They too showed that age has a significant influence on the abdominal aortic diameters which increase with age [8]. Another study by Sharma D et al., included 130 patients who underwent abdominal CT and were divided into two age groups of 20-40 years and 40-80 years. They perceived that, there was a significant difference in the AP and RL diameter between the two age groups (p-value <0.001) and hence, concluded that the size of the abdominal aorta differs with age [9]. In a study by Hawn S et al., 300 patients were enrolled from the Korean population including 150 males and 150 females. They were divided into six age categories 21-30, 31-40, 41-50, 51-60, 61-70 and 71-80 years. Their abdominal aortic measurements were performed at the level of the celiac axis, suprarenal aorta, and aortic bisection, which were found to be 1.98±0.31, 1.84±0.39 and 1.47±0.22 cm in the females while it was 2.21±0.36, 2.04±0.31 and 1.68±0.22 cm in the males respectively [10]. Hence, the abdominal aorta diameter in males was found to be more compared to females (p-value <0.05) which were similar to the present study.

Also, the authors have observed no significant difference in the diameters measured on NCCT and CECT (p>0.05). In a

comparable literature by Nambi P et al., including 316 participants, the average abdominal aortic diameters were measured at the level of the lowest renal artery to the aortic bifurcation on both, NCCT and CECT which were 1.16 and 1.14 cm, respectively. They showed almost similar results to the present study with no significant difference [11]. Hence, this shows that, the abdominal aorta diameter measurements are reproducible on both NCCT and CECT and NCCT can be an alternative to CECT. Espinosa G et al., carried out a study, to compare angiography with CT for evaluation of AAA prior to endograft implant. The study included 113 patients of which 104 were males and 9 were females with AAA. All the participants underwent abdominal spiral CT and catheter angiography. Infrarenal abdominal aorta diameters were measured in both investigations and mean diameters were compared. The authors observed that, there was a statistical difference in the infrarenal aneurysmal neck diameter of the abdominal aorta between the two examinations (p-value <0.05). Therefore, they concluded that, CT was a better method for the evaluation of diameters [12]. Another similar study by Liisberg M et al., was performed to compare NCCT and Ultrasound for AAA screening. The study included 566 men who underwent NCCT and ultrasound examination. In the axis of the abdominal aorta, diameters were measured in anteroposterior and transverse planes. A total of 30 AAA were found using NCCT whereas, ultrasound could not detect nine of these. Also, five additional iliac artery aneurysms were identified by NCCT. They concluded that, NCCT was superior to ultrasound concerning sensitivity since the entire length of the vessel can be evaluated using CT [13].

Hence, the authors considered that, CT is the best modality for the measurement of the abdominal aorta and other large vessels. Also, assessment of variation in the abdominal aorta diameter using CECT abdomen might help in predicting further complications such as AAA and other aortic diseases. Further studies can be performed considering other variable factors for analysing the variation in abdominal aorta diameter like height, weight, patients with hypertension, and history of smoking.

### Limitation(s)

The limitations of the present study include the small sample size.

### CONCLUSION(S)

There was a significant variation in the diameter of the abdominal aorta with age. Besides, the abdominal aorta diameter measurements on

NCCT and CECT abdomen showed no notable difference. Hence, plain CT can undoubtedly be used for diameter measurements. Therefore, CT abdomen can help the radiologist to accurately measure the abdominal aortic diameter, and comparing the values with the standard values will help predict the possibility of progression to AAA.

### Acknowledgement

The authors would like to thank the Department of Radiodiagnosis and Medical Imaging Technology at KS Hegde Medical Academy, Mangaluru, Karnataka, India, for their approval and permission for collecting the data and carrying out the present study without any interruption. The authors also acknowledge the Department of Statistics for its guidance in data analysis and interpretation.

### REFERENCES

- [1] Erbel R, Eggebrecht H. Aortic dimensions and the risk of dissection. *Heart*. 2006;92(1):137-42.
- [2] Aggarwal S, Qamar A, Sharma V, Sharma A. Abdominal aortic aneurysm: A comprehensive review. *Exp Clin Cardiol*. 2011;16(1):11-15.
- [3] Hong H, Yang Y, Liu B, Cai W. Imaging of Abdominal Aortic Aneurysm: the present and the future. *Curr Vasc Pharmacol*. 2010;8(6):808-19.
- [4] Baliyan V, Verdini D, Meyersohn NM. Noninvasive aortic imaging. *Cardiovasc Diagn Ther*. 2018;8(Suppl 1):S3-S18.
- [5] Jasper A, Harshe G, Keshava SN, Kulkarni G, Stephen E, Agarwal S. Evaluation of normal abdominal aortic diameters in the Indian population using computed tomography. *J Postgrad Med*. 2014;60(1):57-60.
- [6] Claridge R, Arnold S, Morrison N, van Rij AM. Measuring abdominal aortic diameters in routine abdominal computed tomography scans and implications for abdominal aortic aneurysm screening. *J Vasc Surg*. 2017;65(6):1637-42.
- [7] Joh JH, Ahn HJ, Park HC. Reference diameters of the abdominal aorta and iliac arteries in the Korean population. *Yonsei Med J*. 2013;54:48-54.
- [8] Kumar R, Rauniyar RK. Normal aortic diameter on multi detector computed tomography in nepalese population of eastern Nepal. *International Journal of Health and Clinical Research*. 2020;4(2):202-08.
- [9] Sharma D, Visakh T. Variation in the size of abdominal aorta measured on computed tomography. *Asian J Pharm Clin Res*. 2018;11(11):146-48.
- [10] Lee SH, Lee W, Choi HJ, Kim DJ, Park E-A, Chung JW, et al. Measurement of the aortic diameter in the asymptomatic Korean population: assessment with multidetector CT. *J Korean Soc Radiol*. 2013;69(2):105-12.
- [11] Nambi P, Sengupta R, Krajoer Z, Muthupillai R, Strickman N, Cheong BYC. Non contrast computed tomography is comparable to contrast-enhanced computed tomography for aortic volume analysis after endovascular abdominal aortic aneurysm repair. *Eur J Vasc Endovasc Surg*. 2011;41(4):460-66.
- [12] Espinosa G, Marchiori E, Silva LF, de Araújo AP, Riguetti C, Baquero RA. Initial results of endovascular repair of abdominal aortic aneurysms with a self-expanding stent-graft. *J Vasc Interv Radiol*. 2002;13(11):1115-23.
- [13] Liisberg M, Diederichsen AC, Lindholt JS. Abdominal ultrasound-scanning versus non contrast computed tomography as screening method for abdominal aortic aneurysm-a validation study from the randomized DANCAVAS study. *BMC Med Imaging*. 2017;17(1):14.

#### PARTICULARS OF CONTRIBUTORS:

1. Lecturer, Department of Radiology, Shridevi Institute of Medical Sciences and Research Hospital, Tumkur, Karnataka, India.
2. Professor and Head, Department of Radiodiagnosis, KS Hegde Medical Academy (Deemed to be University), Deralakatte, Mangaluru, Karnataka, India.

#### NAME, ADDRESS, E-MAIL ID OF THE CORRESPONDING AUTHOR:

Ms. Rakhee Shashikant Naik,  
H. No. M-88, Housing Board Colony, Alto Porvorim, Bardez-403501, Goa, India.  
E-mail: rakheenai510@gmail.com

#### AUTHOR DECLARATION:

- Financial or Other Competing Interests: None
- Was Ethics Committee Approval obtained for this study? Yes
- Was informed consent obtained from the subjects involved in the study? Yes
- For any images presented appropriate consent has been obtained from the subjects. Yes

#### PLAGIARISM CHECKING METHODS: [Jain H et al.]

- Plagiarism X-checker: Jul 06, 2022
- Manual Googling: Dec 08, 2022
- iThenticate Software: Jan 24, 2023 (9%)

#### ETYMOLOGY: Author Origin

Date of Submission: **Jul 05, 2022**  
Date of Peer Review: **Oct 30, 2022**  
Date of Acceptance: **Feb 01, 2023**  
Date of Publishing: **May 01, 2023**