

# Foetal Cardiac Dimensions in 18-40 Weeks of Gestation from Tamil Nadu, India: A Cross-sectional Study

SUNDARA RAJA PERUMAL<sup>1</sup>, LAURA ROSARIO<sup>2</sup>, SENTHIL KUMAR<sup>3</sup>

## ABSTRACT

**Introduction:** Foetal echocardiography helps in the identification of congenital anomalies of the heart and arrhythmias. It is usually done from 18-22 weeks of gestation but it can also be done as early as 12-13 weeks of gestation through transvaginal ultrasound. Measurement of cardiac dimensions in the foetus plays a major role in the early detection of cardiac defects including hypoplastic right and left heart. In addition, the measurement of foetal cardiac dimensions is useful in the evaluation of foetuses with heart failure due to foetal anaemia, which is secondary to Rh alloimmunisation or Bart's disease.

**Aim:** To construct a reference centile curve for foetal cardiac dimensions from 18-40 weeks of gestation for the Indian population residing in Tamil Nadu state.

**Materials and Methods:** This was a cross-sectional study performed between January 2020 and July 2021. A total of 345 antenatal mothers, who came to the Department of Radiology, SRM Medical College and Research Centre, Chennai, India, for routine anomaly and growth scans were included in the study. Cardiac longitudinal and transverse diameters were measured

on 2D images, when the heart was maximally distended in a four-chamber view at the end of the diastole. Left atrial longitudinal and transverse diameters, right atrial longitudinal and transverse diameters, left ventricular longitudinal and transverse diameters, right ventricular longitudinal and transverse diameters, interatrial septum thickness, interventricular septum thickness, cardiac longitudinal and transverse diameters were measured.

**Results:** The mean values at 18 and 40 weeks of gestation for left atrial longitudinal and transverse diameters, right atrial longitudinal and transverse diameters, left ventricular longitudinal and transverse diameters, right ventricular longitudinal and transverse diameters, interatrial septum thickness, interventricular septum thickness, cardiac longitudinal, and transverse diameters were 0.73, 0.65, 0.72, 0.66, 0.83, 0.62, 0.75, 0.62, 0.1, 0.1, 1.71, 1.72 cm and 2.22, 1.71, 2.31, 1.9, 3.21, 1.71, 3.3, 1.84, 0.3, 0.3, 5.02, 3.84 cm, respectively.

**Conclusion:** The normal reference ranges for foetal cardiac dimensions can be a useful tool in the early identification of cardiac remodelling in congenital heart disease.

**Keywords:** Foetal echocardiogram, Four-chamber view, Interatrial septum, Interventricle septum

## INTRODUCTION

Foetal echocardiography helps in identifying congenital heart anomalies and arrhythmias [1]. Out of a thousand live birth two to six foetuses have congenital heart disease and pose significant morbidity and mortality in these children [2]. Environmental, genetic, and chromosomal factors are involved in the occurrence of congenital cardiac anomalies [2]. Cardiac remodelling means the alterations in the heart's shape, structure size, and function in response to insults which occur in foetal life [3]. Various predisposing factors including gestational diabetes, smoking, alcohol, maternal viral infections, medications and exposure to toxins results in congenital heart disease and foetal growth restriction [1]. An adverse event during the development of the foetus can have a major impact on the foetal heart and long-term consequences on the child's health [4]. Measuring foetal cardiac dimensions prenatally helps to detect cardiac defects including hypoplasia of the chambers of the right and left heart [5]. In addition, the measurement of dimensions of the foetal heart is helpful in the identification of foetuses with heart failure due to anaemia in the foetus occurring secondary to Rh factor alloimmunisation and Bart's disease [6]. Enlargement of the right heart is commonly seen in the coarctation of aorta [7]. The increased cardiothoracic ratio is used as a most sensitive sonographic marker in the detection of foetal haemoglobin Bart's disease [8]. The heart is the first organ to develop prenatally and continuously contracts throughout the entire life [4]. Multiple transcription factor networks control the formation of the cardiac chambers during embryonic development [4].

The main ultrasound marker suggestive of a cardiac defect in early gestation is increase in the nuchal translucency of greater of 3 mm

[9]. Evaluation of the pulsatility index of the ductus venosus flow is said to improve the detection of congenital heart defects [10]. Increased pulsatility index is associated with foetal aneuploidy and foetal cardiac defect.

The International Society of Ultrasound in Obstetrics and Gynaecology guidelines in the performance of obstetric ultrasound mandates obtaining four-chamber view along with cardiac outflow tract views in second and third trimester ultrasound scans [11]. Four-chamber view, if obtained alone has a low detection rate for conotruncal anomalies [12]. Detection of congenital heart disease is 55-65% with four-chamber view but increases to 80-84% if outflow tract view is included [13]. Additional views in cardiac ultrasound include aortic arch view, three vessel view, bicaval view and three vessel trachea view [14].

Ultrasound of the foetal heart is a non invasive method and the measurement of foetal heart dimensions helps in the early identification of foetal cardiac remodelling in response to stresses and can be useful in diagnosing the cases of congenital heart disease. The present study provided normal reference ranges for foetal cardiac dimensions from 18-40 week in Indian population of Tamil Nadu region.

## MATERIALS AND METHODS

This cross-sectional study was conducted between January 2020 to July 2021 in the Department of Radiology, SRM Medical College and Research Centre, Chennai, India. Ethical committee clearance was obtained and Ethics clearance number 1819/IEC/2019. A total of 345 antenatal mothers coming to the Department of Radiology for anomaly and growth scans were included in the present study.

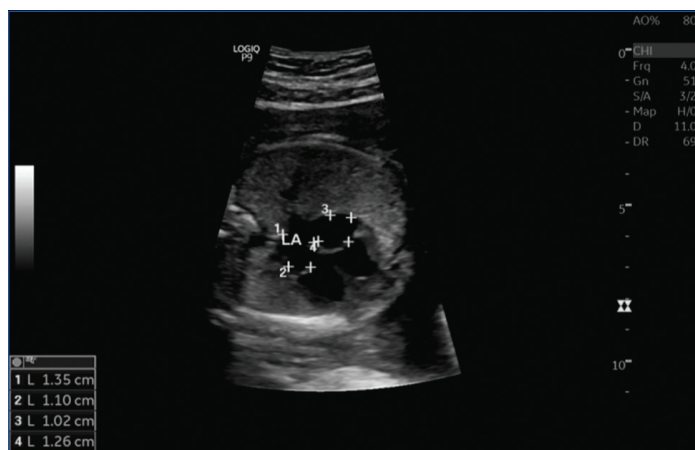
**Inclusion criteria:** Inclusion criteria were normal singleton mothers, antenatal mothers of gestational age 18-40 weeks.

**Exclusion criteria:** Exclusion criteria were intrauterine growth restriction of the foetus, conception through in-vitro fertilisation, exposure to toxins, gestational diabetes, chronic hypertension HIV (Human Immuno-deficiency Virus) infection, foetal malformations and chromosomal abnormalities.

**Study Procedure**

Foetal cardiac ultrasound was performed using 2-6 MHz probe of Philips affinity machine. For the purpose of the study, foetal cardiac ultrasound study was done. The normal foetal biometry parameters including biparietal diameter, head circumference, abdominal circumference and femur length were obtained and the amniotic fluid index was calculated. The foetal heart rate was measured. The four-chamber view was attained by a transverse sweep of the probe through the thorax of the foetus above the level of the diaphragm. The apical four-chamber view was obtained parallel to the interventricular septum. The subcostal four-chamber view was obtained in a plane perpendicular to the interventricular septum. The four-chamber view showed the right and left atria and ventricles and also the atrioventricular valves and septa. The cardiac position and axis were determined in this projection. Longitudinal and transverse diameters of the right ventricle and left ventricle were measured on two-dimensional images of a four-chamber view during end diastole. The transverse diameter was measured at the level below the leaflets of the atrioventricular valve and the longitudinal diameter from the atrioventricular valve to the inner myocardium apex. End diastole was the frame in which closure of the atrioventricular valves occurs and ventricles attain maximum size. Longitudinal and transverse diameters of right and left atrium were measured on two dimensional images when the atria was distended to the maximum during end systole, which is defined at the frame just before the opening of atrioventricular valves. Maximum length of longitudinal and transverse atrial diameter was measured. The atrial measurements do not include the pulmonary veins, pulmonary arteries and annulus of the atrioventricular valves.

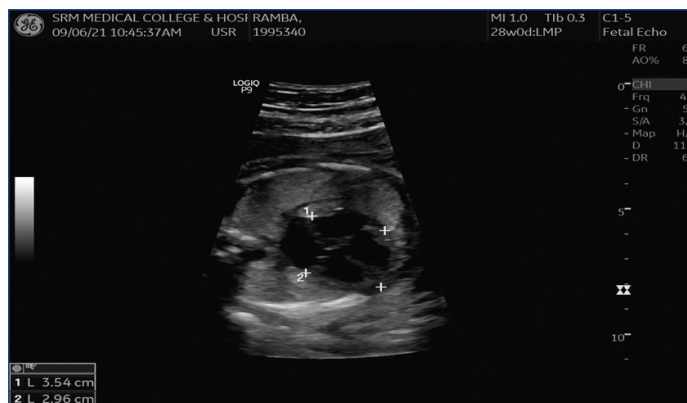Interatrial septal thickness and interventricular septal thickness were measured in 2D images of four-chamber view. Maximum thickness of the septum was measured. Longitudinal and transverse diameter of cardiac dimension were measured on two dimensional images when the heart was maximally distended from a four-chamber view during end diastole, the frame in which closure of the atrioventricular valves occur and ventricles attain in maximum size. Diagrammatic representation of measurement of both ventricle, both atrium and total cardiac dimension were given in [Table/Fig-1-4].



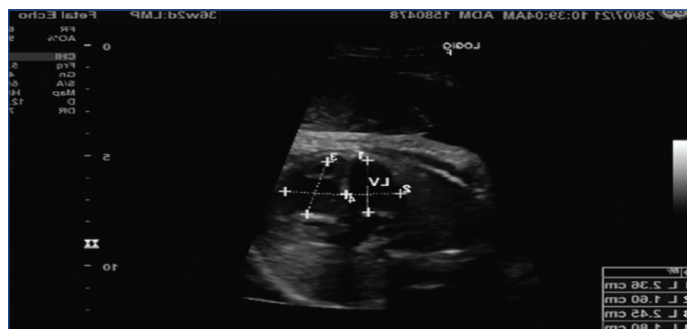
[Table/Fig-1]: Measurement of longitudinal, transverse diameter of left and right atrium.

**STATISTICAL ANALYSIS**

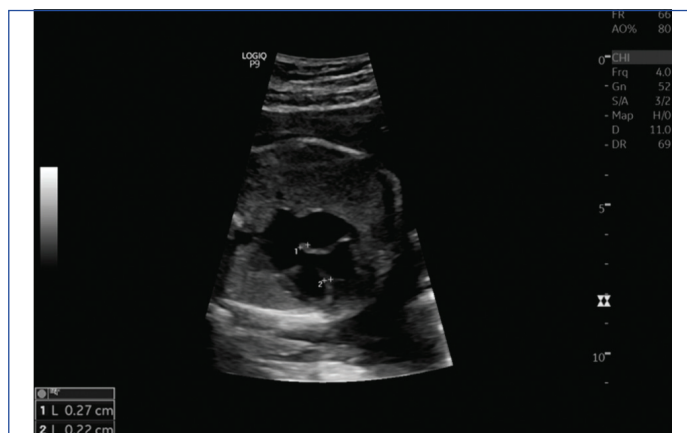Descriptive analysis was carried out by mean and standard deviations for quantitative variables, frequency and proportion for categorical variables. The association between categorical explanatory variables



[Table/Fig-2]: Measurement of total cardiac longitudinal and transverse dimensions in four-chamber view.



[Table/Fig-3]: Show measurement of left and right ventricular transverse and longitudinal diameters in four-chamber view in end diastole.



[Table/Fig-4]: Shows measurement of interatrial and interventricular septal thickness in four-chamber view.

and quantitative outcome was assessed by comparing the mean values. The mean differences along with their 95% Confidence Interval (CI) were presented. Regression coefficient was used to assess to the relationship between the foetal cardiac dimensions and the gestational age. A p-value of less than 0.05 was considered statistically significant. IBM Statistical Package for the Social Sciences, SPSS, version 21.0, was used for statistical analysis.

**RESULTS**

The patient age group was in the range of 18-35 years. The youngest patient was 18-year-old and the oldest patient was 35-year-old. Median age group was around 25 years of age. The maximum number of patients was within the age group of 21-25 years accounting to 45.21% of the total cases [Table/Fig-5].

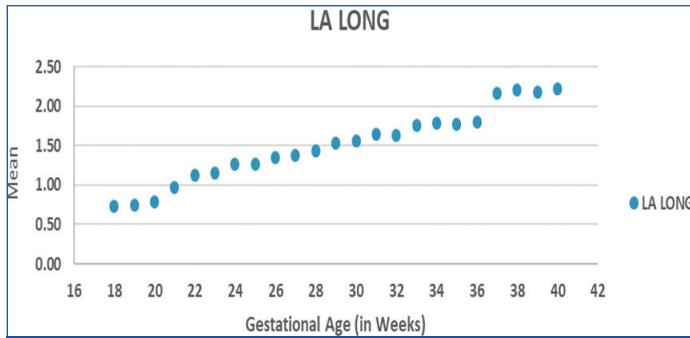
Age (years)	Frequency (n)	Percentage (%)
<20	39	11.32%
20-25	156	45.21%
26-30	105	30.43%
31-35	45	13.04%

[Table/Fig-5]: Descriptive analysis for frequency of maternal age in study population.

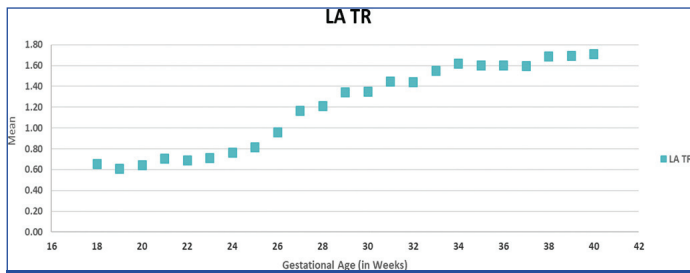
Of the 345 antenatal mothers included in the present study, 87 mothers were primigravida and 258 mothers were multigravida. The mean heart rate at 18-40 weeks of gestation was  $142 \pm 6$  beats per minute. The median heart rate at 18-40 weeks of gestation was 124 beats per minute. The lowest heart rate was 124 beats per minute and the highest heart rate was 164 beats per minute. A linear increase of left atrial longitudinal and transverse diameter was seen throughout the gestational age [Table/Fig-6,7].

A linear increase of right atrial longitudinal and transverse diameter was seen throughout the gestational age [Table/Fig-8,9].

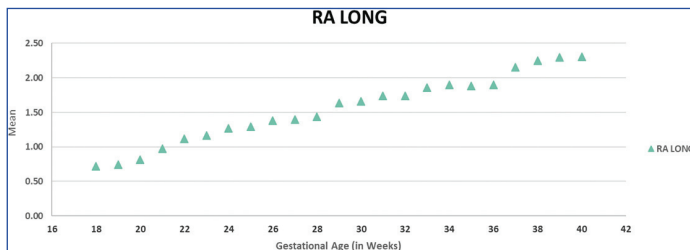
A linear increase of left ventricular longitudinal and transverse diameter was seen throughout the gestational age [Table/Fig-10,11].



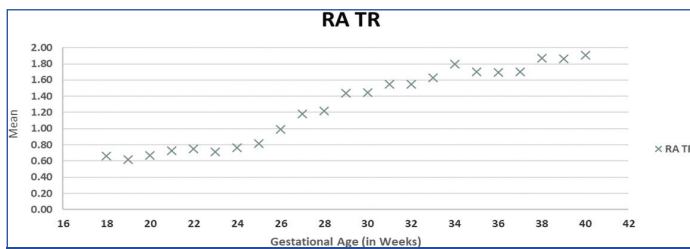
[Table/Fig-6]: Mean and standard deviation values of left atrial longitudinal diameter.



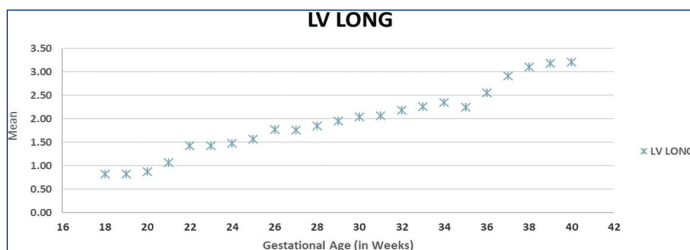
[Table/Fig-7]: Mean and standard deviation values of left atrial transverse diameter.



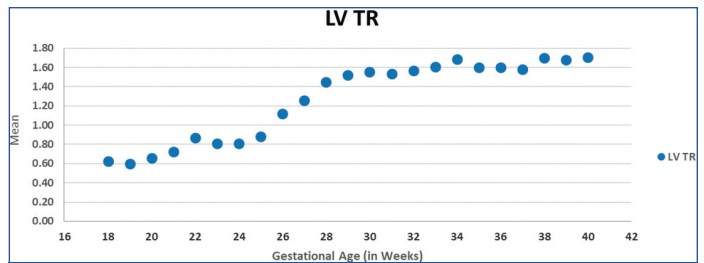
[Table/Fig-8]: Mean and standard deviation values of right atrial longitudinal diameter.



[Table/Fig-9]: Mean and standard deviation values of right atrial transverse diameter.



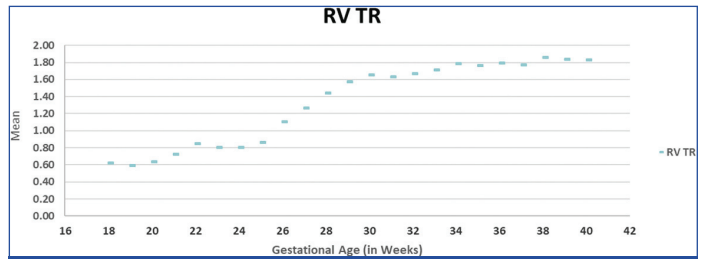
[Table/Fig-10]: Mean and standard deviation values of left ventricular longitudinal diameter.



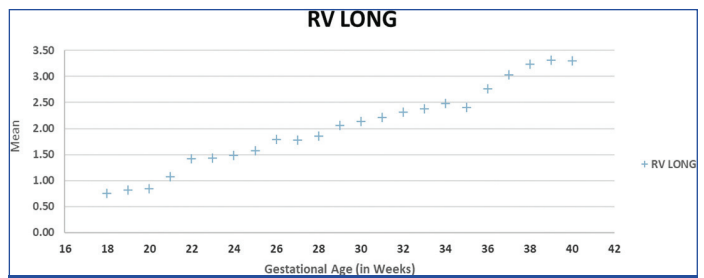
[Table/Fig-11]: Mean and standard deviation values of left ventricular transverse diameter.

A linear increase of right ventricular longitudinal and transverse diameter was seen throughout the gestational age [Table/Fig-12,13].

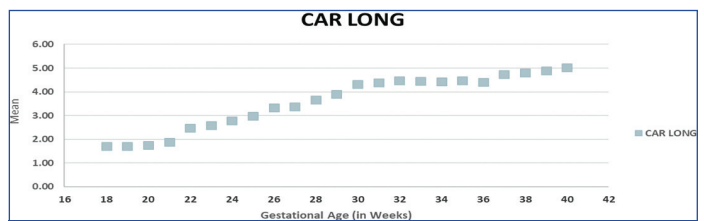
A linear increase of cardiac longitudinal and transverse diameter was seen throughout the gestational age [Table/Fig-14,15].



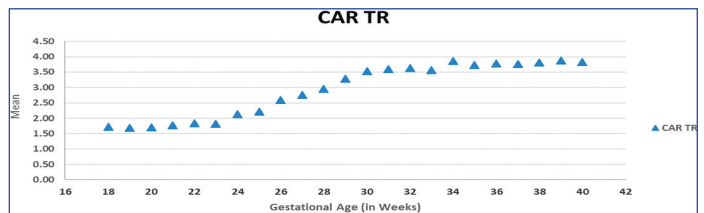
[Table/Fig-12]: Mean and standard deviation values of right ventricular transverse diameter.



[Table/Fig-13]: Mean and standard deviation values of right ventricular longitudinal diameter.



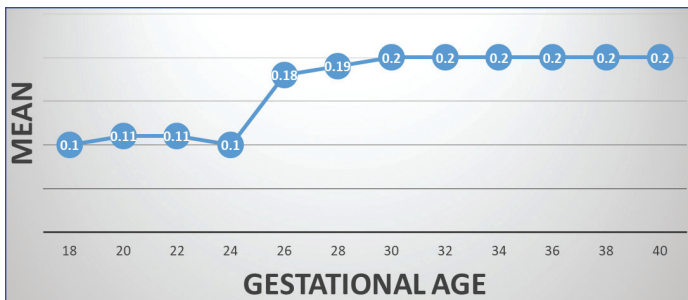
[Table/Fig-14]: The mean and standard deviation values of cardiac longitudinal diameter.



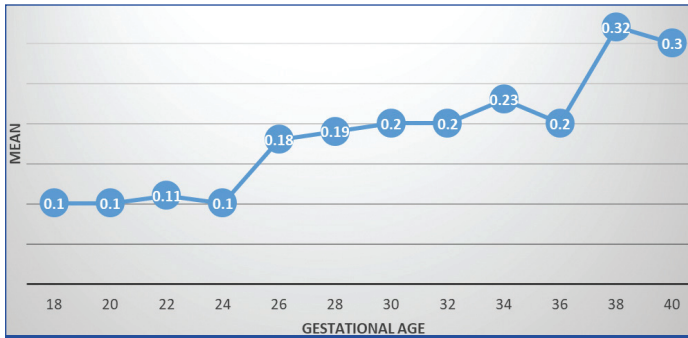
[Table/Fig-15]: The mean and standard deviation values of cardiac transverse diameter.

A linear increase of interatrial and interventricular septal thickness was seen throughout the gestational age [Table/Fig-16,17].

[Table/Fig-18,19] depicted the compiled values of all cardiac measurement for the gestational age of 18-40<sup>th</sup> weeks. All dimensions show progressive increase with gestational age. Regression coefficient is a statistical measure of the average functional relationship between two or more variables [Table/Fig-20]. Thus, it measures the degree of dependence of the dimensions on the gestational age. As the coefficient is high, there is high degree of relationship between dimensions and gestational age. Gestational age is the strong



**[Table/Fig-16]:** The mean and standard deviation values of interarterial septal thickness.



**[Table/Fig-17]:** The mean and standard deviation values of interventricular septal thickness.

predictor of increase in dimensions. As the p-value of all cardiac dimension measured in the present study is less than 0.05, there is significant relationship between the foetal cardiac dimensions and gestational age.

## DISCUSSION

Among the 345 pregnant women, 87 women were primigravida and 258 pregnant mother were multigravida. Maximum number of pregnant women were in 21-25 years of age group comprising 45% of the study population. Foetal cardiac measurement taken in the present study is seen compared with other studies like Garcia- Otero L et al., Luewan S et al., GU X et al., and Barreto EQ et al., [1,2,15,16].

Garcia-Otero L et al., a cohort study, in which foetal cardiac measurement were taken in 600 and two normal singleton pregnancies [1]. Normogram were then constructed for cardiac dimensions of the foetus including transverse, longitudinal atrial, ventricular parameters and whole heart's area, area of atria and ventricles. According to Garcia-Otero L et al., the mean values for left atrial longitudinal and transverse diameters, right atrial longitudinal, transverse diameters, left and right ventricle longitudinal, transverse diameter, at 18 weeks were 0.7, 0.6, 0.6, 0.7, 0.9, 0.6, 0.8, 0.6 cm, respectively [1]. The mean values for total cardiac longitudinal and transverse diameters at 18 weeks were 1.8 and 1.5 cm, respectively. According to Garcia-Otero L et al., the mean values for left atrial longitudinal and transverse diameters, right atrial longitudinal, transverse diameters, left and right ventricle longitudinal, transverse diameter, at 40 weeks are 2.1,1.8,2.2,1.8,3.1,1.8, 3.1,1.8 cm, respectively. The mean values for total cardiac longitudinal and transverse diameters at 40 weeks are 5 cm and 3.9 cm, respectively. Foetal cardiac measurement of the present study seen comparable to the reference value of all cardiac parameters in Garcia-Otero L et al., [Table/Fig-21,22] [1,2,15].

Variable	Mean±SD values (cm)	18	19	20	21	22	23	24	25	26	27	28	29	30
LA long		0.71±0.04	0.73±0.04	0.79±0.06	0.97±0.06	1.12±0.03	1.15±0.05	1.20±0.05	1.23±0.06	1.27±0.06	1.37±0.06	1.43±0.04	1.53±0.04	1.56±0.06
LA TR		0.63±0.06	0.64±0.03	0.65±0.06	0.69±0.07	0.71±0.05	0.72±0.07	0.77±0.05	0.82±0.04	0.96±0.05	1.17±0.07	1.22±0.04	1.31±0.05	1.35±0.05
RA long		0.72±0.02	0.74±0.05	0.81±0.05	0.97±0.06	1.12±0.04	1.16±0.05	1.27±0.05	1.29±0.06	1.38±0.05	1.39±0.05	1.43±0.04	1.63±0.04	1.66±0.05
RA TR		0.62±0.07	0.66±0.03	0.67±0.09	0.71±0.08	0.73±0.07	0.75±0.06	0.77±0.05	0.86±0.04	0.99±0.07	1.19±0.06	1.22±0.03	1.34±0.05	1.45±0.05
LV long		0.81±0.05	0.82±0.04	0.87±0.07	1.07±0.06	1.32±0.06	1.43±0.06	1.48±0.05	1.57±0.05	1.70±0.05	1.75±0.05	1.85±0.05	1.96±0.05	2.05±0.04
LV TR		0.60±0.06	0.62±0.01	0.66±0.07	0.72±0.04	0.81±0.05	0.84±0.03	0.87±0.07	0.88±0.04	1.12±0.05	1.26±0.05	1.45±0.05	1.52±0.04	1.55±0.05
RV long		0.75±0.06	0.82±0.03	0.84±0.09	1.07±0.06	1.22±0.06	1.34±0.06	1.48±0.05	1.57±0.05	1.75±0.04	1.78±0.05	1.85±0.05	2.05±0.06	2.14±0.05
RV TR		0.62±0.07	0.63±0.01	0.64±0.05	0.72±0.04	0.78±0.05	0.81±0.03	0.84±0.07	0.87±0.05	1.11±0.08	1.27±0.05	1.45±0.06	1.58±0.14	1.66±0.05
IA septum		0.10±0.01	0.10±0.00	0.11±0.02	0.10±0.00	0.11±0.02	0.10±0.00	0.10±0.00	0.17±0.05	0.18±0.00	0.18±0.00	0.19±0.00	0.19±0.03	0.20±0.00
IV septum		0.10±0.00	0.10±0.00	0.10±0.00	0.10±0.00	0.11±0.02	0.10±0.00	0.10±0.00	0.17±0.05	0.18±0.00	0.19±0.00	0.19±0.02	0.20±0.00	0.20±0.01
CAR long		1.71±0.04	1.70±0.01	1.74±0.04	1.89±0.06	2.48±0.09	2.59±0.07	2.78±0.09	2.98±0.06	3.34±0.08	3.38±0.15	3.65±0.15	3.91±0.13	4.33±0.10
CAR TR		1.69±0.03	1.70±0.03	1.71±0.03	1.77±0.07	1.84±0.05	1.92±0.06	2.13±0.07	2.22±0.07	2.59±0.28	2.75±0.08	2.95±0.11	3.29±0.08	3.54±0.07

**[Table/Fig-18]:** Foetal cardiac measurements as per gestational age from 18<sup>th</sup> to 30 weeks.

\*LONG: Longitudinal; TR: Transverse; RA: Right atrial; LV: Left ventricular; RV: Right ventricular; IA: Interatrial; CAR: Cardiac

Variable	Mean±SD values (cm)	31	32	33	34	35	36	37	38	39	40
LA long		1.69±0.05	1.64±0.05	1.70±0.05	1.74±0.10	1.78±0.05	1.90±0.01	2.06±0.13	2.12±0.10	2.18±0.07	2.22±0.03
LA TR		1.42±0.05	1.45±0.05	1.55±0.05	1.59±0.07	1.60±0.02	1.67±0.01	1.68±0.13	1.69±0.08	1.70±0.05	1.71±0.02
RA long		1.74±0.05	1.77±0.05	1.82±0.05	1.88±0.10	1.90±0.04	1.99±0.01	2.16±0.03	2.25±0.11	2.30±0.04	2.31±0.02
RA TR		1.51±0.05	1.55±0.05	1.63±0.05	1.70±0.18	1.73±0.01	1.75±0.03	1.78±0.04	1.82±0.06	1.86±0.05	1.90±0.01
LV long		2.07±0.07	2.19±0.06	2.26±0.05	2.35±0.12	2.44±0.05	2.55±0.14	2.91±0.08	3.11±0.09	3.18±0.05	3.21±0.04
LV TR		1.56±0.05	1.57±0.05	1.61±0.03	1.63±0.01	1.66±0.01	1.68±0.01	1.69±0.06	1.70±0.09	1.72±0.05	1.73±0.01
RV long		2.22±0.07	2.31±0.08	2.38±0.04	2.48±0.11	2.60±0.03	2.76±0.11	3.03±0.05	3.23±0.07	3.31±0.05	3.33±0.02
RV TR		1.67±0.05	1.69±0.05	1.71±0.03	1.75±0.1	1.77±0.05	1.80±0.01	1.84±0.08	1.85±0.08	1.86±0.05	1.87±0.05
IA septum		0.20±0.00	0.20±0.00	0.20±0.00	0.20±0.00	0.20±0.00	0.20±0.00	0.20±0.00	0.20±0.00	0.20±0.00	0.20±0.00
IV septum		0.20±0.00	0.20±0.00	0.20±0.00	0.23±0.05	0.20±0.00	0.20±0.00	0.30±0.01	0.32±0.06	0.31±0.03	0.30±0.00
CAR long		4.38 ±0.09	4.46±0.09	4.46±0.09	4.47±0.21	4.47±0.05	4.48±0.15	4.75±0.08	4.81±0.13	4.89±0.08	5.02±0.04
CAR TR		3.60±0.09	3.63 ±0.06	3.70±0.07	3.72±0.17	3.73±0.07	3.78±0.04	3.79±0.08	3.81 ±0.11	3.82±0.06	3.84±0.04

**[Table/Fig-19]:** Foetal cardiac measurements as per gestational age from 31<sup>th</sup> to 40 weeks.

Dependent variables	Unstandardised coefficient		Standardised coefficient beta	p-value
	B	Std. Error		
LA long	0.063	0.001	0.952	0.001
LA TR	0.056	0.001	0.931	0.001
RA long	0.068	0.001	0.959	0.001
RA TR	0.063	0.001	0.934	0.001
LV long	0.100	0.002	0.953	0.001
LV TR	0.054	0.001	0.903	0.001
RV long	0.109	0.002	0.959	0.001
RV TR	0.064	0.001	0.918	0.001
IA septum	0.063	0.001	0.933	0.001
IV septum	0.010	0.000	0.842	0.001
CAR long	0.153	0.003	0.934	0.001
CAR TR	0.116	0.003	0.917	0.001

**[Table/Fig-20]:** Non standardised coefficient, standardised coefficient, p-value of all cardiac dimension.

Article	18 <sup>th</sup> weeks of gestation									CAR TR (cm)
	LA long (cm)	LA TR (cm)	RA long (cm)	RA TR (cm)	LV long (cm)	LV TR (cm)	RV long (cm)	RV TR (cm)	CAR long (cm)	
Garcia-Otero L et al., [1]	0.7	0.6	0.6	0.7	0.9	0.6	0.8	0.6	1.8	1.5
Luewan S et al., [2]						0.7		0.6		
GU X et al., [15]		0.7		0.7		0.66		0.69		
Present study	0.73	0.65	0.72	0.66	0.83	0.62	0.75	0.62	1.71	1.72

**[Table/Fig-21]:** Comparison of reference value of foetal heart at 18 weeks of gestation of the present study with other studies [1,2,15].

Article	40 <sup>th</sup> weeks of gestation									CAR TR (cm)
	LA long (cm)	LA TR (cm)	RA long (cm)	RA TR (cm)	LV long (cm)	LV TR (cm)	RV long (cm)	RV TR (cm)	CAR long (cm)	
Garcia-Otero L et al., [1]	2.1	1.8	2.2	1.8	3.1	1.7	3.1	1.8	5.0	3.9
Luewan S et al., [2]						1.6		1.7		
Present study	2.2	1.7	2.3	1.9	3.2	1.7	3.3	1.8	5.02	3.84

**[Table/Fig-22]:** Comparison of reference value of foetal heart at 40 weeks of gestation of the present study with other studies [1,2].

Barreto EQ et al., a cross-sectional study were conducted on 303 normal singleton pregnancies between their 20<sup>th</sup> and 34<sup>th</sup> weeks of gestation [16]. The mean distance between the apex and base of the foetal heart was measured. The mean distance between the apex and base of the foetal heart at 20 weeks of gestation ranges from 12.1 mm to 17.1 mm. These reference values were seen comparable with the mean value of cardiac longitudinal, transverse dimensions in the present study.

GU X et al., conducted a study on a total of 4396 normal foetuses from 20-34 weeks of gestation [15]. Measurements including the interior diameters of the cardiac chambers of the foetus and its arteries, the isthmus of the aortic arch, the descending aorta, the ductus-arteriosus and the diameter of foramen ovale were calculated. The normal reference value for left and right atrial diameter, left ventricle diameter, and right ventricular diameter at 20 weeks is 0.7, 0.7, 0.66 and 0.69 cm, respectively. These right and left atrial, right and left ventricular longitudinal and transverse diameters were comparable to the reference value of the present study.

The present study provides normal referral diameter for all cardiac variables, as mentioned above and can be used for the Indian population. It also helps in the early identification of foetal cardiac defects and early intervention and management of the patient.

### Limitation(s)

Limitation of the present study is less number of sample size. Electrocardiography (ECG) gating is not used while measuring

the cardiac dimensions. The area of cardiac chambers was not measured in the present study.

### CONCLUSION(S)

The present study gives reference ranges for cardiac dimensions of the foetus from 18-40 weeks of gestational age and provides the normal reference ranges for foetal cardiac dimensions in the Indian population. These measurements can be a helpful tool in the early identification of congenital cardiac defects. These, in turn, can be used to enable early intervention and long-term consequences of the cardiovascular system can be minimised.

### REFERENCES

- [1] García-Otero L, Gómez O, Rodríguez-López M, Torres X, Soveral I, Sepúlveda-Martínez Á, et al. Nomograms of foetal cardiac dimensions at 18-41 weeks of gestation. *Foetal Diagn Ther.* 2020;47(5):387-98. Doi: 10.1159/000494838. Epub 2019 Jan 4. PMID: 30612128.
- [2] Luewan S, Yanase Y, Tongprasert F. Foetal cardiac dimensions at 14-40 weeks' gestation obtained using cardio-STIC-M. *Ultrasound Obstet Gynecol.* 2011;37(4):416-22. Doi: 10.1002/uog.8961. PMID: 21305637.
- [3] Schneider C, McCrindle BW, Carvalho JS, Hornberger LK, McCarthy KP, Daubeney PE, et al. Development of Z-scores for foetal cardiac dimensions from echocardiography. *Ultrasound Obstet Gynecol.* 2005;26(6):599-605. Doi: 10.1002/uog.2597. PMID: 16254878.
- [4] Rommel C, Hein L. Four Dimensions of the cardiac Myocyte Epigenome: From foetal to adult heart. *Curr Cardiol Rep.* 2020;22(5):26. Doi: 10.1007/s11886-020-01280-7. PMID: 32193645; PMCID: PMC7082379.
- [5] Patel N, Narasimhan E, Kennedy A. Foetal Cardiac US: Techniques and normal anatomy correlated with adult CT and MR imaging. *Radiographics.* 2017;37(4):1290-303. Doi: 10.1148/rg.2017160126. Epub 2017 Jun 2. PMID: 28574808.
- [6] Rajiah P, Mak C, Dubinsky TJ, Dighe M. Ultrasound of foetal cardiac anomalies. *AJR Am J Roentgenol.* 2011;197(4):W747-60. Doi: 10.2214/AJR.10.7287. PMID: 21940548.

- [7] Mohammed NB, Chinnaiya A. Evolution of foetal echocardiography as a screening tool for prenatal diagnosis of congenital heart disease. *J Pak Med Assoc.* 2011;61(9):904-09. PMID: 22360034.
- [8] Zhang Y, Cai AL, Ren WD, Guo YJ, Zhang DY, Sun W, et al. Identification of foetal cardiac anatomy and hemodynamics: A novel enhanced screening protocol. *BMC Pregnancy Childbirth.* 2016;16:145. Doi: 10.1186/s12884-016-0933-9. PMID: 27363399; PMCID: PMC4928259.
- [9] Tirosh-Finkel L, Elhanany H, Rinon A. Mesoderm progenitor cells of common origin contribute to the head musculature and the cardiac outflow tract. *Development.* 2006;133(10):1943-53. Doi: 10.1242/dev.02365.
- [10] Lickert H, Kutsch S, Kanzler B, Tamai Y, Taketo MM, Kemler R. Formation of multiple hearts in mice following deletion of beta-catenin in the embryonic endoderm. *Developmental Cell.* 2002;3(2):171-81. Doi: 10.1016/s1534-5807(02)00206-x.
- [11] Khalil A, Nicolaides KH. Foetal heart defects: Potential and pitfalls of first-trimester detection. *Semin Foetal Neonatal Med.* 2013;18(5):251-60. Doi: 10.1016/j.siny.2013.05.004. Epub 2013 Jun 7. PMID: 23751926.
- [12] Crispi F, Sepúlveda-Martínez Á, Crovetto F, Gómez O, Bijmens B, Gratacós E, et al. Main patterns of foetal cardiac remodeling. *Foetal Diagn Ther.* 2020;47(5):337-344. Doi: 10.1159/000506047. Epub 2020 Mar 26. PMID: 32213773.
- [13] Patey O, Carvalho JS, Thilaganathan B. Leftventricular torsional mechanics intermfoetuses and neonates. *Ultrasound Obstet Gynecol.* 2020;55(2):233-41.
- [14] Hata T, Dai SY, Inubashiri E, Kanenishi K, Tanaka H, Yanagihara T, et al. Four-dimensional sonography with B-flow imaging and spatiotemporal image correlation for visualization of the foetal heart. *J Clin Ultrasound.* 2008;36(4):204-07. Doi: 10.1002/jcu.20478. PMID: 18335509.
- [15] Gu X, He Y, Zhang Y, Sun L, Zhao Y, Han J, et al. Foetal echocardiography: Reference values for the Chinese population. *J Perinat Med.* 2017;45(2):171-79. Doi: 10.1515/jpm-2015-0385. PMID: 27665417.
- [16] Barreto EQ, Araujo Júnior E, Martins WP, Rolo LC, Milani HJ, Nardoza LM, et al. New technique for assessing foetal heart growth using three-dimensional ultrasonography: Description of the technique and reference curves. *J Matern Foetal Neonatal Med.* 2015;28(9):1087-93. Doi: 10.3109/14767058.2014.943176. Epub 2014 Jul 28. PMID: 25005859.

**PARTICULARS OF CONTRIBUTORS:**

1. Professor, Department of Radiology, SRM Medical College and Research Centre, Chennai, Tamil Nadu, India.
2. Student, Department of Radiology, SRM Medical College and Research Centre, Chennai, Tamil Nadu, India.
3. Professor and Head, Department of Radiology, SRM Medical College and Research Centre, Chennai, Tamil Nadu, India.

**NAME, ADDRESS, E-MAIL ID OF THE CORRESPONDING AUTHOR:**

Dr. Sundara Raja Perumal,  
B43, TVS Green Acre, Phase IV, Kolappakkam, New Perungulathur,  
Chennai, Tamil Nadu, India.  
E-mail: majsundp@srmist.edu.in

**PLAGIARISM CHECKING METHODS:** [Jain H et al.]

- Plagiarism X-checker: Aug 18, 2022
- Manual Googling: Oct 16, 2022
- iThenticate Software: Dec 15, 2022 (10%)

**ETYMOLOGY:** Author Origin**AUTHOR DECLARATION:**

- Financial or Other Competing Interests: None
- Was Ethics Committee Approval obtained for this study? Yes
- Was informed consent obtained from the subjects involved in the study? Yes
- For any images presented appropriate consent has been obtained from the subjects. Yes

Date of Submission: **Aug 12, 2022**Date of Peer Review: **Nov 11, 2022**Date of Acceptance: **Dec 27, 2022**Date of Publishing: **Apr 01, 2023**