

Optic Nerve Head Melanocytoma Co-existing in a Case of Thyroid Eye Disease: Co-incidence or Cause?

JANANI RAJAGOPAL¹, GOPAL K DAS²

(CC) BY-NC-ND

ABSTRACT

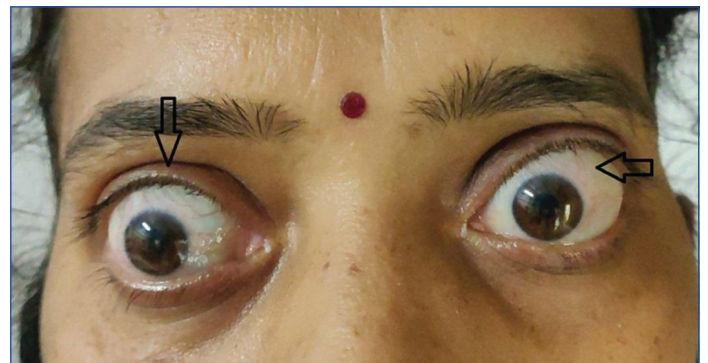Optic Nerve Head Melanocytoma (ONHM) is a rare benign pigmented tumour of the uveal tract, seen commonly at the optic nerve head. The tumour is associated with a few ocular and systemic conditions. It usually remains stationary and rarely (1-2%) undergoes a malignant transformation. With the progressive understanding of its benign nature with advancing imaging modalities, observation with regular follow-up is the mainstay of treatment. A 35-year-old female, presented with complaints of foreign body sensation in both eyes. She was a known case of graves' disease under treatment with anti-thyroid drugs and beta blockers. Ocular examination revealed classic signs of thyroid eye disease. The left eye fundus revealed a large, black, globular tumour in the optic nerve head obscuring the entire disc and Ultrasound B scan revealed a tumour at the optic nerve head with high echogenicity. Optical Coherence Tomography (OCT) through the mass revealed a dome-shaped elevation with obscuration of underlying details due to heavy pigmentation, with no signs of subretinal exudation or edema. Thyroid profile was within normal limits. A diagnosis of left eye ONHM was made. The patient was started on tapering doses of systemic steroids and was regularly followed-up to monitor the tumour growth for 18 months. This is the first reported case of ONHM co-existing with thyroid eye disease and this association could be coincidental or embryological. This case highlights the need for ophthalmologists to be familiar with this benign condition and for regular careful follow-up of such patients.

Keywords: Graves' disease, Magnocellular nevus, Pigmented ocular tumours, Uveal tumours

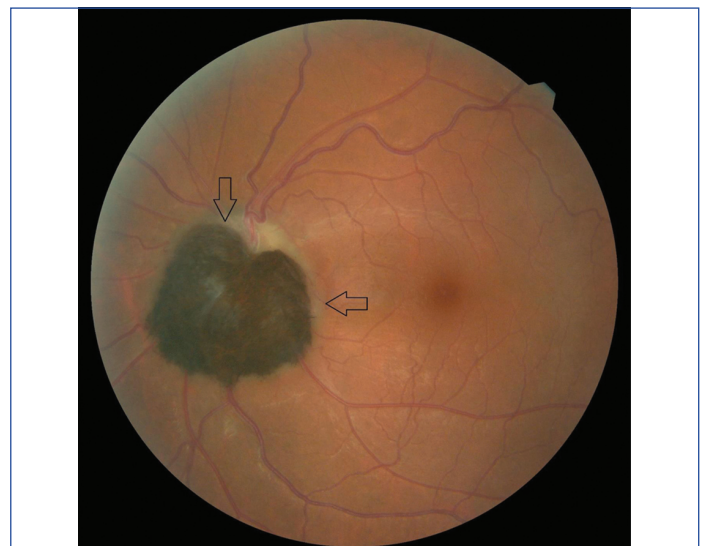
CASE REPORT

A 35-year-old female patient came to the ophthalmology clinic with the chief complaints of foreign body sensation and inability to close her eyes during sleep for the past one year. She was a known case of Graves' disease, on treatment for the past 12 years with antithyroid drugs like Carbimazole 10 mg and Propranolol 20 mg. She had a good appetite with excessive sweating, weakness, fatigue, tremors, and palpitations. She had no other chronic illnesses like diabetes, hypertension, or coronary artery disease. Though, she had a history of oligomenorrhoea. She was a non smoker and non alcoholic with normal bowel and bladder habits. Her family history was not significant.

The physical examination showed her body weight to be 65 kg. Her blood pressure was 120/80 mmHg and her pulse rate was 82 beats per minute. No evidence of thymomegaly was seen. Ocular examination revealed bilateral exophthalmos with classical thyroid eyes signs like lid retraction, lid lag, lid fullness, and lateral lid flare [Table/Fig-1]. Hyperaemia and congested conjunctival vessels were noted at the area of extraocular muscle insertion. The cornea was normal with no signs of exposure keratitis. Pupils were equal in size and reacted equally to light. Her best corrected visual acuity was Snellen 6/9 in the right eye and 6/18 in the left eye. Intraocular pressure, gonioscopy, and rest of the anterior segment findings were within normal limits. The right eye fundus was unremarkable. The left eye fundus revealed a round, black, raised pigmented tumour with a feathery margin (approximately, 2 Disc Diameter in size) extending beyond the disc margin, into the surrounding Retinal Nerve Fiber Layer (RNFL), obscuring the optic nerve head, pointing to a diagnosis of "ONHM" [Table/Fig-2]. The adjacent retina and choroid were uninvolved. Only the superior neuroretinal rim was visible which was pale and ill-defined. Dilated retinal veins were seen. Macula was normal. OCT optic nerve head revealed a dome-shaped elevation corresponding to the tumour at the optic nerve head area with a thin hyper-reflective line defining the anterior outline of the tumour, with an underlying back-shadowing due to heavy

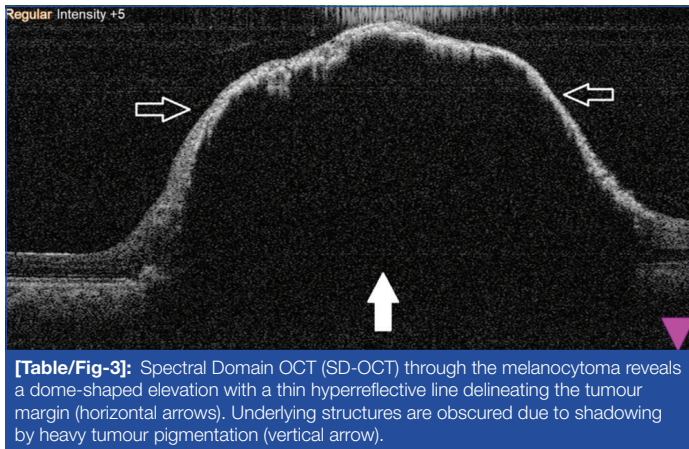


[Table/Fig-1]: Photograph of the patient with thyroid eye signs in both eyes- Exophthalmos, Lid retraction (vertical arrow), and Lateral lid flare (horizontal arrow).



[Table/Fig-2]: Fundus photograph showing a large, pigmented melanocytoma (arrows), obscuring the optic disc with feathery margins. The surrounding retina and choroid appear normal.

pigmentation [Table/Fig-3]. There was no surrounding exudation or edema. Humphrey's visual field analysis of the left eye revealed an enlarged blind spot with a biarcuate scotoma in the left eye. B-scan ultrasonography revealed a dome-shaped mass lesion over the optic disc region of the left eye with high echogenicity. Proptosis measurement using Hertel's exophthalmometry and dry eye work-up (Schirmer's test and Tear film break-up time) were recorded. Clinical Activity Scoring (CAS) was done.



[Table/Fig-3]: Spectral Domain OCT (SD-OCT) through the melanocytoma reveals a dome-shaped elevation with a thin hyperreflective line delineating the tumour margin (horizontal arrows). Underlying structures are obscured due to shadowing by heavy tumour pigmentation (vertical arrow).

Medical records available with the patient dated before starting antithyroid drugs revealed that the patient was biochemically hyperthyroid initially with a reduced Thyroid Stimulating Hormone (TSH-0.21 μ IU/mL; normal range: 0.340-4.220) and elevated T3 and T4 hormones (T3-4.29 pg/mL; normal range: 2.24-3.94 pg/mL and T4-3.56 ng/dL; normal range: 0.77-1.59 ng/dL) with a positive Thyrotropin-Receptor Antibody test (TRAb- 2.7 IU/L; Normal values: ≤ 2 IU/L). A repeat thyroid profile was done on presentation and it revealed a euthyroid state (TSH-2.08 μ IU/mL, T3-3.51 pg/mL, and T4-1.19 ng/dL) probably due to the treatment with antithyroid drugs. The complete blood count, serum calcium, urea, creatinine, liver function tests, and Electrocardiograph (ECG) were within normal limits. Ultrasound of the thyroid gland revealed a normal-sized gland.

A clinical diagnosis of euthyroid Graves' disease with thyroid eye disease with left eye ONHM was made. An endocrinology referral was done for evaluation and treatment. The patient was started on a tapering regime of prednisolone 40 mg per day daily for two weeks, then 20 mg daily for two weeks, then 10 mg daily for one week, and finally 5 mg daily for one week, along with Omeprazole 40 mg per day daily. Conservative management was done for eye symptoms. Head end elevation and cool compresses were advised. Topical lubricants (1% Carboxy methyl cellulose) were prescribed and refractory error correction was done. The patient was regularly followed-up for 18 months to monitor the tumour growth and activity of the thyroid eye disease and the tumour. The patient remained euthyroid and asymptomatic under medications, with no visual deterioration or tumour progression.

DISCUSSION

The ONHM has been historically considered a part of primary malignant melanoma of the optic nerve. It is evident from the past literature that the majority of these cases underwent enucleation, erroneously believing this to be a malignant tumour with lethal potential but the histopathology of these enucleated eyes had revealed benign features. Hence, a separate entity of closely similar pigmented benign tumour had been described by Zimmerman LE, as "Melanocytoma of the optic nerve" [1]. Melanocytoma has been believed to be originating from the pigmentation of uveal melanocytes of lamina cribrosa [2,3]. Most of the cases are diagnosed incidentally on routine ophthalmic examination at a mean age of 50 years [4]. Women are more commonly affected than men [5]. Visual loss is rare and can be caused by exudative detachment of the fovea, central

retinal vein occlusion, and neuroretinitis due to tumour necrosis or malignant transformation (1-2%) [6]. The diagnosis is usually clinical with the classical features of a dark brown to a black lesion that is located centrally obscuring part or the entire optic disc. The tumour has a feathery margin that can extend to the adjacent RNFL with or without the surrounding retinal and choroidal involvement [7]. The visual field can reveal an enlarged blind spot. The present case had an enlarged blind spot with a biarcuate scotoma probably due to mechanical compression of the nerve fiber bundles and its microcirculation. The differential diagnosis includes juxta-papillary choroidal melanoma, choroidal nevus, Congenital Hypertrophy of Retinal Pigment Epithelium (CHRPE), combined hamartoma of the retina and Retinal Pigment Epithelium (RPE), adenoma of RPE and metastatic melanoma of the optic disc [8]. Imaging modalities like Fundus Fluorescein Angiography (FFA), OCT, OCT Angiography, and Ultrasound B scan can help in differentiating these lesions from ONHM.

Spectral Domain OCT (SD-OCT) is very useful in differentiating melanocytoma from uveal melanoma. OCT of the present case revealed a dome-shaped elevation arising from the optic disc corresponding to the tumour with increased reflectivity at its anterior margin. A dense optically empty space can be observed underneath due to the shadowing of the underlying retina as a result of the heavy pigmentation. Raval V et al., and Zhang P et al., reported similar OCT features of ONHM in their case studies [9,10]. FFA reveals hypo-fluorescence throughout the angiogram and can aid in differentiating this condition from uveal melanoma. Computed Tomography (CT) and Magnetic Resonance Imaging (MRI) can detect the retrolaminar extension of the tumour into the optic nerve. Ultrasound B scan can reveal an acoustic solidity with high internal reflectivity. Reassurance, symptomatic therapy, and careful follow-up for signs of malignancy are the mainstay of treatment.

The present case had been followed-up for a period of 18 months. The patient had no visual disturbance or vision loss during the course of the follow-up. The tumour size remained stationary indicating the absence of progression of the tumour. This was confirmed by serial fundus examinations, ultrasound B scan, and OCT. Transient ischemic necrosis [11] and subsequent visual disturbance are possible in this benign tumour but rapid progressive growth with profound vision loss indicates malignant change and such eyes have to be enucleated [12]. The present case was a patient with Grave's eye disease with co-existing melanocytoma which was incidentally detected during a routine ophthalmic examination. Benign melanotic tumours of the optic nerve head arise from leptomeninges. Melanocytoma has been reported along with a few ocular conditions like ocular melanocytosis, retinitis pigmentosa, retinal vascular occlusion [13], congenital ptosis, and systemic conditions like vitiligo [14], meningioma, and neurofibromatosis in the past literature. Although these conditions have occurred co-incidentally with melanocytoma, a possible embryological link has also been postulated. Shinoda K et al., reported a case of co-existing melanocytoma and tuberculum sellae meningioma and linked this association as embryological, as both these structures are originating from the neural crest cells [15]. Attiku Y et al., reported a similar case of association between melanocytoma and pituitary adenoma and suggested to suspect pituitary pathologies in the cases of melanocytoma with unexplained visual field changes. There was no published literature linking melanocytoma to Grave's disease [16]. Ellerhorst JA et al., in their study reported that functional TSH receptors have been expressed by all melanocytic lesions like benign nevi, dysplastic nevi, and melanomas [17]. He postulated that the TSH hormone is a growth factor for melanoma, but not for melanocytes. At a relevant concentration, the expression of TSH influences the transformation of melanocytes into melanoma cells, indicating the role of TSH in melanoma progression. Contrastingly,

a possible protective role of graves' disease on melanoma risk and progression has been postulated by Chen S et al., [18]. He provided a possible explanation that the excessive thyroid hormones and the TSH receptor antibodies in Graves' disease fail to activate the TSH receptors expressed in melanocytes. Kim CY et al., emphasised in their study that melanoma induces thyroid dysfunction [19]. Both melanocyte-stimulating hormone and thyroid-stimulating hormone act upon the melanocytes and thyroid cells. The present case is a known case of Grave's disease, with higher circulating thyroid hormones and thyrotropin receptor antibodies and with a low circulating TSH, and fluctuation of these hormones (due to antithyroid drugs treatment), this could have had a cause or effect relationship with the growth of melanocytoma, due to the expression of TSH receptors and the sensitivity of these receptors in the tumour to TSH. With the possibility that the patients of grave's disease have random periods of hyperthyroid, euthyroid, and hypothyroid state (the patient was euthyroid on presentation under treatment), it was suspected that the fluctuating TSH levels could have had a role in the occurrence or growth of melanocytoma, owing to its expression of functional TSH receptors.

While discussing the possible aetiology of this condition, it will be relevant to discuss another case of small superior ONHM in a young patient who got diagnosed incidentally in the ophthalmology clinic. This patient was a known case of Type 1 diabetes who came for a routine dilated fundus examination to screen for diabetic retinopathy. With the fact that Type 1 diabetes (as observed in the above-mentioned case) is an autoimmune condition and ONHM has been previously reported along with vitiligo [14], and in the present case with Graves' disease, an autoimmune association could not be completely ruled out. Whether this is a chance association or a contributory autoimmune aetiological relationship exists between melanocytoma and endocrine disorders could only be established with further research in more similar cases. With the developing knowledge of this condition, this benign tumour has to be observed for progression and if rapidly progresses to cause severe visual deterioration, malignant transformation has to be suspected and aggressive management like enucleation can be planned.

This was the first reported case of ONHM observed in a patient with thyroid eye disease. Ophthalmologists should be aware of this benign lesion and its association with systemic and ocular conditions, to avoid extensive diagnostic and therapeutic procedures. Serial fundus photographs with ultrasound measurement of tumour size are recommended and if any significant change in size is detected, OCT and FFA imaging for ruling out malignant transformation can be done. Patients should be educated about the benign nature of this tumour and its rare chances of malignant transformation, thereby emphasising the need to visit for regular follow-up.

CONCLUSION(S)

The present case depicts the rare and unique association between ONHM and thyroid eye disease. This case highlights the importance of promptly diagnosing this benign condition and providing a careful long-term follow-up to exclude malignant transformations so that aggressive management like enucleation can be avoided at the benign stage. Any ocular and systemic association should be looked for to establish a causative (embryological- neural crest cell origin/hormonal/autoimmune or other) or co-incident relationship with melanocytoma for further understanding of this rare condition.

REFERENCES

- [1] Zimmerman LE. Pigmented tumours of the optic nerve head. The 22nd Annual de Schweinitz Lecture. *Am J Ophthalmol.* 1960;50:338.
- [2] Antcliff RJ, Fytche TJ, Shilling JS, Marshall J. Optical coherence tomography of melanocytoma. *Am J Ophthalmol.* 2000;130:845-47.
- [3] Eldaly H, Eldaly Z. Melanocytoma of the optic nerve head, thirty-month follow-up. *Semin Ophthalmol.* 2015;30(5-6):464-69.
- [4] Lee E, Sanjay S. Optic disc melanocytoma report of 5 patients from Singapore with a review of the literature. *Asia Pac J Ophthalmol (Phila).* 2015;4(5):273-78.
- [5] Lisker-Cervantes A, Ancona-Lezama DA, Arroyo-Garza LJ, Martinez JD, Barreiro RGD, Valdepeña-López-Velarde VD, et al. Ocular ultrasound findings in optic disk melanocytoma. *Revista Mexicana de Oftalmología.* 2017;91(6):316-20.
- [6] Shields JA, Demirci H, Mashayekhi A, Shields CL. Melanocytoma of optic disc in 115 cases: The 2004 Samuel Johnson Memorial Lecture, part 1. *Ophthalmology.* 2004;111(9):1739-46.
- [7] Mohmad Z, Kah TA, Yong KC, Abdul Halim WH, Kong Yong T. Melanocytoma of the optic nerve head-A diagnostic dilemma. *Clin Pract.* 2011;1(3):e60.
- [8] Mannat G, Meenakshi S, Navya NK, Subina N. Optic disc melanocytoma: A case report. *Rom J Ophthalmol.* 2021;65(1):89-92.
- [9] Raval V, Reddy R, Kaliki S, Das T, Singh AD. Optic nerve head melanocytoma: Optical coherence tomography/angiography features. *Indian J Ophthalmol.* 2021;69(2):332-36.
- [10] Zhang P, Hui YN, Xu WQ, Zhang ZF, Wang HY, Sun DJ, et al. Infrared autofluorescence, short-wave autofluorescence and spectral-domain optical coherence tomography of optic disk melanocytomas. *Int J Ophthalmol.* 2016;9:713-16.
- [11] Kim DS, Park HM, Lim HW, Lee WJ. Optic disc melanocytoma with normal tension glaucoma and angle closure glaucoma: Two case reports. *Medicine (Baltimore).* 2020;99(30):e21350.
- [12] Shields JA, Demirci H, Mashayekhi A, Eagle RC Jr, Shields CL. Melanocytoma of the optic disk: A review. *Surv Ophthalmol.* 2006;51(2):93-104.
- [13] Khadka S, Byanju R, Pradhan S. Central retinal artery occlusion in optic disk melanocytoma. *Clin Case Rep.* 2021;9(10):e04927.
- [14] Shields JA, Shields CL. Melanocytoma, in Shields JA, Shields CL (eds): *Atlas of Intraocular Tumours.* Philadelphia, Lippincott Williams and Williams, 1999, Pp. 324-25.
- [15] Shinoda K, Hayasaka S, Nagaki Y, Kadoi C, Kurimoto M, Okada E. Melanocytoma of the left optic nerve head and right retrobulbar optic neuropathy compressed by a tuberculum sellae meningioma. *Ophthalmologica.* 2000;214(2):161-63.
- [16] Attiku Y, Rishi P, Bassi S. Co-existing optic disc melanocytoma and pituitary adenoma. *Ocul Oncol Pathol.* 2019;5(5):319-22.
- [17] Ellerhorst JA, Sendi-Naderi A, Johnson MK, Cooke CP, Dang SM, Diwan AH. Human melanoma cells express functional receptors for thyroid-stimulating hormone. *Endocr Relat Cancer.* 2006;13(4):1269-77.
- [18] Chen S, Wu F, Hai R, You Q, Xie L, Shu L, et al. Thyroid disease is associated with an increased risk of breast cancer: A systematic review and meta-analysis. *Gland Surg.* 2021;10(1):336-46.
- [19] Kim CY, Lee SH, Oh CW. Cutaneous malignant melanoma associated with papillary thyroid cancer. *Ann Dermatol.* 2010;22(3):370-72.

PARTICULARS OF CONTRIBUTORS:

1. Senior Resident, Department of Ophthalmology, JIPMER, Karaikal, Puducherry, India.
2. Director Professor, Department of Ophthalmology, UCMS and GTBH, Delhi, India.

NAME, ADDRESS, E-MAIL ID OF THE CORRESPONDING AUTHOR:

Dr. Janani Rajagopal,
Number 31, Thomas Arul Street, Karaikal-609602, Puducherry, India.
E-mail: rjananiraj@gmail.com

AUTHOR DECLARATION:

- Financial or Other Competing Interests: None
- Was informed consent obtained from the subjects involved in the study? Yes
- For any images presented appropriate consent has been obtained from the subjects. Yes (Patient gave written informed consent for her images and other clinical information to be reported in the journal)

PLAGIARISM CHECKING METHODS: [Jain H et al.]

- Plagiarism X-checker: Nov 15, 2022
- Manual Googling: Jan 12, 2023
- iThenticate Software: Jan 28, 2023 (7%)

ETYMOLOGY: Author Origin

Date of Submission: **Oct 30, 2022**
Date of Peer Review: **Dec 31, 2022**
Date of Acceptance: **Feb 11, 2023**
Date of Publishing: **May 01, 2023**