

# Type I Segmental Darier's Disease: Successful Treatment with Oral Acitretin- A Case Report

SHANMUGAM REDDY PRAVEEN KUMAR<sup>1</sup>, MY SUPARNA<sup>2</sup>, VARSHA RAMANI<sup>3</sup>, THARAYIL KUNNETH SUMATHY<sup>4</sup>

## ABSTRACT

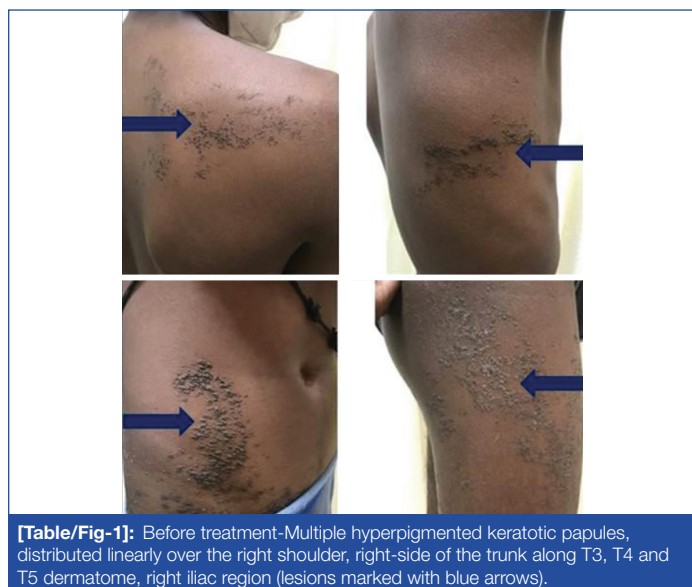Unilateral type I segmental Darier's Disease (DD) is a rare variant of DD. It is characterised by eruptions which are erythematous and keratotic papules. The authors hereby report a case of an 18-year-old male patient who presented with waxy hyperpigmented keratotic papules on the right side of the trunk and lower limb and was confirmed by histopathology. He was treated with oral acitretin, 25 mg once a day, which showed a marked clinical improvement within four months.

**Keywords:** Genodermatosis, Histopathology, Hyperpigmentation, Oral retinoids, Papules

## CASE REPORT

An 18-year-old male patient presented to the dermatology Outpatient Department (OPD) with complaints of asymptomatic lesions on the right side of his body for the past three years. The number of lesions had increased over time, presenting initially over the right leg extending upwards to involve the right side of his trunk. There were no similar complaints in family members.

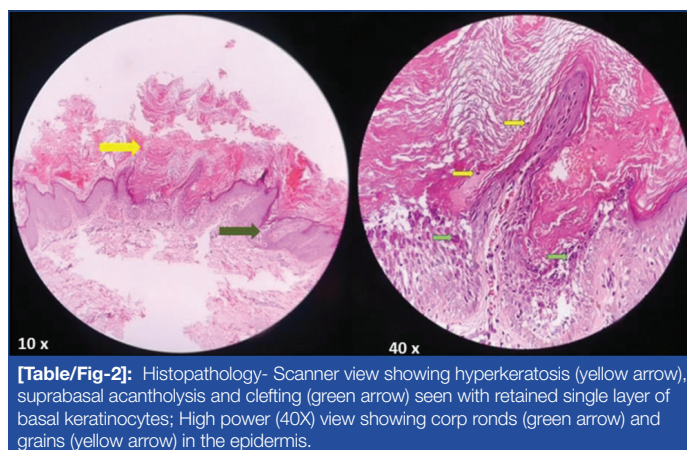
On cutaneous examination, multiple hyperpigmented keratotic papules were distributed linearly over the right thigh, abdomen, chest, upper back, and right shoulder [Table/Fig-1]. The scalp, nails, and mucous membranes were normal.



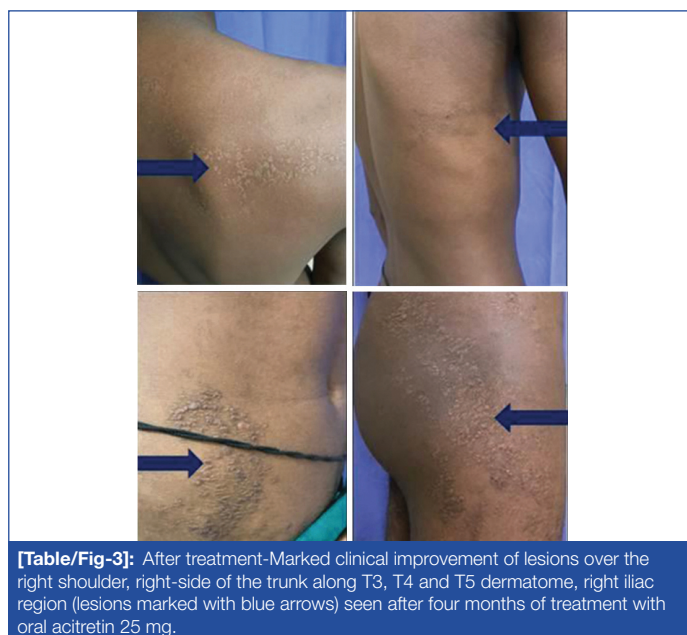**[Table/Fig-1]:** Before treatment—Multiple hyperpigmented keratotic papules, distributed linearly over the right shoulder, right-side of the trunk along T3, T4 and T5 dermatome, right iliac region (lesions marked with blue arrows).

A punch biopsy was performed on the lesion on the right thigh, and histopathological examination revealed hyperkeratosis, suprabasal acantholysis and clefting seen with a retained single layer of basal keratinocytes. Corp ronds and grains were seen in the epidermis [Table/Fig-2]. The underlying dermis showed perivascular chronic inflammatory cell infiltrates.

The patient was diagnosed with type 1 segmental DD based on the clinical presentation and histopathological examination results. The patient was treated, after relevant laboratory investigations, with oral Acitretin, 25 mg once a day and was followed-up regularly every month, for the duration of four months. At the end of four months, clinical improvement was seen with a 70-80% reduction in lesions [Table/Fig-3].



**[Table/Fig-2]:** Histopathology- Scanner view showing hyperkeratosis (yellow arrow), suprabasal acantholysis and clefting (green arrow) seen with retained single layer of basal keratinocytes; High power (40X) view showing corp ronds (green arrow) and grains (yellow arrow) in the epidermis.



**[Table/Fig-3]:** After treatment—Marked clinical improvement of lesions over the right shoulder, right-side of the trunk along T3, T4 and T5 dermatome, right iliac region (lesions marked with blue arrows) seen after four months of treatment with oral acitretin 25 mg.

## DISCUSSION

The DD, also known as Darier-White disease and Keratosis follicularis, is a genodermatosis with an autosomal dominant mode of inheritance with a peak age of onset at puberty. It presents characteristically with multiple keratotic papules primarily in a seborrheic distribution. Among the various types of clinical presentations, the segmental types (type 1 & 2) present with distribution of the lesions along the lines of Blaschko. Type 1 segmental DD is a result of post-zygotic

mutation in the ATP2A2 gene during the embryonic period [1-3]. There is a mutation in the ATP2A2 gene which encodes for Sarco/endoplasmic reticulum calcium ATPase (SERCA) isoform [1]. This gene is responsible for transport of calcium from cytosol to the lumen of endoplasmic reticulum. As a result of which, in DD, there is disruption of intracellular Ca<sup>2+</sup> signalling and keratinocyte intercellular adhesion and differentiation [4].

Kreibich in 1906 described a localised form of DD which follows Blaschko's lines, as was referenced in the previous literatures also [3,5] and patients developed lesions in 3<sup>rd</sup> or 4<sup>th</sup> decade of life with no significant family history [6,7]. The lesions can also be zosteriform, linear, unilateral, or segmental in distribution [5,8]. There are two patterns of segmental DD. In the type1 pattern, lesions occur unilaterally along Blaschko's lines and in the type 2 pattern, the lesions occur focally and are severe in intensity [5,6,9,10]. Due to a post-zygotic somatic mutation in early embryogenesis, localised DD is considered to be a genetic mosaic variant of generalised DD. In localised DD, the lesions follow a Blaschkoid distribution and but not dermatomal [11]. In present case, the lesions were present on the entire right-side of the body with a zosteriform and linear pattern distributed along the lines of Blaschko.

Histopathologically segmental and generalised, DD are indistinguishable. DD is characterised by papillomatous epidermal hyperplasia along with focal suprabasal acantholysis and dyskeratosis. Corps ronds are located in the spinous layer and are large, round acantholytic keratinocytes with dark nuclei surrounded by a bright pink rim of condensed keratin. Grains are flattened cells with thin dark nuclear membrane and bright pink condensed keratin which are located in the stratum corneum [12]. In the present case, histopathology of skin lesions showed dyskeratotic cells (corps ronds and grains).

There are no specific treatment guidelines for treating type 1 segmental DD. However, the goal is to manage symptomatically and improve quality of life. The main stay of treatment involves emphasis on improvement in hygiene, use of cotton clothes and regular use of emollients with intermittent usage of medium-potency topical corticosteroids [13]. Topical retinoids have been found effective in localised forms of DD.

Systemic retinoids are the mainstay of treatment in the generalised form of DD [14]. In the present case, patient was treated with oral

Acitretin 25 mg daily for four months, inferred significant reduction in number of lesions.

## CONCLUSION(S)

Clinical and histopathological correlation are very important to diagnose this rare clinical entity and its variants. This is a unique report of unilateral segmental DD with involvement of the right half of the body, treated with systemic retinoids with significant clinical improvement in lesions over a short span of time.

## REFERENCES

- [1] Palanisamy A, Kandasamy S, Vadivel S, Kothandapany S. Type one segmental Darier's disease. *Indian J Dermatopathol Diagn Dermatol*. 2015;2(2):34-36.
- [2] Medeiros PM, Alves NR, Trujillo JM, Silva CC, Faria PC, Silva RS. Segmental Darier's disease: A presentation of difficult diagnosis. *An Bras Dermatol*. 2015;90(3 Suppl 1):62-65.
- [3] Lin FL, Hu SL, Liang CW. Seasonal recurrence of linear Darier's disease-A case report. *Dermatol Sinica*. 2008;26(4):236-41.
- [4] Burge S, Hovnanian A. Acantholytic disorders of the skin. In: Goldsmith LA, Katz SI, Gilchrist BA, Paller AS, Leffell DJ, Wolff K, editors. *Fitzpatrick's Dermatology in General Medicine*. 8<sup>th</sup> ed. New York: McGraw-Hill; 2012. Pp. 550-62.
- [5] Gilaberte M, Puig L, Vidal D, Alomar A. Acantholytic dyskeratotic naevi following Blaschko's lines: A mosaic form of Darier's disease. *J Eur Acad Dermatol Venereol*. 2003;17(2):196-99.
- [6] O'Malley MP, Haake A, Goldsmith L, Berg D. Localized Darier disease. Implications for genetic studies. *Arch Dermatol*. 1997;133(9):1134-38.
- [7] Starink TM, Woerdeman MJ. Unilateral systematized keratosis follicularis: A variant of Darier's disease or an epidermal naevus (acantholytic dyskeratotic epidermal naevus)? *Br J Dermatol*. 1981;105(2):207-14.
- [8] Itin PH, Büchner SA, Happle R. Segmental manifestation of Darier disease. What is the genetic background in type 1 and type 2 mosaic phenotypes? *Dermatology*. 2000;200(3):254-57.
- [9] Hohl D. Darier disease and Hailey-Hailey disease. In: Bologna JL, Jorizzo JL, Schaffer JV, editors. *Bologna Textbook of Dermatology*. 3<sup>rd</sup> ed. New York: Elsevier; 2012. Pp. 887-97.
- [10] Alsharif SH, Alesa D, Baabdullah A. Type 1 segmental Darier Disease: Case report and discussion of the treatment options. *Case Reports in Dermatology*. 2020;12(3):159-67.
- [11] Reese DA, Paul AY, Davis B. Unilateral segmental Darier disease following Blaschko lines: A case report and review of the literature. *Cutis*. 2005;76:197-200. <https://cdn.mdedge.com/files/s3fs-public/Document/September-2017/076030197.pdf>.
- [12] Suryawanshi H, Dhobley A, Sharma A, Kumar P. Darier disease: A rare genodermatosis. *J Oral Maxillofac Pathol*. 2017;21(2):321.
- [13] Cooper SM, Burge SM. Darier's disease: Epidemiology, pathophysiology, and management. *Am J Clin Dermatol*. 2003;4(2):97-105.
- [14] Christophersen J, Geiger JM, Danneskiold-Samsøe P, Kragballe K, Larsen FG, Laurberg G, et al. A double-blind comparison of acitretin and etretinate in the treatment of Darier's disease. *Acta Derm Venereol*. 1992;72(2):150-52.

### PARTICULARS OF CONTRIBUTORS:

1. Associate Professor, Department of Dermatology, Ramaiah Medical College, Bangalore, Karnataka, India.
2. Assistant Professor, Department of Dermatology, Ramaiah Medical College, Bangalore, Karnataka, India.
3. Postgraduate Student, Department of Dermatology, Ramaiah Medical College, Bangalore, Karnataka, India.
4. Professor, Department of Dermatology, Ramaiah Medical College, Bangalore, Karnataka, India.

### NAME, ADDRESS, E-MAIL ID OF THE CORRESPONDING AUTHOR:

MY Suparna,  
Assistant Professor, Department of Dermatology, Ramaiah Medical College,  
Bangalore, Karnataka, India.  
E-mail: mysuparna.mail@gmail.com

### AUTHOR DECLARATION:

- Financial or Other Competing Interests: None
- Was informed consent obtained from the subjects involved in the study? Yes
- For any images presented appropriate consent has been obtained from the subjects. Yes

### PLAGIARISM CHECKING METHODS: [Jain H et al.]

- Plagiarism X-checker: Mar 11, 2023
- Manual Googling: Apr 03, 2023
- iThenticate Software: Apr 08, 2023 (4%)

### ETYMOLOGY: Author Origin

Date of Submission: **Feb 28, 2023**  
Date of Peer Review: **Mar 25, 2023**  
Date of Acceptance: **Apr 15, 2023**  
Date of Publishing: **May 01, 2023**