

Imaging Implications in Plunging Ranula- A Rare Case Report

SUSHMITHA SUDHARSAN¹, SANKARA ARAVIND WARRIER², VAISHNAVI MUTHUKUMARAN³

(CC) BY-NC-ND

ABSTRACT

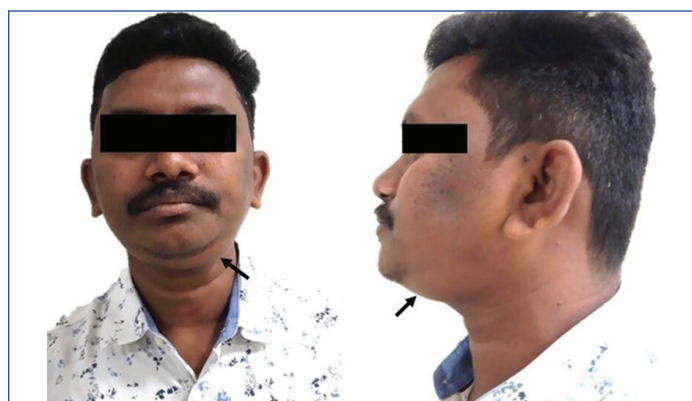Plunging ranula is an intraoral swelling plunging deep into neck and extending beyond the floor of the mouth. Clinical diagnosis is challenging to the clinician as, they mimic other neck lesions like reactive lymphadenopathy, cystic hygroma, thyroglossal duct cyst, abscess and so on. Herein, the authors present a case of a 34-year-old male with history of swollen neck for past three months reported to the outpatient ward. On examination apart from the extraoral swelling in the left side of the neck, there was also an evidence of dome-shaped fluctuant deep seated swelling in the floor of the mouth. Biochemical analysis of the patient was within the normal limits. Further two-dimensional (2D) radiographs findings also, were non contributory. An anechoic presentation indicating fluid-filled sac was evident on ultrasound imaging. Sialogram of the case revealed the classic tail sign indicating a defect beyond the mylohyoid muscle; thus, three-dimensional (3D) imaging paves the way for deriving a final diagnosis. Furthermore, patient has been enlightened about the available treatment options and is under regular follow-up. Adding as a novelty, the present case is discussed with complete clinical, videographic and radiographic presentation of plunging ranula.

Keywords: Cystic lesion, Magnetic resonance imaging, Salivary gland, Sialogram, Ultrasonography

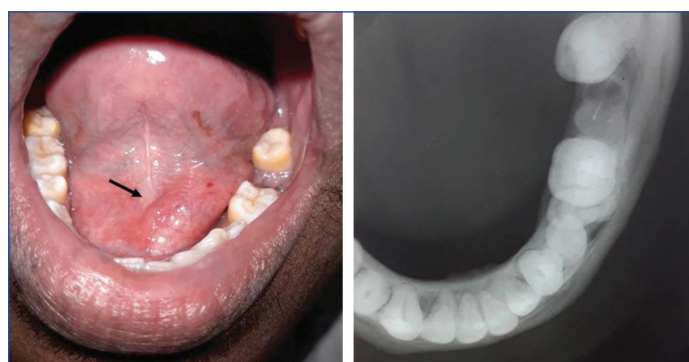CASE REPORT

A 34-year-old male reported to the Department of Oral Medicine with discomfort due to a swelling on the left side of the neck for a period of three months. The swelling was gradually progressive in onset with no other associated symptom of pain. His past medical and dental history were non contributory. Extraoral inspection of the left submandibular region revealed a diffuse swelling roughly measuring of size 3×5 centimetres (cm), extending from the left angle of mandible to the submental region without crossing the midline, round to oval in shape with no other surface changes [Table/Fig-1]. On palpation, the swelling was soft, compressible and non tender. Intraoral examination revealed a well-circumscribed dome-shaped fluctuant swelling around 5×5 cm approximately [Table/Fig-2]. Medially, the swelling extended to the midline of the left side of the floor of the mouth and laterally to the lingual vestibule. Anteroposteriorly, the swelling was limited unilaterally to an imaginary line drawn from the lower left canine to the left first molar, respectively. Bidigital palpation of the swelling was soft, compressible but not reducible and fluctuant. This confirmed that the swelling was deep seated herniating through the mylohyoid muscle [Video-1]. Based on the history and clinical examination, a provisional diagnosis of plunging ranula was considered. In the differential diagnosis, dentoalveolar abscess leading to space infection was considered, due to the presence of root stump in relation to 37 tooth number. Secondly, benign salivary gland pathology was added upon due the site-specific clinical presentation.

Complete blood picture and the thyroid profile were within normal bounds. Mandibular left lateral occlusal radiograph revealed a root stump in relation to 37 tooth number [Table/Fig-3]. Ultrasonography (USG) of the swelling revealed an anechoic, bilobed fluid collection in the left submandibular area with a superficial and deep component extended along the fascial plane features confirming the diagnosis [Table/Fig-4a-c]. Magnetic Resonance (MR) sialogram with Computed Tomography (CT) screening revealed a dilated left submandibular duct in the floor of the mouth and thickened defect of the mylohyoid muscle with sublingual gland herniation, depicting the pathognomonic "Tail sign". Interpretation revealed case of plunging ranula that extends posteriorly to the left submandibular space [Table/Fig-5a,b]. The patient is under regular follow-up and has been planned for surgical management.

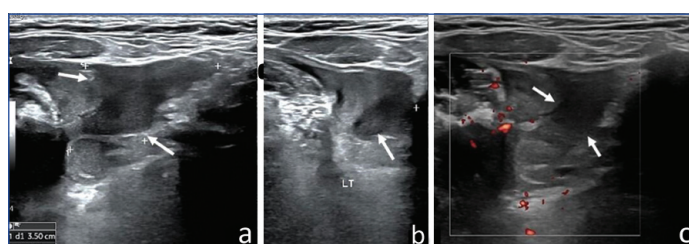


[Table/Fig-1]: Extraoral swelling in the left submandibular region.

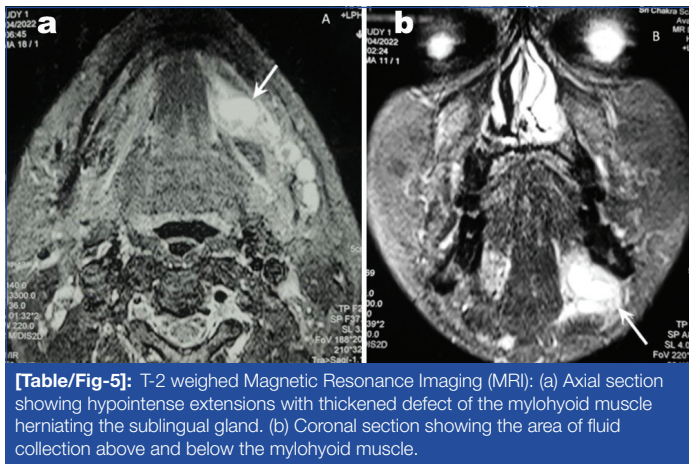


[Table/Fig-2]: A dome-shaped swelling in the left floor of the mouth.

[Table/Fig-3]: Mandibular left lateral occlusal radiograph revealed root stump in relation to 37 tooth number. (Images from left to right)



[Table/Fig-4]: a,b) USG showing an anechoic cystic space with bilobed fluid collection in the left submandibular area. (c) Doppler USG of the swelling reveals no abnormalities.



[Table/Fig-5]: T-2 weighed Magnetic Resonance Imaging (MRI): (a) Axial section showing hypointense extensions with thickened defect of the mylohyoid muscle herniating the sublingual gland. (b) Coronal section showing the area of fluid collection above and below the mylohyoid muscle.

Surgical management is the major treatment modality in a case of plunging ranula. Patient has been enlightened about the planned procedure and favourable treatment outcomes. His concerns regarding the postsurgical aesthetic compliance were cleared by the team. Patient was symptomatically managed with antibiotic and analgesics. Owing to his financial status a time lap was given for further discussion with family members to revert back. Patient is under regular follow-up.

DISCUSSION

A unilateral cystic swelling on the floor of the mouth is a common presentation of ranula [1,2]. "Ranula" a Latin word "rana," means "frog" due to its representation as a transparent underbelly of frog [3]. The penetration of mucous fluid pressure through the mylohyoid muscle filling the submandibular depicts the 'plunging ranula' [4]. Oral sialocysts make up 6% of all cases of ranula, occurring in 0.2% out of every 1000 people whereas, true retention cysts accounts to only 1% to 10% [4,5]. Children and young adults are more likely to have ranulas than older adults with the cervical variant peaking in their third decade [4].

Various aetiological factors are [6]:

- Anatomic discrepancy of the sublingual gland;
- Congenital malformation of the gland;
- Genetic susceptibility of the patient;
- Trauma tot;
- Iatrogenic surgical injury;
- Sadosomochistic habit (e.g., whistling by inserting finger under the tongue).

Clinically, they manifest as a slow-growing, usually unilateral, pliable, painless mass in the floor of the mouth are habitual presentation [5]. The size is usually >2 cm, appearing as a blue-tinged, tense, fluctuant dome-shaped vesicle. The pressure in the fluid causes the swelling to rupture, dissecting through the mylohyoid muscle into the submandibular or submental space forming a plunging or diving ranula [3]. About 45% of patients present with an intraoral swelling as their first symptom, while 34% present with as plunging ranulas [3].

The 2D ultrasonographic imaging technique is predominantly being carried out to study soft tissue pathologies as it is highly sensitive in detecting a relatively small volume of the fluid, non invasive, non ionic and cost effective. The mylohyoid muscle defect is an occasional presentation apart from being a cystic lesion. The largest number of this defect occurs at the junction of the anterior and middle third where the submental vessels travel. The anterior and posterior fibres of the mylohyoid are said to overlap slightly on one other, perhaps culminating to a potential area of dehiscence. This resulting defect is been called as 'boutonnière' and the herniating salivary gland is called the 'bouton' [5]. A simple and direct radiographic approach was introduced by Takimoto T in preoperative identification of

plunging ranulas. This method was done through injecting contrast media into the sublingual region smoothly displacing the glandular ducts surrounding the mass [7]. Jain P, studied the presence of the classic tail sign with USG in 126 plunging ranula cases. A total of 13 patients (10.3%) showed sublingual space fluid, most showed fluid extension through a mylohyoid dehiscence, 2 patients (1.6%) showed fluid within the posterior sublingual space fluid, and only one patient in his entire study revealed all of the components of the characteristically described tail sign [8].

Magnetic Resonance Imaging (MRI) is a valuable tool in assessing the deeper tissue layers which cannot be detected by conventional sonography. Plunging ranulas are frequently characterised by homogenous cystic formations surrounding the sublingual area in the submandibular or parapharyngeal region [5]. MR sialography a non invasive method that characterises the ductal structure of the salivary gland, providing an excellent alternative to conventional sialography. A high resolution Fat-suppressed T2-weighted (FS-T2W) or Fast Spin Echo T2-weighted (FSE-T2W) sequence with surface coil or multichannel head coil are usually performed. It is limited by the acquisition time required for a single sequence and susceptibility to motion. The accuracy of MR sialography in detecting obstructions, stenosis and stricture of the ducts are similar to the conventional sialography. Ranulas appear characteristically on MR imaging due to their high water content. As a result, it has a significant T2-weighted signal intensity and a low T1-weighted proton density that may resemble a lymphatic malformation, especially in a plunging ranula [9]. Tanaka T et al., studied the sublingual gland duct visualisation using MR sialography in seven patients with sublingual salivary gland diseases. In one patient with a ranula, the lesion could be correctly diagnosed as a ranula by MR sialography because the mass was clearly derived from sublingual gland ducts [10]. A CT scan is useful in guiding the surgeon for soft-tissue planes and spaces involved in the neck region. Ranulas typically have an oval form with a homogeneous core attenuation area that ranges from 10 to 20 Hounsfield Unit (HU). The detailed mapping provided by the CT scan assists in planning approach for the excision and thus, minimising recurrence [3,9].

Differential diagnosis of dentoalveolar abscess leading to space infection was overruled by radiographic diagnosis whereas, benign salivary gland pathology was ruled out on ultrasound and 3D MRI. Other differentials of cervical ranula may include soft tissue swellings of the neck such as infectious cervical lymphadenopathy (tuberculosis, Epstein-Barr virus, cat scratch disease,) submandibular sialadenitis, cystic or neoplastic thyroid disease, branchial cleft cyst, cystic hygroma, lipoma, laryngocele, intramuscular haemangioma and dermoid cyst. Cervical ranula have high frequency of recurrence, if not completely resected, as they have the tendency to dissect through the midline [3,11].

CONCLUSION(S)

The diagnostic imaging modalities of plain radiographs, sialography, and ultrasound are adequate in differentiating ranulas among various entities. However, the surgical need for delineating the extent of any cystic swelling necessitates the 3D imaging approach. Similarly, in the present case, along with baseline radiological imaging of occlusal radiograph and ultrasonogram, MR sialogram with CT screening was executed to prove the clinical diagnosis and for a proper surgical planning. An elaborate patient history, clinical examination, USG, MRI or CT imaging, and fluid aspiration plays a pivotal role for the clinician to successfully attain an early prompt diagnosis.

REFERENCES

- [1] Olojede ACO, Ogundana OM, Emeka CI, Adewole RA, Emmanuel MM, Gbotolorun OM, et al. Plunging ranula: Surgical management of case series and the literature review. Clin Case Rep. 2017;6(1):109-14.
- [2] Gupta A, Karjodkar FR. Plunging Ranula: A case report. ISRN Dentistry. 2011;2011:806928.

- [3] Dhingra R, Davessar J, Pushkal, Vignesh AK, Sharma S. Plunging ranula in 26 years old male: a case report. *Int J Otorhinolaryngol Head Neck Surg.* 2020;6:1009-12.
- [4] Ayers E. Plunging ranula: A case report. *Journal of Diagnostic Medical Sonography.* 2018;34(3):875647931876763.
- [5] Jain P, Jain R, Morton RP, Ahmad Z. Plunging ranulas: High-resolution ultrasound for diagnosis and surgical management. *Eur Radiol.* 2010;20(6):1442-49.
- [6] Bishen KA, Singh A, Limaye M, Mishra K. Bilateral plunging ranula due to habitual etiology. *J Oral Health Comm Dent.* 2017;11(1):19-22.
- [7] Takimoto T. Radiographic technique for preoperative diagnosis of plunging ranula. *Journal of Oral and Maxillofacial Surgery.* 1991;49(6):659.
- [8] Jain P. Plunging Ranulas and prevalence of the "Tail Sign" in 126 consecutive cases. *Journal of Ultrasound in Medicine.* 2019;39(2):273-78.
- [9] Ugga L, Ravanelli M, Pallottino AA, Farina D, Maroldi R. Diagnostic work-up in obstructive and inflammatory salivary gland disorders. *Acta Otorhinolaryngol Ital.* 2017;37(2):83-93.
- [10] Tanaka T, Oda M, Wakasugi-Sato N, Joujima T, Miyamura Y, Habu M, et al. First report of sublingual gland ducts: Visualization by dynamic mr sialography and its clinical application. *J Clin Med.* 2020;9(11):3676.
- [11] Charnoff SK, Carter BL. Plunging ranula: CT diagnosis. *Radiology.* 1986;158(2):467-68.

PARTICULARS OF CONTRIBUTORS:

- Lecturer, Department of Oral Medicine and Radiology, Sri Ramachandra Institute of Higher Education and Research (Deemed to be University), Chennai, Tamil Nadu, India.
- Professor and Head, Department of Oral Medicine and Radiology, Sri Ramachandra Institute of Higher Education and Research (Deemed to be University), Chennai, Tamil Nadu, India.
- Postgraduate, Department of Oral Medicine and Radiology, Sri Ramachandra Institute of Higher Education and Research (Deemed to be University), Chennai, Tamil Nadu, India.

NAME, ADDRESS, E-MAIL ID OF THE CORRESPONDING AUTHOR:

Vaishnavi Muthukumaran,
1, Mount Poonamallee Road, Sri Ramachandra Nagar, Ramachandra Nager,
Chennai-600116, Tamil Nadu, India.
E-mail: d0720002@sriher.edu.in

PLAGIARISM CHECKING METHODS: [\[Jain H et al.\]](#)

- Plagiarism X-checker: Feb 13, 2023
- Manual Googling: Feb 25, 2023
- iThenticate Software: Mar 10, 2023 (14%)

ETYMOLOGY: Author Origin**AUTHOR DECLARATION:**

- Financial or Other Competing Interests: None
- Was informed consent obtained from the subjects involved in the study? Yes
- For any images presented appropriate consent has been obtained from the subjects. Yes

Date of Submission: **Feb 03, 2023**Date of Peer Review: **Feb 21, 2023**Date of Acceptance: **Mar 11, 2023**Date of Publishing: **May 01, 2023**