

Unilateral Traumatic Atresia of External Auditory Canal: A Case Report

PRIYA KANAGAMUTHU¹, SANDEEP UNNIKRISHNAN², RAGHVI ANAND³

(CC) BY-NC-ND

ABSTRACT

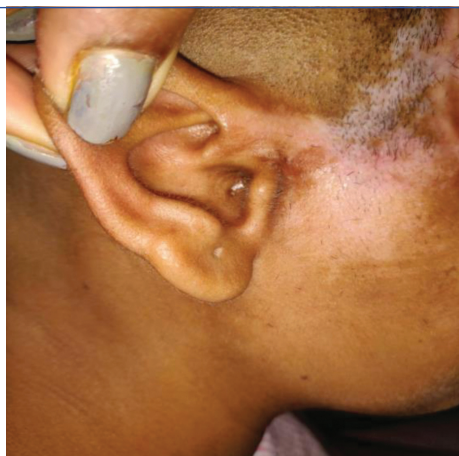External Auditory Canal (EAC) atresia, which can be acquired or congenital, is a condition in which the EAC is not present. A blind sac in the external acoustic meatus is the result of intraluminal or extraluminal processes of various aetiologies, which can lead to acquired atresia of the EAC. Acquired EAC atresia is a rare disorder of the EAC, and it is extremely uncommon for it to be brought on by direct trauma. In present investigation, a 31-year-old female patient, leading to onset of right temporal discomfort and impaired hearing in the right ear. On examination, a 10×1 cm tender scar was present extending from right parietal region till right zygomatic arch with stenosis in the right external auditory meatus. Facial nerve examination revealed loss of wrinkling on right side with slight deviation of the angle of mouth to left side. High Resolution Computed Tomography (HRCT) temporal bone showed soft tissue causing complete occlusion of right EAC. Patient underwent right EAC atresioplasty with canaloplasty and canal reconstruction. Facial nerve weakness persisted postoperatively. Patient is still on follow-up and has improved symptomatically with no restenosis. Surgical management of EAC atresia is very challenging, thus it needs meticulous planning and long term follow-up for good results which was evident in the present case.

Keywords: Canaloplasty, Facial nerve, Meatoplasty, Restenosis

CASE REPORT

A 31-year-old female patient came with complaints of pain over the right temporal region for past five months following an alleged history of Road Traffic Accident (RTA). Patient also gave history of right ear discharge which settled with medications and loss of consciousness for few minutes postroad traffic accident. No history of vomiting, seizures or visual disturbances postroad traffic accident was present. Patient complained of impaired hearing in right ear but no complaints with respect to left ear. No known co-morbidities and no significant family history were present.

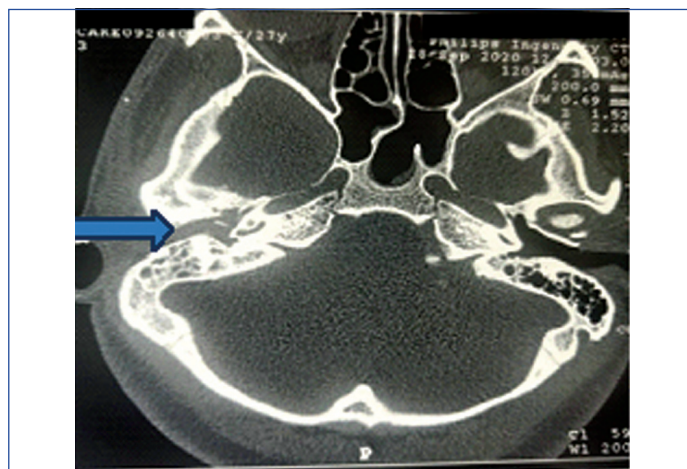
On examination, a 10×1 cm scar was present extending from right parietal region till right zygomatic arch with tenderness over the scar [Table/Fig-1]. Tenderness was also present over right preauricular and postauricular region. Stenosis was present in the right external auditory meatus hiding the visibility of the tympanic membrane. There was tenderness over the stenosed area. Facial nerve examination showed loss of wrinkling on the right side with slight deviation of the angle of mouth to left side.



[Table/Fig-1]: Post-traumatic right ear showing External Auditory Canal (EAC) atresia.

Patient was provisionally diagnosed to have right ear External Auditory Canal (EAC) atresia secondary to trauma with right sided facial nerve palsy. Photographs were taken after obtaining informed and written consent from the patient.

Pure tone audiometry could not be performed due to severe tenderness over right EAC. High Resolution Computed Tomography (HRCT) temporal bone revealed soft tissue causing complete occlusion of right EAC and filling entire middle ear and mastoid air cells [Table/Fig-2].



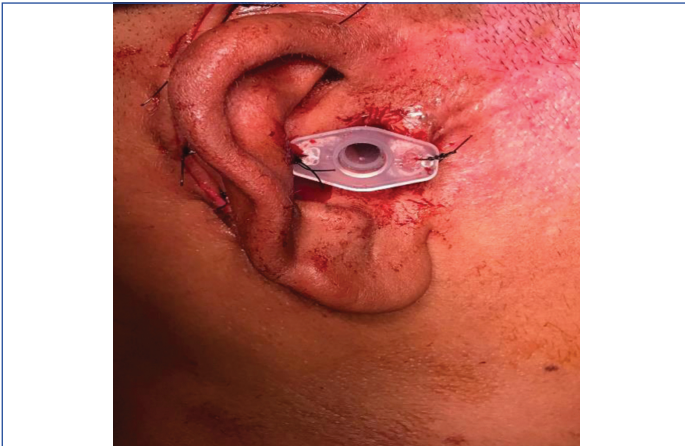[Table/Fig-2]: High resolution computed tomography temporal bone-axial view showing right External Auditory Canal (EAC) atresia (Blue arrow).

A diagnosis of right ear traumatic EAC atresia with right sided facial nerve palsy was made and after getting proper consent patient was taken for right EAC atresioplasty with canaloplasty and canal reconstruction.

Operative Procedure

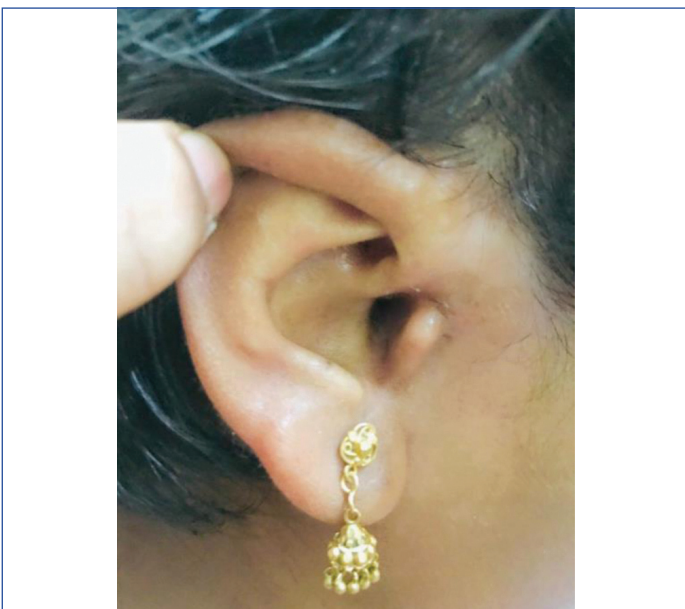
Under general anaesthesia with orotracheal intubation, patient was placed in supine position with head turned to left side, parts painted and draped. Local infiltration was given with premixed xylocaine with adrenaline in the stenosed part of EAC. Circular incision was made in the external auditory meatus and soft tissues were removed. Local infiltration given in the postauricular region, William Wilde's incision was made and periosteum was elevated. Cartilagenous part of EAC was found in fragments and firmly attached to surrounding soft tissues and the same was removed. Tympanomeatal flap was found to be unhealthy and the same was removed. Small perforation

was noted in anterosuperior quadrant of tympanic membrane. Bony part of EAC widened using diamond burr. The postaural incision was extended superiorly, temporalis fascia was harvested. The perforation was sealed by overlay technique using temporalis fascia. Gel foam placed in bony part of EAC. A stent was kept by using a 1cc syringe which was cut into half and placed up to bony cartilagenous junction of EAC and gel foam was placed surrounding it. Postauricular incision was sutured and stay sutures applied to stent [Table/Fig-3] and mastoid dressing done. Complete haemostasis was maintained throughout the procedure. Patient was extubated and shifted to postoperative care unit under stable condition.



[Table/Fig-3]: Immediate postoperative image of right ear showing stent placed upto bony-cartilagenous junction of External Auditory Canal (EAC).

Facial nerve weakness persisted postoperatively. Hence, patient was managed with oral steroids, physiotherapy, facial exercises and eye care. The stent was removed after a period of four weeks during postoperative visit. Patient is on continuous follow-up and facial nerve weakness has improved. No restenosis has so far occurred [Table/Fig-4].



[Table/Fig-4]: Four months postoperative image showing good recovery with no evidence of restenosis of right ear.

DISCUSSION

The EAC atresia can be of two types, acquired or congenital. It is a condition in which there is an absence of a patent EAC [1,2]. Atresia can be membranous or solid. Congenital aural stenosis can be divided into three subgroups: (i) stenosis combined with cholesteatoma; (ii) stenosis combined with hearing loss; (iii) stenosis without cholesteatoma and with normal hearing. The degree of stenosis (diameter) and curvature of the osseous EAC are risk factors for EAC cholesteatoma formation [3,4].

Acquired EAC atresia is a rare disorder of the EAC [5,6]. A number of factors, including inflammatory diseases, trauma, burns, and surgery, can result in acquired atresia of the EAC. Chronic inflammation in EAC leads to subepithelial inflammation caused by the invasion of inflammatory cells, which causes fibrosis of the canal resulting in EAC stenosis [7]. Chronic otitis externa is one of the most typical causes of acquired EAC atresia [8]. However, several reported series characterised these patients as idiopathic, since they were unable to identify a specific aetiology for the inflammatory process affecting the EAC while others raised the possibility of a connection with systemic dermatologic disorders like eczema or lichen planus, which can affect the skin around the auditory canal [9]. There are only very few cases of post-traumatic atresia [10,11].

In the present case report, patient complained of pain over the right temporal region for past five months following an alleged history of road traffic accident. HRCT temporal bone revealed soft tissue causing complete occlusion of right EAC. This was similar to a study by Sahoo SR and Sarma M, where a 37-year-old male with a history of RTA 10 years back, had bleeding from left ear and decreased hearing [12]. CT revealed soft tissue density causing stenosis of left EAC.

Surgery should be the treatment of choice in post-traumatic EAC stenosis. The goal of the surgery is to remove the fibrous plug/debris, widen the bony EAC, expose the tympanic membrane, and recreate an epithelial lined EAC. Complete resection of fibrous plug with canalplasty and re-epithelisation of EAC with split skin thickness skin grafts should be the treatments of choice to achieve a patent EAC for a long period of time [13-15]. By performing canalplasty and meatoplasty frequently and carefully arranging skin grafts, it is possible to halt the formation of granulation tissue and further scarring [16]. In this case, a postaural approach was taken and atresioplasty with canalplasty was done along with canal reconstruction.

According to the study by Zeeshan S et al., where a patient with a history of burn injuries to left ear had presented with gross deformity, resulting in complete occlusion of the EAC [17]. HRCT scan of temporal bone had demonstrated complete occlusion with a soft tissue density lesion filling the left EAC. Similar to the present case report, postauricular approach was used. After removal of cholesteatoma debris and the reconstruction of the atretic portion of EAC, the bare area had been covered with redundant skin obtained from the fibrous partition, augmented with wide meatoplasty. Regular dressing of the wound had been done using hydrogen peroxide, oxum spray, povidone iodine and the ear canal antibiotic merocel packs had been periodically replaced to prevent restenosis whereas in present case report, an EAC stent was used for period of four weeks instead.

Split-thickness Skin Graft (STSG) reconstruction with conchomeatoplasty, canalplasty, and atresioplasty is another treatment option and a satisfactory surgical outcome may depend on the use of an STSG [18]. Another option is modified meatoplasty for EAC stenosis with endoaural-conchal incision [19]. It offers a functionally adequate and cosmetically acceptable result. Another technique is an endaural approach with the use of either alloderm or epidermal allograft instead of a skin graft. The rationale for this application was to eliminate the donor site, adding to ease of the surgery and the postsurgical care. This also reduces cost associated with surgical supplies and operating time [20].

Some studies show that stenosis of the EAC is particularly challenging to cure and has a high rate of recurrence after therapy [21-23]. The likelihood of restenosis, which is brought on by granulation and secondary healing, presents a problem in the treatment of this condition [24,25]. As seen in some studies, early restenosis is typically caused by poor surgical technique that leaves the fibrous plug partially in place or does not adequately cover the

exposed bone [9,12,26]. In the present case report, no restenosis has so far occurred.

CONCLUSION(S)

The present case report was of right ear traumatic EAC atresia. Postauricular approach was used and atresioplasty with canaloplasty was done along with canal reconstruction. The stent used in this case was not only beneficial in achieving good postoperative result but was also cost-effective. Thus, in order to obtain the desired result, meticulous preoperative planning should be done followed by periodic postoperative visits to monitor for restenosis.

REFERENCES

- [1] Willis RG, Kahn SA, Brevard SB. Traumatic acute external auditory canal stenosis. *Am Surg*. 2017;83(9):386-88.
- [2] Luong A, Roland PS. Acquired external auditory canal stenosis: Assessment and management. *Curr Opin Otolaryngol Head Neck Surg*. 2005;13(5):273-76.
- [3] Casale G, Nicholas BD, Kesser BW. Acquired ear canal cholesteatoma in congenital aural atresia/stenosis. *Otol Neurotol*. 2014;35:1474-79.
- [4] Yin D, Li C, Juan H, Li J, Yang L, Zhang T, et al. Morphological characteristics of osseous external auditory canal and its relationship with external auditory canal cholesteatoma in patients with congenital aural stenosis. *Otol Neurotol*. 2017;38:1528-34.
- [5] Stucker FJ, Shaw GY. Revision meatoplasty: Management emphasizing de-epithelialized postauricular flaps. *Otolaryngol Head Neck Surg*. 1991;105:433-39.
- [6] Namysłowski G, Scierski W, Mrówka-Kata K, Bilińska-Pietraszek E, Turecka L. Surgical treatment of acquired external auditory canal atresia. *Otolaryngol Pol The Pol otolaryngol*. 2002;56(1):63-67.
- [7] Ghani A, Smith M. Postinflammatory medial meatal fibrosis: Early and late surgical outcomes. *J Laryngol Otol*. 2013;127:1160-68.
- [8] Jacobsen N, Mills R. Management of stenosis and acquired atresia of the external auditory meatus. *J Laryngol Otol*. 2006;120(4):266.
- [9] Kmeid M, Nehme J. Post-inflammatory acquired atresia of the external auditory canal. *J Otol*. 2019;14(4):149-54.
- [10] Droessaert V, Vanspauwen R, Offeciers E, Zarowski A, Dinther JV, Somers T. Surgical treatment of acquired atresia of the external auditory ear canal. *Int Arch Otorhinolaryngol*. 2017;21(4):343-46.
- [11] Dhooge I, D'hoop M, Loose D, Acke F. Acquired atresia of the external auditory canal: long-term clinical and audiometric results after surgery. *Otol Neurotol*. 2014;35(7):1196-200.
- [12] Sahoo SR, Sarma M. A case of acquired external auditory canal stenosis following trauma. *Indian J Health Sci Biomed Res*. 2021;14:390-91.
- [13] Roland PS. Chronic external otitis. *Ear Nose Throat J*. 2001;80(suppl):12-16.
- [14] Kumar A, Sarkar A, Kumar S. Post traumatic external auditory canal stenosis causing conductive hearing loss. *Astro*. 2016;3(3):174-76.
- [15] McCary WS, Kryzer TC, Lambert PR. Application of split thickness skin grafts for acquired diseases of the external auditory canal. *Am J Otol*. 1995;16:801-05.
- [16] El-Sayed Y. Acquired medial canal fibrosis. *J Laryngol Otol*. 1998;112(2):145-49.
- [17] Zeeshan S, Alam M, Chandra K. Acquired atresia of external auditory canal with canal cholesteatoma: A case report. *Int J Current Adv Res*. 2017;6:8388-92.
- [18] Selesnick S, Nguyen TP, Eisenman DJ. Surgical treatment of acquired external auditory canal atresia. *Am J Otol*. 1998;19(2):123-30.
- [19] Chen Y, Zhang T. Modified meatoplasty for external auditory canal stenosis with endoaural-conchal incision. *Otol Neurotol*. 2015;36(1):01-03.
- [20] Farhood Z, Muus JS, Chang DK, Edmonds JL. Case series: A novel technique for the treatment of external auditory canal stenosis. *Int J Pediatr Otorhinolaryngol*. 2015;79(10):1765-70.
- [21] Magliulo G. Acquired atresia of the external auditory canal: Recurrence and long-term results. *Ann Otol Rhinol Laryngol*. 2009;118(5):345-49.
- [22] Stultiens JJ, Huygen PL, Oonk AM, Mylanus EA, Kunst HP, Hol MK, et al. Hearing results of surgery for acquired atresia of the external auditory canal. *Otol & Neuro*. 2019;40(5S):S43-50.
- [23] Keller RG, Ong AA, Nguyen SA, O'Connell BP, Lambert PR. Postinflammatory medial canal fibrosis: An institutional review and meta-analysis of short-and long-term outcomes. *The Laryng*. 2017;127(2):488-95.
- [24] Tos M., Balle B. Postinflammatory acquired atresia of the external auditory canal: Late results of surgery. *Am J Otol*. 1986;7:365-70.
- [25] Cremers WR, Smeets JH. Acquired atresia of the external auditory canal: Surgical treatment and results. *Arch Otolaryngol Head Neck Surg*. 1993;119(2):162-64.
- [26] Slattery WH, Saadat P. Postinflammatory medial canal fibrosis. *Am J Otol*. 1997;18:294-97.

PARTICULARS OF CONTRIBUTORS:

1. Professor, Department of Otorhinolaryngology, Chettinad Academy of Research and Education, Chettinad Hospital and Research Institute, Chennai, Tamil Nadu, India.
2. Professor, Department of Plastic Surgery, Chettinad Health City, Chennai, Tamil Nadu, India.
3. Junior Resident, Department of Otorhinolaryngology, Chettinad Academy of Research and Education, Chettinad Hospital and Research Institute, Chennai, Tamil Nadu, India.

NAME, ADDRESS, E-MAIL ID OF THE CORRESPONDING AUTHOR:

Dr. Priya Kanagamuthu,
No. A6, Ground Floor, Staff Villa, Chettinad Health City, Chennai, Tamil Nadu, India.
E-mail: catchpriya.29@gmail.com

PLAGIARISM CHECKING METHODS: [Jain H et al.]

- Plagiarism X-checker: Nov 24, 2022
- Manual Googling: Jan 20, 2023
- iThenticate Software: Feb 07, 2023 (15%)

ETYMOLOGY: Author Origin

AUTHOR DECLARATION:

- Financial or Other Competing Interests: None
- Was informed consent obtained from the subjects involved in the study? Yes
- For any images presented appropriate consent has been obtained from the subjects. Yes

Date of Submission: **Nov 12, 2022**

Date of Peer Review: **Dec 13, 2022**

Date of Acceptance: **Feb 08, 2023**

Date of Publishing: **Jun 01, 2023**