

Scrape to Nail the Diagnosis: A “Mitey” Challenge in an Erythroderma

S PRAVEEN KUMAR¹, TK SUMATHY², AL SHYAM PRASAD³, ARCHANA LAKSHMAN⁴

ABSTRACT

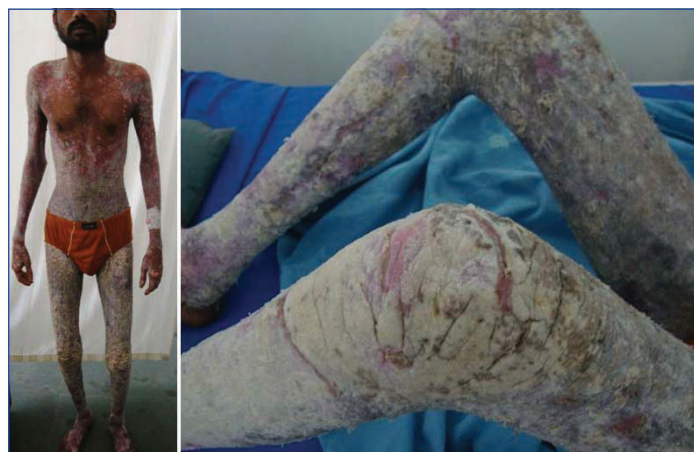Norwegian (crusted) scabies is a highly contagious form of scabies which can evolve into erythroderma at times. We herein report a case of a 29-year-old male patient, an established case of Epidermolysis Bullosa Dystrophica (EBD), presented to us with asymptomatic generalised scaling and crusting of two months duration. On examination patient also had dystrophic nails, anonychia and joint contractures. With a high index of suspicion, a scraping for KOH mount was done, which showed numerous scabies mites, eggs and faecal pellets. The patient was started on weekly oral Ivermectin (200 mcg/kg) and topical 5% permethrin application. There was dramatic response within 1-2 weeks. This case is presented to highlight the diagnostic challenge that erythroderma may be due to Norwegian scabies or the primary entity- EBD. The association of EBD and Norwegian scabies has been reported in literature. A simple bedside test like scraping can nail the diagnosis, provided there is a high index of suspicion.

Keywords: Epidermolysis bullosa, Ivermectin, Scabies

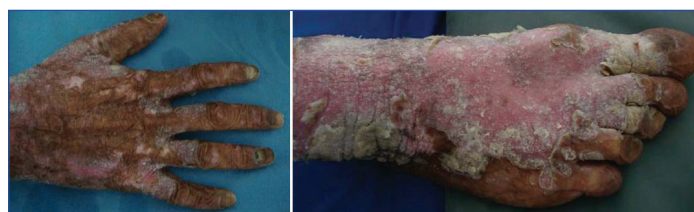CASE REPORT

A 29-year-old male patient presented to us with asymptomatic generalised scaling and crusting of two months duration. Patient was a case of Epidermolysis Bullosa Dystrophica (EBD) and was on phenytoin since past 10 years. Cutaneous examination revealed generalised scaling and thick hyperkeratotic crusts, accentuated over extremities with joint contractures [Table/Fig-1,2]. He also had erosions, scarring, dystrophic nails and anonychia [Table/Fig-3,4].

for the same. With a high index of suspicion, a scraping for KOH mount was done from the patient which showed numerous scabies mites, eggs and faecal pellets [Table/Fig-5]. HIV I and II ELISA were negative. A final diagnosis of erythroderma secondary to crusted scabies was made.

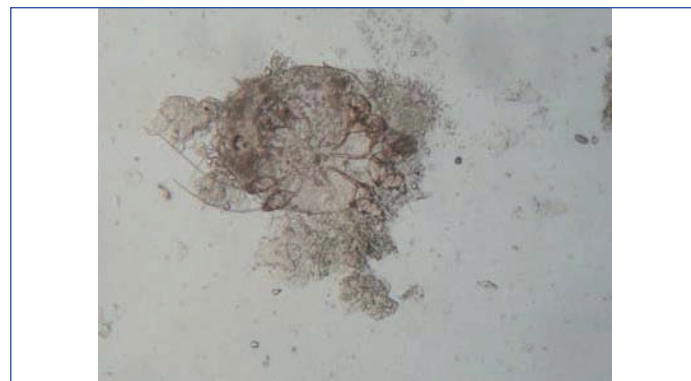


[Table/Fig-1,2]: Showing hyperkeratotic extensive scaling with accentuation over extremities. (Images from left to right)



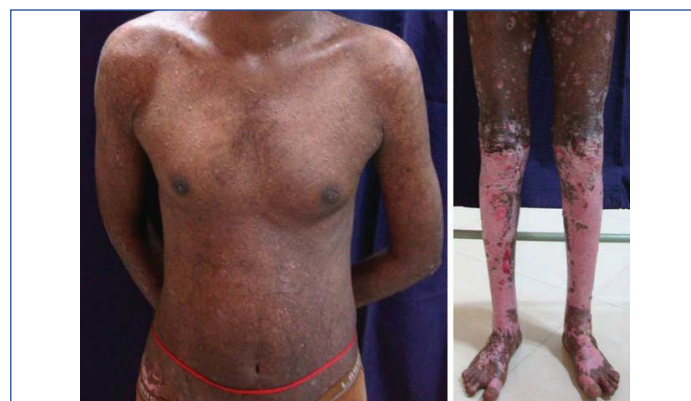[Table/Fig-3,4]: Dystrophic nails and anonychia with atrophic scars. (Images from left to right)

The erythroderma was initially treated with isotretinoin, presuming the cause to be EBD but had to be discontinued as the patient developed visual and auditory hallucinations. He had extensive exfoliation associated with burning sensation. Meanwhile, his mother who was attending to him was diagnosed with scabies and treated



[Table/Fig-5]: *Sarcoptes scabiei* (KOH mount 40X).

The patient was started on weekly oral Ivermectin (200 mcg/kg) and topical 5% permethrin applications. There was dramatic response within 1-2 weeks. Weekly topical 5% permethrin applications were continued for a total of six weeks. At six weeks patient had complete resolution of erythroderma, however only few bullae over the legs reminiscent of his EBD were present [Table/Fig-6,7].



[Table/Fig-6,7]: Complete resolution at six weeks. (Images from left to right)

DISCUSSION

Norwegian scabies is a highly contagious form of scabies. The term ‘Norwegian’ is derived from the description of the entity by Danielssen and Boeck in lepers of Norway. Hebra described this entity as “scabies Norvegica Boeckii”. It has been suggested that the term “Norwegian” be replaced with “crusted” [1]. Norwegian scabies can evolve into erythroderma at times. In our case, the diagnostic challenge was the simultaneous presence of Norwegian scabies as well as epidermolysis bullosa dystrophica, wherein each of these entities may have presented with erythroderma.

The causes of erythroderma in an adult are diverse, which include psoriasis, drug reactions, seborrhoeic dermatitis, atopic dermatitis, haematological malignancies, pityriasis rubra pilaris, pemphigus foliaceus, underlying immunosuppression [2] and crusted scabies. The incidence of crusted scabies in erythroderma ranges from 1-1.25% [3].

The contributory factors associated with crusted scabies include diseases with physical incapacity (epidermolysis bullosa, severe arthropathy, paresis), diseases with skin anaesthesia, diseases with mental impairment and conditions with underlying immunosuppression [4].

Clinically, crusted scabies is characterised by extensive hyperkeratosis and crusting of skin, accentuated on the acral areas. There is a peculiar sand-like quality of the scales which may suggest the diagnosis. The nail apparatus is frequently affected, with masses of horny debris accumulating beneath the thickened and discoloured nails. Itching is often absent, but may occasionally be severe [5].

Our case is unique, because initially the treatment for erythroderma (probably secondary to EBD) with isotretinoin showed worsening of cutaneous lesions with precipitation of psychiatric symptoms. In this scenario, an alternative diagnosis with a high index of suspicion of crusted scabies was made. The pointers towards this include family history of scabies in mother and an associated risk factor of absence of nails (however, patient did not have pruritus). In an immunocompetent host, the defensive act of scratching may eliminate some of the parasites in acarid tunnels. The use of topical [5] and systemic steroids may be a predisposing factor for Crusted scabies. In a case report by Van Der Wal et al., also similar picture of scaling and erythroderma with epidermolysis bullosa dystrophica has been reported [6]. But in their case patient did not tolerate permethrin applications and they had treated with topical gamma benzene hexa chloride and oral ivermectin, repeated weekly.

A simple bedside test- “skin scraping for KOH mount” was performed. To our surprise, numerous mites, eggs and scybala were found. This indicates that in a non responsive erythroderma, an alternate diagnosis should always be considered and simple bedside procedures should be performed mandatorily. Norwegian scabies presents a serious therapeutic problem as it is resistant to treatment and relapses frequently. The treatment of crusted scabies includes weekly oral Ivermectin (200 mcg/kg) in combination with topical scabicides. Oral methotrexate can be used in resistant cases. Relapses may occur from subungual spaces and scalp, which are difficult-to-reach areas with topical agents. Recently, several studies have shown oral Ivermectin as a safe and promising agent [7]. The introduction of oral Ivermectin to the therapeutic armamentarium has revolutionized the treatment of scabies especially the crusted variety, as seen in our case.

CONCLUSION(S)

Erythroderma is caused by myriad reasons and when it is unresponsive to appropriate and adequate standard treatment, it is essential to evaluate for the less common underlying causal entities. The association of EBD and Norwegian scabies is reported in literature. In our case the patient may have developed crusted scabies due to a: (i) modified host response; (ii) inability to scratch due to dystrophic and absent nails.

A delay in diagnosis of even a single case of crusted scabies can lead to a massive institutional outbreak of scabies which is a daunting task to control. Hence, a simple bedside test like scraping can nail the diagnosis provided there is a high degree of suspicion. Oral ivermectin repeated at weekly intervals shows promising results as seen in our case.

REFERENCES

- Parish LC, Lomholt G. Crusted scabies alias Norwegian scabies. *Int J Dermatol.* 1976;15:747-48.
- Jucowics P, Ramon ME, Don PC, Stone RK, Bamji M. Norwegian scabies in an infant with acquired immunodeficiency syndrome. *Arch Dermatol.* 1989;125:1670-71.
- Ekmekeci TR, Koslu A. Erythrodermic crusted scabies in a young healthy man. *Dermatology Online Journal.* 2006;12(6):23.
- Espy PD, Jolly HW. Norwegian scabies: Occurrence in a patient undergoing immunosuppression. *Arch Dermatol.* 1976;112:193-96.
- Mehta V, Balachandran C, Monga P, Roa R, Roa L. Norwegian scabies presenting as erythroderma. *Indian J Dermatol Venereol Leprol.* 2009;(75):609-10.
- Van Der WalVB, VanVoorst Vader PC, Mandema JM, Jonkman MF. Crusted (Norwegian) scabies in a patient with dystrophic epidermolysisbullosa. *BJD.* 1999;141(5):918-21.
- Angelo C, Pedicelli C, Provini A, Annessi G, Zambruno G, Paradisi M, et al. Successful treatment of Norwegian scabies with ivermectin in a patient with recessive dystrophic epidermolysisbullosa. *Minerva Pediatr.* 2004;56(3):353-57.

PARTICULARS OF CONTRIBUTORS:

- Associate Professor, Department of Dermatology, Ramaiah Medical College, MSRIT Post, Bengaluru, Karnataka, India.
- Senior Professor and Head, Department of Dermatology, Ramaiah Medical College, MSRIT post, Bengaluru, Karnataka, India.
- Adjunct Professor, Department of Dermatology, Ramaiah Medical College, MSRIT Post, Bengaluru, Karnataka, India.
- Ex-Senior Resident, Bangalore Medical College and Research Institute, Bengaluru, Karnataka, India.

NAME, ADDRESS, E-MAIL ID OF THE CORRESPONDING AUTHOR:

Dr. S Praveen Kumar,
Associate Professor, Department of Dermatology, Ramaiah Medical College and Teaching Hospital, MSRIT Post, Bengaluru-560054, Karnataka, India.
E-mail : drpraveen.1982@gmail.com

AUTHOR DECLARATION:

- Financial or Other Competing Interests: None
- Was informed consent obtained from the subjects involved in the study? Yes
- For any images presented appropriate consent has been obtained from the subjects. Yes

PLAGIARISM CHECKING METHODS: [Jain H et al.]

- Plagiarism X-checker: Mar 28, 2023
- Manual Googling: Mar 28, 2023
- iThenticate Software: May 05, 2023 (9%)

ETYMOLOGY: Author Origin

Date of Submission: **Apr 10, 2015**
Date of Peer Review: **Jul 08, 2015**
Date of Acceptance: **Sep 20, 2015**
Date of Publishing: **Jun 01, 2023**