

Clinical Features of Post Fever Retinitis and Visual Outcomes with Oral Corticosteroids: A Retrospective Study

SANJANASHREE S PATIL¹, VISHALAKSHI², CHARUSHILA V GEJAPATI³

ABSTRACT

Introduction: Post Fever Retinitis (PFR) is an infectious or parainfectious uveitis presenting with visual impairment after a fever episode. The condition can cause potential visual impairment in PFR patients. There is no national guideline for treatment of PFR. Hence, there is a need to study the clinical features and visual outcomes with the use of corticosteroid therapy.

Aim: To describe the clinical features of patients presenting with PFR and visual outcome with the oral corticosteroid therapy.

Materials and Methods: This retrospective study conducted in the Outpatient Department (OPD) of Ophthalmology at SDM College of Medical Sciences and Hospital, Dharwad, Karnataka, India. The duration of the study was 35 months, from January 2019 to December 2021. A total of 23 eyes of 13 patients treated with oral corticosteroids were included. Data collected included patients' demographic details including name, age, sex, hospital identification number, duration of vision loss, detailed ophthalmic examination findings, including visual acuity testing with Snellen's chart, slit lamp examination findings and fundus examination findings, including detailed fundus drawings,

Optical Coherence Tomogram (OCT) and fundus photographs. Visual Acuity (VA) at the time of presentation and after steroid therapy were recorded. Data was entered in microsoft excel spreadsheet and descriptive analysis was done.

Results: Age of the study participants ranged from 15 years to 52 years with an average of 29.6 years. A total of 23 eyes of 13 patients were included in the present study. At the time of presentation, two eyes had visual acuity better than 6/12 on Snellen's chart. Five eyes had mild vision impairment, five eyes had moderate vision impairment and eleven eyes had vision <3/60, according to the visual impairment classification of World Health Organisation (WHO). Macular oedema was the other most common finding seen in 12 (52.17%) eyes. All the patients showed beginning of resolution of retinitis by 2-3 weeks after starting oral corticosteroids. A total of 23 eyes, 8 (34.7%) eyes recovered vision >6/12, out of which 6 (26.08%) eyes recovered with 6/6 vision.

Conclusion: PFR affects predominantly young immunocompetent individuals. Treatment outcomes with oral steroids is found to be satisfactory.

Keywords: Macular oedema, Oral steroid therapy, Parainfectious uveitis, Visual acuity

INTRODUCTION

The PFR is an infectious or para infectious uveitis entity caused by several organisms, presenting as focal or multifocal retinitis. It is commonly seen in tropical countries and can be caused due to several viruses or bacterial agents, usually presenting days to weeks after the initial febrile episode [1]. The exact aetiopathogenesis of this condition is unclear. Most of the time the patient is afebrile and systemic features are absent at the time of presentation to the ophthalmologist. It may not be possible to pin point an underlying aetiological agent in all the cases. However, it is prudent to rule out the treatable bacterial causes which might have caused the PFR episode. Knowledge of the recent outbreaks or endemic infections in the region may point to a probable aetiology. There is no set guideline for treatment of cases of PFR. Ophthalmologists generally treat these cases with high dose corticosteroids with or without antibiotics [2]. There are not many studies about PFR from Northern Karnataka region, and only case reports having been published so far. The present study describes the clinical features of cases of PFR presenting to Ophthalmology OPD of SDM College of Medical Sciences and Hospital, Dharwad, which is a tertiary care referral centre in North Karnataka. The present study also describes the visual outcomes after treatment with oral corticosteroids.

MATERIALS AND METHODS

This retrospective observational study was conducted in the OPD of Ophthalmology at SDM College of Medical Sciences and

Hospital, Dharwad, Karnataka, India. The duration of the study was 35 months, from January 2019 to December 2021. The Institutional Ethics Committee clearance was obtained and the study adhered to the tenets of declaration of Helsinki (letter no: ECR/950/Inst/KA/2017/RR-21) and informed consent was obtained from the patients prior to the study.

Inclusion criteria: All the patients diagnosed clinically with retinitis with a history of fever in the preceding four weeks during the study period were included in the study.

Exclusion criteria: Patients with specific retinitis entities such as, toxoplasma retinitis and Cytomegalovirus retinitis which require specific therapy were excluded in the study.

Study Procedure

Data collected included patients demographic details including name, age, sex, hospital identification number, duration of vision loss, detailed ophthalmic examination findings including visual acuity testing with Snellen's chart, slit lamp examination findings and fundus examination findings including detailed fundus drawings, OCT and fundus photographs. Basic investigations included complete haemogram, erythrocyte sedimentation rate, blood pressure, random blood sugar levels, Human Immunodeficiency Virus (HIV) Enzyme-linked Immunosorbent Assay (ELISA), Hepatitis B Surface Antigen (HBsAg), mantoux test, and chest X-ray. Other investigations were carried out as necessary like widal test, chikungunya IgG/IgM, dengue IgG/IgM, malaria parasite and Weil-Felix test. History of

exposure to pets including any scratches/bites by cats was elicited. All the patients were treated with oral prednisolone (tablet omnacortil, macleods pharmaceuticals Ltd.,) 1 mg/kg body weight which was tapered over a period of 6-8 weeks. The ocular examination findings at follow-up visits at one week and six weeks were noted down and the visual acuity at six weeks follow-up was considered for measuring final visual outcomes. The visual impairment was classified as mild (VA of 6/12 to 6/18), moderate (VA of 6/18 to 6/60), severe (VA 6/60 to 3/60) and blindness-(VA <3/60) as per WHO classification [3]. Improvement in VA and reduction in size of retinitis lesions were considered as signs of improvement.

STATISTICAL ANALYSIS

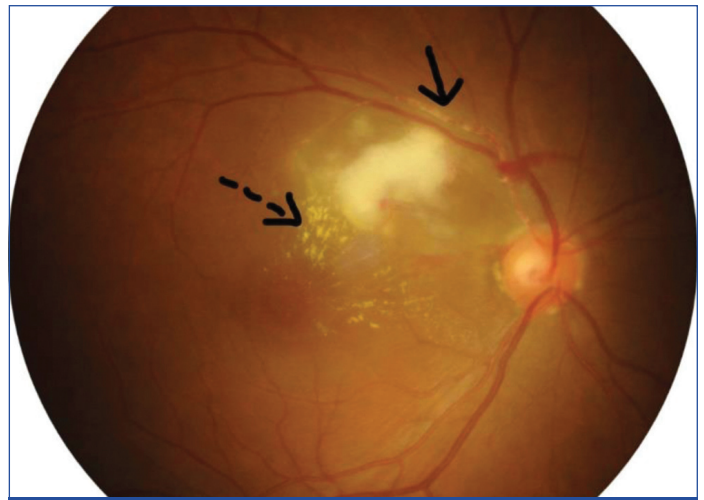The data collected were entered into Microsoft excel spreadsheet. Descriptive statistics were applied to the data. Descriptive statistics of the explanatory and outcome variables were calculated by mean and range. Frequency and proportions for qualitative variables were calculated where applicable.

RESULTS

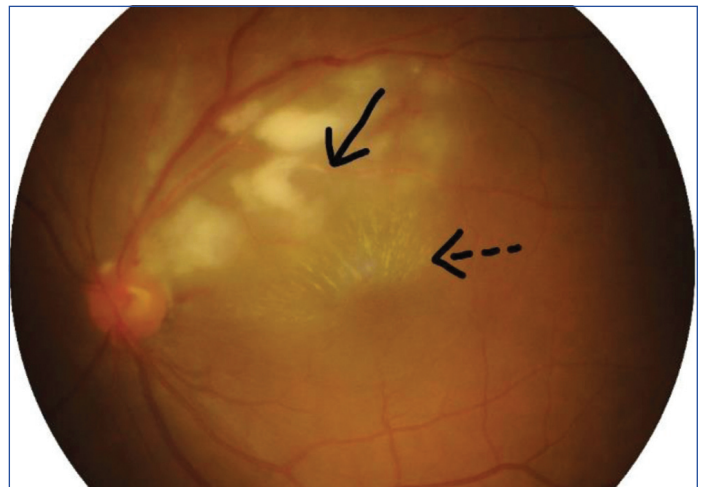During the study period, a total of 27 eyes of 15 patients were examined and diagnosed as PFR. Out of these, two patients with bilateral disease did not come for follow-up after the initial visit and were excluded from the study. A total of 23 eyes of 13 patients were included in the present study. Ten patients had bilateral disease and three had unilateral eye involvement. A total of 13 subjects, 7 (53.8%) were males and 6 (46.1%) were females. Age of the subjects ranged from 15 years to 52 years with an average of 29.6 years. All the patients presented with diminution of vision in the affected eye. All had a history of fever in the preceding four weeks. The duration between onset of fever and vision impairment ranged from two days to four weeks, with an average of two weeks. None were febrile at the time of presentation to ophthalmic OPD. None of the patients were on any oral medications for the febrile episode at the time of diagnosis of PFR.

At the time of presentation, 2 (8.6%) eyes had visual acuity better than 6/12 on Snellen's chart, 5 (21.7%) had mild vision impairment, 5 (21.7%) had moderate vision impairment and 11 (47.8%) had vision <3/60 [3]. Low grade anterior chamber reaction of 1+ was present in four eyes. Relative afferent pupillary defect was present in two eyes of two patients. On fundus examination, vitritis was present in nine eyes. None had dense vitritis preventing retinal examination. Retinal examination showed yellow-white cotton wool spot like retinal lesions with fuzzy borders suggestive of retinitis, either focal or multifocal, in all the eyes. The lesions were noted in the posterior pole and around the arcade vessels. None of the eyes showed lesions in the periphery of the retina. Other retinal findings included disc hyperaemia (four eyes), disc oedema (two eyes), macular oedema (12 eyes), macular star/fan (3 eyes), retinal vascular sheathing (4 eyes), retinal haemorrhages (14 eyes) and involvement of foveal area by the retinitis patch (5 eyes). Macular oedema was one of the most common finding seen in 12 (52.17%) eyes. The lesions were noted to be predominantly in the posterior pole. [Table/Fig-1a,b] shows fundus photographs of a patient with bilateral retinitis lesions in the posterior pole.

A total of 13 patients, underlying aetiology could be determined in only 5 (38.46%) patients. Two had a positive Weil-Felix test at the time of fever episode, one had a positive Widal test and two patients were positive for IgM chikungunya virus. Two patients had been suspected to have rickettsial infection at the time of the febrile episode but were Weil-Felix test negative, and had been treated with oral doxycycline (tab DOXT-SL, Dr. Reddy's Laboratories Ltd.,) for two weeks by the physician. Immune Fluorescence Assay

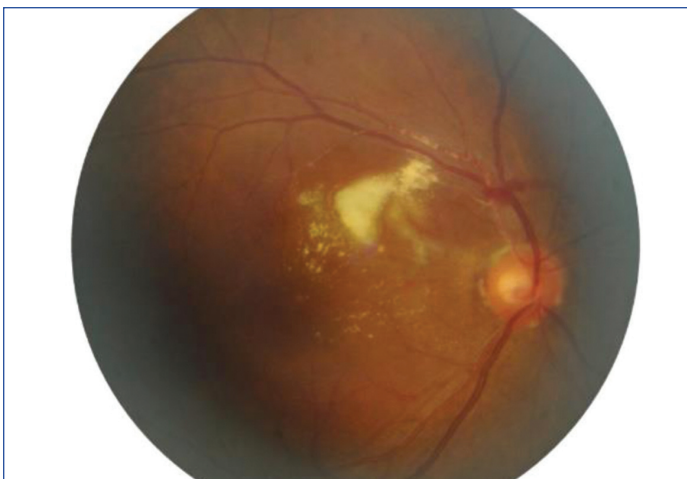

[Table/Fig-1a]: Fundus photograph of right eye of a patient showing active retinitis. Black arrow shows vascular exudation. Broken arrow showing macular fan.

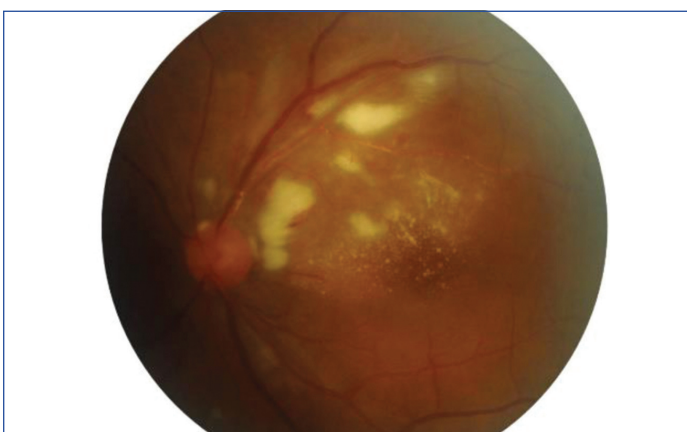


[Table/Fig-1b]: Fundus photograph of left eye showing active multifocal retinitis in the posterior pole. Black arrow shows vascular exudation. Broken arrow showing macular fan.

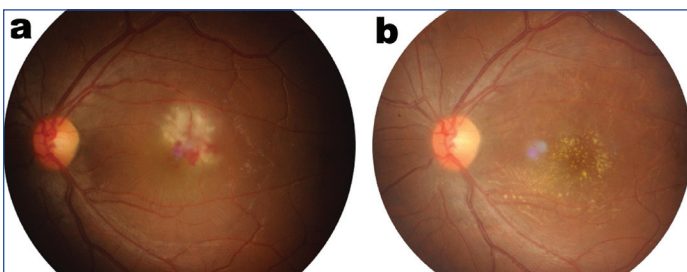
(IFA) was not done in all suspected rickettsia patients due to non availability. All the patients were Coronavirus Disease-2019 (COVID-19) Real Time-Polymerase Chain Reaction (RT-PCR) negative at the time of diagnosis of retinitis. Rest of the subjects did not test positive for any of the tests conducted. None of the patients had exposure to pets or history of cat bite/scratch. Erythrocyte Sedimentation Rate (ESR) ranged from 4 mm/hr to 80 mm/hr with an average 31.4 mm/hr. All the patients were treated with oral prednisolone (tablet omnacortil, macleods Pharmaceuticals Ltd.,) 1 mg/kg body weight which was tapered over a period of 6-8 weeks. A physician clearance was taken for all patients before starting on oral corticosteroids. Four patients received additional oral doxycycline 100 mg twice a day for four weeks. Doxycycline was added for patients with proven or suspected rickettsial infection. The patient who had a positive Widal test was already treated with oral ciprofloxacin 500 mg twice a day for two weeks by the physician. All the patients showed beginning of resolution of retinitis by 2-3 weeks after starting oral corticosteroids. [Table/Fig-1c,d] shows the beginning of resolution in a patient with bilateral involvement. [Table/Fig-2a,b] shows the fundus photograph of left eye of a patient with unilateral retinitis before and after initiation of treatment. Out of the 23 eyes, 8 (34.7%) eyes recovered vision >6/12 with 6 (26.08%) eyes having 6/6 vision. Three eyes had mild vision impairment with VA of 6/12 to 6/18, 7 (30.4%) eyes had moderate vision impairment of 6/18 to 6/60 and three eyes had severe visual impairment of 6/60 to 3/60. 2 (8.6%) eyes had vision worse than 3/60. Comparison of visual acuity at the time of presentation and at six weeks is shown in [Table/Fig-3].



[Table/Fig-1c]: Fundus photograph of right eye of patient (shown in [Table/Fig-1a]) after initiation of oral corticosteroid therapy.



[Table/Fig-1d]: Fundus photograph of left eye of patient (shown in [Table/Fig-1b]) after initiation of oral corticosteroid therapy.



[Table/Fig-2a,b]: Fundus photographs of a study subject with unilateral PFR at the time of presentation and six weeks after initiation of steroid therapy showing resolution of retinitis lesions which is replaced by retinal pigment epithelial changes and resolving hard exudates. The visual acuity at presentation was 6/36 which improved to 6/18 at six weeks.

Level of visual acuity/impairment (Snellen's chart)	n (%)	n (%)
>6/12	2 (8.6)	8 (34.7)
6/12 to 6/18	5 (21.7)	3 (13.04)
6/18 to 6/60	5 (21.7)	7 (30.4)
6/60 to 3/60	--	3 (13.04)
<3/60	11 (47.8)	2 (8.6)

[Table/Fig-3]: Visual acuity at the time of presentation and at six weeks after treatment. n=number of eyes at the time of presentation

DISCUSSION

The PFR has been reported from different regions. A detailed ocular examination of patients presenting with visual disturbance after an episode of fever helps in identifying these cases. In the present study, 10 patients with bilateral disease and three with unilateral involvement have been described. PFR can present with either unilateral or bilateral involvement. The average age of the study participants was 29.6 years with a age range of 15 years to 52 years. Other studies have also described incidence of PFR in

young and middle-aged patients [4,5]. Thus, PFR is seen more in younger adults when compared to the elderly subjects, probably due to a stronger immune system in the younger population. The average duration between fever and onset of defective vision was two weeks in the present study. None of the patients were febrile at the time of ocular examination. The delay in ocular findings and absence of fever favour an immunological mechanism for development of PFR. Another author has also hypothesised a similar theory [6]. All the patients in the present study, presented with defective vision and showed multifocal areas of retinitis.

Macular oedema, seen in 52% of the cases, was the most common finding in the present study. Sundar DM et al., have reported clinical features, OCT findings and treatment outcomes in 19 eyes of 13 patients with PFR and found 69% patients had macular oedema [4]. They reported complete or incomplete macular star, seen in 95% of their cases as the most common finding in association with retinitis. In the present study, authors noted macular star or fan in 3 eyes (13%) of the subjects. The retinitis lesions were predominantly in the posterior pole with involvement of foveal area in five eyes. None of the study participants had involvement of retinal periphery by the retinitis lesions. Shenoy P et al., have reported a similar posterior pole and peripapillary involvement in their case study [7]. Khochtali S et al., in a retrospective study of PFR, reported involvement of retinal periphery in 75% of their cases with acute multifocal retinitis [8]. They also observed the exudative retinal detachment in 10% of their subjects. Vascular sheathing was noted in four eyes in the present study. Sheathing occurs due to an inflammation of the retinal vessels, and may cause minor or major vein occlusions in the retina. Vascular occlusions and immune complex mediated occlusive vasculopathy has been reported in cases with dengue retinitis [9]. Other features of dengue retinitis are foveolitis, macular oedema and disc hyperaemia [10].

In the present study, four eyes had disc hyperemia of which two had associated disc oedema. The study participants were negative for dengue serology. West Nile Virus (WNV) infection can cause disc oedema and neuroretinitis [11]. However, the typical linear pattern of chorioretinitis patches described in WNV retinitis was not seen in any of the study patients. Underlying aetiology could be determined in only four patients. Confirmatory test of Immunofluorescence Assay (IFA) for rickettsia infection could not be performed due to lack of availability. Patients with chikungunya infection, can present with retinitis, neuroretinitis and optic neuritis [12]. The patients who tested positive for IgM chikungunya, were afebrile at the time of presentation to us and had only ocular signs of multifocal retinitis. Recurrent chikungunya retinitis has been reported after steroid taper by Salceanu SO and Raman V [13]. In the present study, such recurrence was unnoticed. All the patients tested COVID-19 RT-PCR negative at the time of diagnosis of PFR. Mahendradas P et al., have reported a case of bilateral PFR with vascular occlusions presenting three weeks after the febrile illness due to Severe Acute Respiratory Syndrome (SARS)-CoV-19 infection [14]. The retinitis in their case improved with oral steroids, doxycycline and anticoagulants. All the patients in the present study had received oral prednisolone 1 mg/kg body weight, which was tapered over 6-8 weeks depending on the response. All the patients showed signs of improvement with oral corticosteroids with 34.7% showing significant visual improvement. Other studies have reported similar improvement on treatment with corticosteroids in cases of PFR [1,15]. High dose methyl prednisolone has also been considered for treatment [16]. Shenoy P et al., reported the findings in a large cohort of patients with PFR and their response to steroids [7]. They found nearly two-third patients improved within four weeks of starting oral steroids. In their study, they did not observe any additional benefits of intravenous steroids. Vishwanath S et al., also have reported resolution of retinitis in all cases following treatment with oral steroids [1]. Kawali A et al., compared the treatment outcomes in epidemic retinitis treated with or without steroids and

found that, epidemic retinitis with macular oedema could be well managed without corticosteroids [17].

Chawla R et al., have reported a case of rickettsial retinitis which worsened with initial monotherapy with steroids and showed improvement after the initiation of oral doxycycline [18]. Other authors also have advocated the use of oral doxycycline and intravitreal injection of bevacizumab for treatment of these cases [4]. Without any other proven treatment modalities available for specific treatment of PFR, corticosteroids remain the therapy of choice. In the present study, 2 eyes (8.6%) had poor vision at the end of six weeks. These were the cases with involvement of the foveal area by the retinitis lesion. These also had poor visual acuity at the time of presentation. Shenoy P et al., found larger size of the lesion, presence of haemorrhages and disc involvement to be associated with late response to treatment [7]. Biswal S et al., reported the predictors of visual outcome in post fever retinitis. They found increase in central macular thickness, subretinal fluid height, presence of Disorganisation of Retinal Inner Layers (DRIL), subfoveal deposits and ellipsoid zone loss to be negatively correlated with final visual acuity [19].

In the present study, patients showed improvement in retinitis with oral corticosteroids irrespective of the underlying aetiology. Patients with suspected or proven rickettsial infection needed additional treatment with oral doxycycline. Visual outcomes depended on the involvement of foveal area by the retinitis lesions.

Limitation(s)

Limitations of the present study were its retrospective nature, possibility of recall bias regarding details during fever episode, lack of long term follow-up and non availability of OCT images and fundus fluorescein angiograms in all patients. Well-designed prospective studies with inclusion of large number of patients will help overcome the existing limitations. A thorough systemic work-up can shed more light on the underlying aetiology in these cases. Fundus fluorescein angiogram can be helpful to know the macular perfusion and help to prognosticate the visual outcomes in these patients.

CONCLUSION(S)

The PFR is predominantly seen in young population in the Northern Karnataka region. Underlying aetiology may not be confirmed in all the cases. Patients with visual loss may have unilateral or bilateral involvement by focal or multifocal retinitis with macular oedema being a common finding. Oral corticosteroid therapy is associated with improvement and resolution of retinitis. Foveal involvement is associated with poor visual outcomes. It is therefore, necessary to watch out for visual impairment in cases with bacterial or viral febrile episode. Therapy with oral corticosteroids is beneficial in visual recovery.

Acknowledgement

The authors would like to thank for the academic support and encouragement provided by Dr. Anupama Desai, Professor and Head of the Department and Dr. Shankargouda Patil, Professor, Department of Ophthalmology, SDM College of Medical Sciences and Hospital, Shri Dharmasthala Manjunatheshwara University, Dharwad, Karnataka, India.

REFERENCES

- [1] Vishwanath S, Badami K, Sriprakash KS, Sujatha BL, Shashidhar SD, Shilpa YD. Post fever retinitis: A single center experience from South India. *Int Ophthalmol*. 2014;34:851-57.
- [2] Mahendradas P, Kawali A, Luthra S, Srinivasan S, Curi Andre L, Maheswari S, et al. Post fever retinitis-newer concepts. *Indian J Ophthalmol*. 2020;68:1775-86.
- [3] Blindness and visual impairment. World Health Organisation. Fact sheets. 14 October 2021. Available from: <https://www.who.int/news-room/fact-sheets/detail/blindness-and-visual-impairment>. Last accessed on 26/12/2022.
- [4] Sundar MD, Chawla R, Balaji A, Garg I, Kalathil R, Hasan N, et al. Clinical features, optical coherence tomography findings and treatment outcomes of post fever retinitis. *Ther Adv Ophthalmol*. 2020;12:01-10.
- [5] Kawali A, Mahendradas P, Mohan A, Mallavarapu M, Shetty B. Epidemic retinitis. *Ocul Immunol Inflamm*. 2019;27:571-77.
- [6] Panchsal B. Commentary: Post fever retinitis and vasculitis: A morphological conundrum. *Indian J Ophthalmol*. 2018;66(12):1844.
- [7] Shenoy P, Kohli GM, Kerkatta A, Pathak P, Shetty S, Barde P, et al. Clinical profile and response to steroids in post fever retinitis: A nine year experience from a referral institute in the rural hinterland of Central India. *Int Ophthalmol*. 2021;41(12):4055-63.
- [8] Khohtali S, Gargouri S, Zina S, Ksaa I, Abroug N, Zaouali S, et al. Acute multifocal retinitis: A retrospective review of 35 cases. *J Ophthal Inflamm Infect*. 2018;8:18.
- [9] Bacsal KE, Chee S, Cheng C, Flores JVP. Dengue-associated maculopathy. *Arch Ophthalmol*. 2007;125:501-10.
- [10] Agarwal A, Aggarwal K, Dogre M, Kumar A, Akella M, Katoch D, et al. Dengue induced inflammatory, ischemic foveolitis and outer maculopathy: A swept source imaging evaluation. *Ophthalmol Retina*. 2019;3:170-77.
- [11] Sivakumar RR, Prajna L, Arya LK, Muraly P, Shukla J, Saxena D. Molecular diagnosis and ocular imaging of West Nile virus retinitis and neuroretinitis. *Ophthalmology*. 2013;120:1820-26.
- [12] Mahesh G, Giridhar A, Shedbele A, Kumar R, Saikumar SJ. A case of bilateral presumed chikungunya neuroretinitis. *Indian J Ophthalmol*. 2009;57:148-50.
- [13] Salceanu SO, Raman V. Recurrent chikungunya retinitis. *BMJ Case Rep*. 2018;2018:bcr2017222864.
- [14] Mahendradas P, Hande P, Patil A, Kawali A, Sanjay S, Ahmed SA, et al. Bilateral post fever retinitis with retinal vascular occlusions following severe acute respiratory syndrome corona virus (SARS-CoV2) infection. *Ocul Immunol Inflamm*. 2022;30(7-8):1715-20.
- [15] Prabhushanker M, Topiwalla TT, Ganesan G, Appandaraj S. Bilateral retinitis following typhoid fever. *Int J Retina Vitreous*. 2017;3:11.
- [16] Karkhur S, Soni D. Clinical spectrum, disease course and management outcome of post fever retinitis cases: Experience from a tertiary eye institute in Central India. *Int Ophthalmol*. 2022;42(9):2697-709.
- [17] Kawali A, Srinivasan S, Mohan A, Bavaharan B, Mahendradas P, Shetty B. Epidemic retinitis with macular edema-treatment outcome with and without steroids. *Ocul Immunol Inflamm*. 2021;29(5):932-36.
- [18] Chawla R, Pundalik GA, Chaudhry R, Thakur C. Rickettsial retinitis: Direct bacterial infection or an immune mediated response? *Indian J Ophthalmol*. 2017;65(10):1038-41.
- [19] Biswal S, Gondchawar A, Ravishankar HN, Sagar P, Shanmugam PM, Shah A, et al. Predictors of visual outcome in post fever retinitis: a retrospective analysis. *Int Ophthalmol*. 2021;41(12):4099-109.

PARTICULARS OF CONTRIBUTORS:

1. Junior Resident, Department of Ophthalmology, SDM College of Medical Sciences and Hospital, Shri Dharmasthala Manjunatheshwara University, Dharwad, Karnataka, India.
2. Assistant Professor, Department of Ophthalmology, SDM College of Medical Sciences and Hospital, Shri Dharmasthala Manjunatheshwara University, Dharwad, Karnataka, India.
3. Associate Professor, Department of Ophthalmology, SDM College of Medical Sciences and Hospital, Shri Dharmasthala Manjunatheshwara University, Dharwad, Karnataka, India.

NAME, ADDRESS, E-MAIL ID OF THE CORRESPONDING AUTHOR:

Dr. Vishalakshi,
Assistant Professor, Department of Ophthalmology, SDM College of Medical Sciences and Hospital, Shri Dharmasthala Manjunatheshwara University,
Dharwad-580009, Karnataka, India.
E-mail: drvishalakshi@gmail.com

AUTHOR DECLARATION:

- Financial or Other Competing Interests: None
- Was Ethics Committee Approval obtained for this study? Yes
- Was informed consent obtained from the subjects involved in the study? Yes
- For any images presented appropriate consent has been obtained from the subjects. Yes

PLAGIARISM CHECKING METHODS: [Jan H et al.]

- Plagiarism X-checker: Sep 10, 2022
- Manual Googling: Dec 20, 2022
- iThenticate Software: Jan 18, 2023 (10%)

ETYMOLOGY: Author Origin

EMENDATIONS: 6

Date of Submission: Sep 08, 2022

Date of Peer Review: Nov 19, 2022

Date of Acceptance: Jan 24, 2023

Date of Publishing: Jun 01, 2023