

Isocitrate Dehydrogenase (IDH1) and p53 Mutations in Gliomas: A Cross-sectional Study from a Tertiary Care Hospital, Karnataka, India

NISSY J LOUIS¹, SAPNA PATEL², HARISH SRIKANTEGOWDA³

ABSTRACT

Introduction: Gliomas, being the most common Central Nervous System (CNS) neoplasms, are broadly divided into astrocytomas, oligodendrogliomas and ependymomas. World Health Organisation (WHO) 2016 criteria incorporated Immunohistochemistry (IHC), molecular diagnostic techniques and histological tumour grading into its diagnostic criteria. Isocitrate Dehydrogenase (IDH1) mutations are commonly seen in young people with good prognostic implications. The detection of Tumour Protein53 (p53) mutations in gliomas and its association with the grade of the tumour can be used as a diagnostic, prognostic and therapeutic tool for better survival in affected individuals. IHC can be used as surrogate markers in detecting the mutational status of IDH1 and p53.

Aim: To study the expression of IDH1 and p53 mutations in gliomas and to evaluate its association with known clinicopathological variables.

Materials and Methods: This cross-sectional, retrospective, analytical study was conducted in the Department of Pathology at JSSAHER, Mysuru, Karnataka, India, from October 2018 to September 2022. All histopathologically diagnosed glioma cases, who underwent surgery, were appropriately reviewed and graded. IHC was performed for the detection of IDH1 mutational status and p53 expression. The tumour was labelled as, IDH1 positive with cytoplasmic staining and p53 positive

when nuclear staining was observed in more than 5% of tumour cells. The p53 expression was further quantified in scores as low ≤ 8 and high > 8 score. The associations of clinicopathological variables and the comparison of the scores of p53 mutation across various categories of gliomas were analysed statistically. The data was analysed using Statistical Package for Social Sciences (SPSS) version 26.0.

Results: The mean age of the study participants was 42.6 years with the standard deviation of 12.8 years. A total of 35 cases (20 males and 15 females) were analysed. The maximum number of cases was in the age group of 31-40 years (n=13) followed by 41-50 years of age group (n=11). Three of them were seen in age less than 20 years. The male: female ratio was 1.33:1. Out of total cases, 20 cases showed IDH1 positivity, 11 cases showed high p53 expression and five cases demonstrated both IDH1 positivity and high expression of p53. A statistically significant association (p-value=0.014) was seen between the grade of the tumour and p53 immunoreaction.

Conclusion: The present study of the detection of IDH1 and p53 mutations, could provide reliable information for improved tailoring of patient therapy as study revealed that, there was a significant association of p53 expression with the grade of the tumour with low expression in low grade gliomas and high p53 expression in high grade gliomas.

Keywords: Astrocytomas, Ependymomas, Oligodendrogliomas, Prognosis, Tumour protein53

INTRODUCTION

Gliomas are the commonest primary intracranial CNS neoplasms. These tumours have features, that are histologically similar to the normal glial cells and are grouped into astrocytomas, oligodendrogliomas and ependymomas, and each of these types has a wide spectrum of aggressiveness [1]. The WHO grades 1 and 2 tumours were once referred to as "low grade gliomas," while the more aggressive and rapidly growing tumours were referred to as "high grade gliomas." These terminologies are no longer used as per the recommendation given by WHO, because these lesions refer to a heterogeneous group of neoplasms with vastly differing prognosis and treatments due to their diverse biological characteristics [1].

The WHO's categorisation of gliomas was first released in 1979 and since, 2016 edition of the WHO classification [2], gliomas have been categorised according to histology and molecular characteristics [1]. It is envisaged that, this categorisation would result in more biologically homogenous defined diagnostic entities, which will improve patient care, determine therapy response and prognosis more precisely, and increase diagnostic accuracy [2].

The classification of oligodendroglial and astrocytic tumours also changed with the addition of molecular parameters [3]. They are classified based on their growth patterns, IDH1 genetic status and ATRX (Alpha-thalassemia/mental retardation, X-linked) immunoreaction [4]. Along with those mentioned in the "Consortium to Inform Molecular and Practical Techniques to CNS Tumour Taxonomy- Not Official WHO (cIMPACT-NOW)" updates one through seven, more molecular approaches have been integrated into the 5th (2021) edition [5]. IDH1-mutant tumours are associated with a considerably better prognosis than IDH1-wildtype tumours [6]. Studies also showed that, "mutant type p53" has a better prognosis and responds well to chemotherapy and radiotherapy when compared to "wild type p53". Moreover, "p53 positive tumours" are said to have a long survival when compared to "p53 negative tumours" [7] and are also essential in predicting the clinical course of the disease. Assessment of the expression of p53 and IDH1 can be helpful in further stratification of the patients for the specific treatment plan.

The study uses IHC and demonstrates glioma cases into either IDH1 mutant and IDH1 wild-type cases. Additionally, p53 expression and IDH1 mutational status is also associated with various clinical

parameters like age of the patient in the present study. IDH mutation and p53 expression are said to have a better prognosis [6,7] and hence, can be beneficial in monitoring immunotherapy.

The aim of the present study was to study the expression of IDH1 and p53 mutations in gliomas and to evaluate association of IDH1 and p53 expressions with known clinicopathological variables.

MATERIALS AND METHODS

This cross-sectional, retrospective analytical study was conducted in the Department of Pathology at JSSAHER, Mysuru, Karnataka, India. The duration of the study was 48 months (which is four years), from October 2018 to September 2022. A total of 35 glioma cases were included using a convenient sampling technique. Permission to conduct the study was obtained from the Institutional Ethical Committee (JSS/MC/PG/5156/2020-21).

Inclusion criteria: All histopathologically diagnosed cases of gliomas were included in the study.

Exclusion criteria: Patients with no available pathology material for IDH1 and p53 immunostain were excluded from the study.

Study Procedure

All the cases were appropriately evaluated and categorised based on their histological characteristics. Tissues from surgically excised brain tumours were embedded in paraffin and stained with Haematoxylin and Eosin (H&E) after being fixed in 10% neutral buffered formalin. For the retrospective cases (which were from October 2018 to September 2020), the clinical and histopathological data were retrieved from the hospital information system and 3-4 μ m thick sections were obtained from representative paraffin blocks and studied. For prospective cases (which were from October 2020 to September 2022), routine processing was done and studied. IHC was performed on 3 μ m thick sections that were air-dried and coated with Polylysine. The slides were baked at 60°C for an hour in a hot air oven and then deparaffinised followed by rehydration. The slides were heated in a pressure cooker with antigen retrieval solution and sodium citrate buffer at pH 6. Mouse monoclonal antibody brain tumour marker, clone H09 anti-IDH1 R132H/DIA-H09-L Ready To Use (RTU) was used for detection of the presence of IDH1 mutation. Antibody clone H09 reacts specifically with the IDH1R132H point mutation in tissue sections from formalin-fixed brain tumour specimens. The tumour was categorised as IDH1 positive with cytoplasmic staining [8]. No scoring or grading systems were used in the present study to further subcategorise the IDH1 positive cases. Sections from brain tumour diagnosed as diffuse astrocytoma was used as positive control and sections treated with phosphate buffer saline, rather than the primary antibody were used as negative control.

Monoclonal antibody p53 (Novacastra, Mouse Monoclonal Antibody; P53-DO7-R-7-CE, RE7290-CE) was used for p53 antigen detection. Diaminobenzidine (DAB) chromogen substrate, which was prepared by mixing 50 μ l of DAB chromogen with 1 mL of DAB buffer, was used to detect the bound antibody. If $\geq 5\%$ of the cells in 10 High Power Fields (HPF) showed nuclear staining, the tumour was considered to be p53 positive [9]. Based on the percentage of tumour cells, that showed positivity for p53, they were placed into one of the six categories-if the percentage of the total number of tumour cells is less than 5%, then it is scored as zero and when, the percentage of tumour cells is between 5%-30%, 31%-50%, 51%-70%, 71%-90% and greater than 90%, then the score given was 1,2,3,4 and 5, respectively [9]. Secondly, the tumour cells were scored based on p53 staining intensity as weak, moderate and intense expression with a score of 1+, 2+ and 3+, respectively [9]. The results of p53 IHC were quantified as scores and the weighted score for each tumour was calculated by multiplying the percentage and staining intensity scores, with a score of ≤ 8 assigned as low

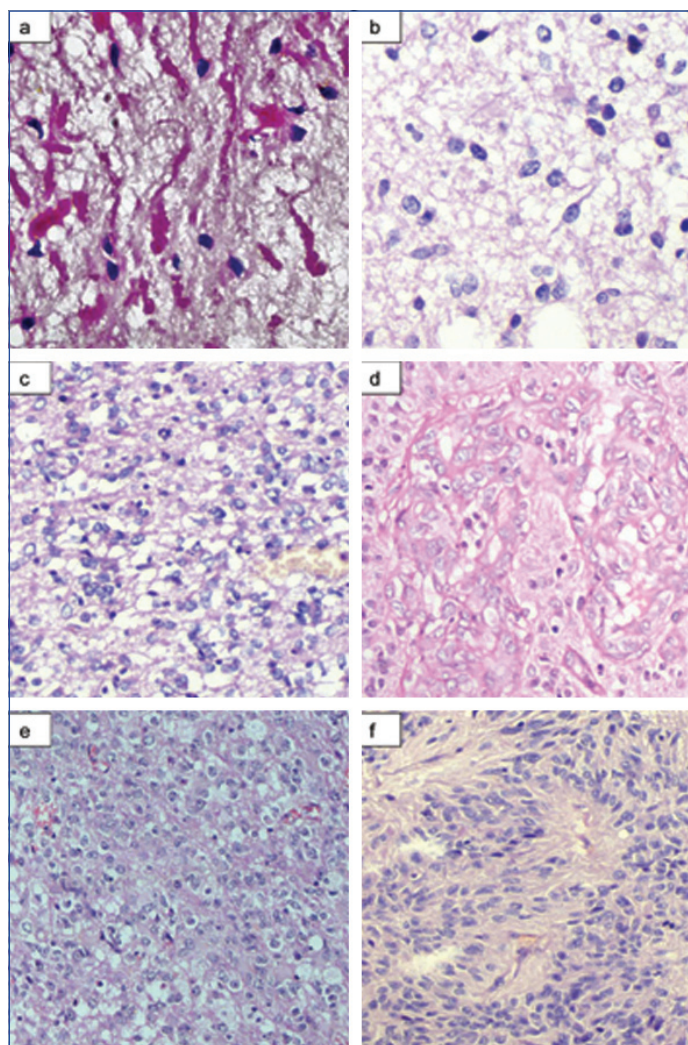
expression and >8 assigned as high expression [9]. Section from colon cancer was used as a positive control, whereas, phosphate buffer saline was applied to sections as a negative control in place of the primary antibody.

STATISTICAL ANALYSIS

The data was analysed using SPSS version 26.0. Descriptive statistics like proportions and inferential statistics like Pearson's Chi-square test were used as appropriate to evaluate the association of IDH1 and p53 expressions with known clinicopathological variables. Kruskal-Wallis test was used to compare the scores of p53 mutation among various categories of gliomas. The p-value ≤ 0.05 was considered statistically significant. Graphs were created using Microsoft excel 2019.

RESULTS

The present study included 23 retrospective and 12 prospective cases and comprised 30 cases of astrocytomas [Table/Fig-1a-d], two cases of oligodendrogliomas [Table/Fig-1e] and three cases of ependymomas [Table/Fig-1f] which were diagnosed histopathologically (histopathological grading for these gliomas has been provided in [Table/Fig-2]). There was a wide age range with gliomas being reported between the age groups of 14 and 67 years the mean age is 42.6 years. The maximum number of



[Table/Fig-1]: Photomicrographs of gliomas belonging to different grades: a) Pilocytic astrocytoma (biphasic appearance showing compact cellular portion with Rosenthal fibres in a microcystic background) (H&E, x400); b) Grade 2 astrocytoma (tumour cells showing round to oval nuclei in a fibrillary background) (H&E,x400); c) Grade 3 astrocytoma (increased cellularity displaying pleomorphic cells with mitoses) (H&E,x200); d) Glioblastoma (tumour cells are seen having round to oval, vesicular nuclei with moderate eosinophilic cytoplasm. Microvascular proliferation seen as glomeruloid appearance) (H&E, x400); e) Grade 3 oligodendroglioma (tumour cells have round monotonous nuclei with a perinuclear halo and occasional mitoses) (H&E, x200); f) Grade 2 ependymoma (true ependymal rosettes are noted with central fibrillar areas) (H&E, x200).

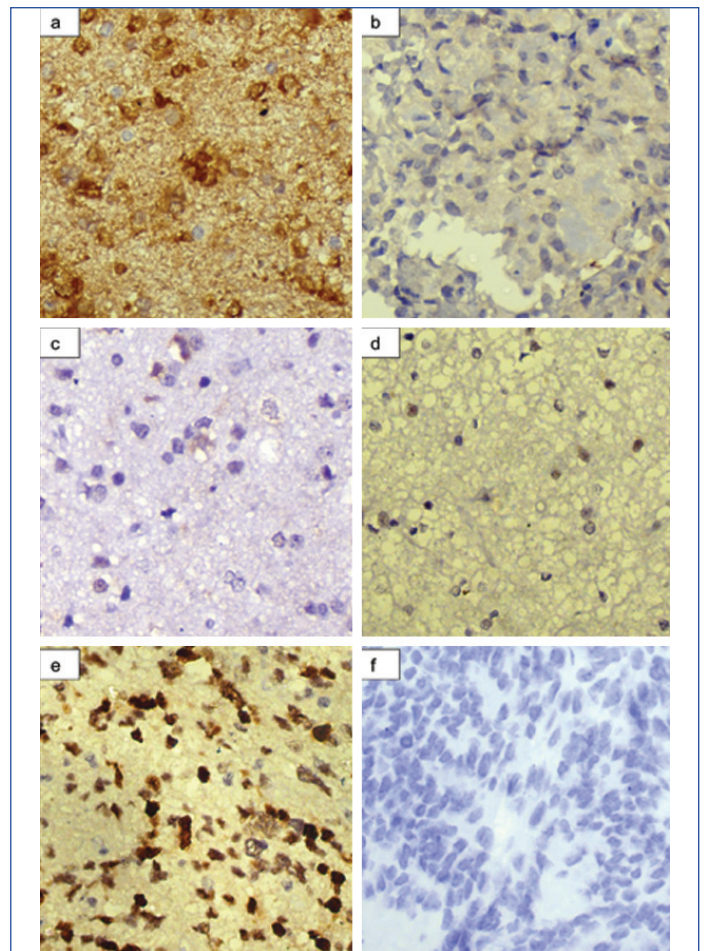
cases was in the age group of 31-40 years (n=13) followed by 41-50 years of age group (n=11). Three of them was seen in age less than 20 years. The male: female ratio was 1.33:1 (20 males and 15 females). Majority of the cases belonged to grade 4 {number of cases (n), n=14} gliomas followed by grade 2 (n=12). Among 35 cases of gliomas studied, 20 of them showed IDH1 positivity [Table/Fig-3a]. Pilocytic astrocytomas and ependymomas showed IDH1 negative immunoreaction [Table/Fig-3b] irrespective of the age and the grade of the tumour and oligodendrogliomas showed low expression of p53 [Table/Fig-3c-f].

S. No.	Age (in years)	WHO grade	IDH1	p53 expression
1.	32	4	Negative	Positive - high
2.	34	2	Positive	Positive - low
3.	18	3	Negative	Positive - low
4.	61	2	Positive	Positive - low
5.	40	4	Negative	Positive - high
6.	40	2	Positive	Positive - low
7.	48	2	Positive	Negative
8.	42	1	Negative	Positive - low
9.	56	4	Positive	Positive - high
10.	14	1	Negative	Negative
11.	35	4	Positive	Positive - high
12.	35	3	Positive	Positive - low
13.	45	3	Positive	Positive - low
14.	45	2	Positive	Positive - low
15.	58	4	Negative	Positive - low
16.	32	4	Positive	Positive - high
17.	33	3	Negative	Positive - high
18.	38	2	Positive	Positive - low
19.	42	2	Positive	Positive - low
20.	48	4	Positive	Positive - high
21.	45	2	Negative	Positive - high
22.	45	3	Negative	Positive - low
23.	45	4	Negative	Positive - high
24.	49	4	Negative	Positive - high
25.	55	3	Positive	Positive - low
26.	40	2	Positive	Positive - low
27.	36	3	Positive	Positive - low
28.	48	2	Negative	Positive - low
29.	36	2	Negative	Negative
30.	14	4	Positive	Positive - low
31.	58	4	Positive	Positive - low
32.	58	2	Negative	Positive - low
33.	65	4	Positive	Negative
34.	67	4	Negative	Negative
35.	37	4	Positive	Positive - high

[Table/Fig-2]: Immunostaining analysis of IDH1 and p53 of all cases.

The p-value in all the associations of IDH1 with the clinicopathological parameters was greater than 0.05 and the p-value between the IDH1 mutation and age (p=0.697) [Table/Fig-4], grade of the tumour (p=0.375) [Table/Fig-5] or p53 expression of the tumour (p=0.333) was not significant.

A total of 5 (14.3%) out of 35 cases in the current study, tested negative for p53, whereas, 19 (54.3%) displayed low expression and 11 (31.4%) displayed high expression for p53 immunostain [Table/Fig-2]. The maximum number of glioma cases with low expressions of p53 was seen in grade 2 tumours which constituted 9 (25.7%) cases [Table/Fig-2]. Maximum number of high p53 positivity was seen in grade 4 gliomas which constituted 9 (25.7%)



[Table/Fig-3]: Immunostaining of IDH1 and p53: IDH1 - a) Cytoplasmic positivity of IDH1 (H&E, x400); b) IDH1 negative immunostaining (H&E, x400); p53 - c) Tumour cells showing 1+ (weak) intensity of p53 staining (H&E, x400); d) Tumour cells showing 2+ (moderate) intensity of p53 staining (H&E, x400); e) Tumour cells showing 3+ (intense) p53 nuclear staining (H&E, x400); f) Negative expression of p53 immunostain in tumour cells (H&E, x400).

Age (in years)		<20	31-40	41-50	51-60	>61	p-value
Total no. of cases (n)	n=35	3	13	11	5	3	
IDH1	Negative	2	4	6	2	1	
	Positive	1	9	5	3	2	0.151
p53	Negative	1	1	1	0	2	
	Low positive (Score ≤8)	2	6	6	4	1	
	High positive (Score >8)	0	6	4	1	0	

[Table/Fig-4]: Association of age with IDH1 and p53 immunoreactivity. Pearson's Chi-square test and Kruskal-Wallis test have been used

		WHO grade				p-value
Total no. of cases (n=35)		1 (n=2)	2 (n=12)	3 (n=7)	4 (n=14)	
Age (in years)	<20	1	0	1	1	0.644
	31-40	0	5	3	5	
	41-50	1	5	2	3	
	51-60	0	1	1	3	
	>60	0	1	0	2	
IDH1	Negative	2	4	3	6	0.375
	Positive	0	8	4	8	
p53	Negative	1	2	0	2	0.014
	Low positive (score ≤8)	1	9	6	3	
	High positive (score >8)	0	1	1	9	

[Table/Fig-5]: Association of grade of gliomas with age, IDH1 and p53 immunostaining. Pearson's Chi-square test and Kruskal-Wallis test have been used

cases [Table/Fig-2]. Less than 5% of the tumour cells (negative p53 expression) were stained for p53 in five cases. The p-value ≤ 0.05 was considered to be statistically significant and in the current study, there was statistical significance between the expression of p53 and the tumour grade ($p=0.014$) [Table/Fig-5], but not between the expression of p53 and age ($p=0.151$) [Table/Fig-4].

DISCUSSION

Gliomas constitute about 80% of all brain malignancies and are further classified into four tumour grades, with grade 1 being the least aggressive and grade 4 being the most aggressive. There are different mutations implicated in the development of gliomas like IDH1, p53, ATRX, Cyclin-dependent Kinase Inhibitor 2B (CDKN2B), and a few other mutations. IDH1 mutation provides a growth advantage to the cells that express it by increasing the level of 2-hydroxyglutarate. The p53 mutation leads to the development of tumours by promoting the uncontrolled growth of cells. The type of therapy is determined by the location, grade of the tumour and the patient's age [10]. Grade 1 and 2 tumours are usually treated with surgery, while grade 3 and 4 tumours are treated with a combination of surgery, radiation, and chemotherapy [10,11].

The present study showed gliomas with a mean age of 42.6 years. Lewandowska MA et al., and Deng L et al., observed a mean age of 36 years and 42.06 years respectively, in their studies [12,13]. Both, the current study (57.1%) and those conducted by Watanabe T et al., and Chen N et al., found that, males predominated [14,15]. In the present study, for all glioma types, males were predominantly affected except in grade 2 gliomas where, females predominated. The study had the highest percentage of grade 4 gliomas (40%) compared to studies by Mellai M et al., [Table/Fig-6] and Rasmussen BK et al., [12-14,16,17].

Different studies (year of publication and place of study)	WHO grade			
	1	2	3	4
Incidence of gliomas:				
Present study	5.7%	34.3%	20%	40%
Deng L et al., [13] (2018, China)	2.9%	32%	29.6%	22.8%
Watanabe T et al., [14] (2009, Switzerland)	9.66%	40.8%	10.9%	29%
Mellai M et al., [16] (2011, Italy)	5.92%	17%	15%	64.8%
IDH1 mutations:				
Present study	0	66.67%	57.14%	57.14%
Lewandowska MA et al., [12] (2013, Poland)	0	56%	94.1%	50%
Deng L et al., [13] (2018, China)	0	66.67%	55.74%	10.63%
Mellai M et al., [16] (2011, Italy)	5.88%	51%	41.9%	9.67%

[Table/Fig-6]: Incidence of gliomas across each tumour grade with IDH1 mutations as seen in different studies [12-14,16].

The IDH1 mutations are more prevalent than IDH2 mutations among the two frequent IDH mutations in gliomas and occur in both astrocytomas, as well as, in oligodendrogliomas. p53 mutations occur in those cells which are already committed to any one of these lineages [18] and further tells us that, IDH1 mutation occurs early in the development of gliomas which is later accompanied by p53 mutation as the tumour progresses. Hartmann C et al., studied 80 anaplastic astrocytoma cases, among which 40 cases (50%) showed IDH1 immunopositivity [19]. The current study showed 75% of grade 3 astrocytomas that demonstrated IDH1 positivity. Capper D et al., in a study showed, 94% of grade 3 oligodendrogliomas positive for IDH1 immunoreaction [20]. The present study demonstrated 57% of grade 3 gliomas with IDH1 immunopositivity.

The study conducted by Lewandowska MA et al., analysed that, longer survival was seen in those patients, who had low expression of IDH1 [12]. As an example, they have considered two cases of grade 2 astrocytoma, one with low expression (1+ or 2+) of IDH1 and the other with high expression (3+ or 4+) of IDH1, the one with low

expression of grade 2 astrocytoma was said to have a longer survival when compared to that of a high expression [12]. Previously, IDH mutation was considered to be the single most prognostic marker in Glioblastoma Multiforme (GBM) [21,22]. Hence, IDH mutations in gliomas are targeted for diagnostic, therapeutic, and prognostic purposes [23]. Mellai M et al., suggested that, IDH1 was said to have a prognostic significance in grade 3 and grade 4 gliomas and had better survival, when compared to those patients, who had gliomas without IDH1 mutations [16]. However, Balss J et al., found that, there was no association between IDH1 and p53 mutation [18]. The present study also demonstrated a similar observation.

p53: In approximately, 50% of all malignancies, the p53 gene is mutated and greater than 65% of gliomas have the p53 protein genetically altered. In 2006, Hu X et al., studied 152 glioma patients [24]. The mean age in that study, was 40.3 years ranging from 21-79 years, had male predominance and p53 expression was seen maximum in grade 3 glioma, which was similar to the present study. The current research, however, demonstrated a significant association ($p\text{-value}=0.014$) between p53 expression and the tumour grade, which was consistent with the 81 case study by Cho MY et al., [25]. The latter study also said that, the frequency of p53 expression was the highest in grade 3 astrocytoma when compared to grade 4. The maximum expression in the present study was seen in grade 3 (which is 100%), followed by grade 4 and then grade 2. Low expression of p53 was seen maximum in grade 2 tumours followed by grade 3 and then grade 4. But, the frequency of gliomas expressing high immunopositivity of p53 was seen highest in grade 4. This result suggested that, p53 targeted therapy could be helpful in these patients if detected in the early stages of disease progression.

Popova SN et al., studied gliomas in 219 cases over a period of 18 years and analysed that, none of the oligodendroglioma cases showed high expression of p53, which was consistent with the present study [26]. A descriptive study done by Arshad H et al., grouped the gliomas into four grades and performed p53 and MIB1 immunohistochemical stains [27]. They concluded that, the histopathological grade was the most important prognostic factor in regard to the survival of the patient and the IHC staining could be clubbed along with the histological grade, as an additional tool in knowing the clinical course of the patient [27]. Another study, conducted at the University of Texas from the tissue samples obtained from 182 patients determined the significance of p53 as a prognostic marker and suggested that, the IHC status of p53 could be an important predictor for patient survival [7].

Limitation(s)

The sample size of the present study was low therefore, more studies using a large number of cases are required to obtain more corroboration. An equal distribution of cases was not obtained among all the tumour grades of gliomas and follow-up of the cases was not possible. Hence, addressing the parameters like the recurrence of the tumour, prognosis and survival studies of the patients was not done. Selection bias cannot be ruled out, as it was a single Institutional study. Ancillary techniques like Fluorescent In-situ Hybridisation (FISH) and molecular detection techniques could not be performed in the present study, considering its unavailability in the Institute where the study was conducted.

CONCLUSION(S)

The hybrid taxonomy of WHO CNS 2021 criteria, include the reporting of gliomas in structured layering and integrated diagnoses using histopathological examination, immunohistochemical assessment and molecular studies in certain entities. The present study revealed that, there was a significant association of p53 expression with the grade of the tumour with low expression in low grade gliomas and high p53 expression in high grade gliomas. Therefore, the present

study emphasises the detection of IDH1 and p53 mutations in gliomas, that may act as an objective tool to supplement subjective methods of evaluation in differentiating low grade gliomas from high grade gliomas.

Acknowledgement

The authors would like to thank the technical staff of the hospital for their skillful assistance in the present study. The authors are also thankful to the Head of the Department for the valuable support throughout the study and also, wish to thank Dr. Suchitha S for her valuable contribution and expertise in all aspects of the present study.

REFERENCES

- [1] Louis DN, Ohgaki H, Wiestler OD, Cavenee WK, Burger PC, Jouvet A, et al. The 2007 WHO classification of tumours of the central nervous system. *Acta Neuropathol.* 2007;114(2):97-109.
- [2] Louis DN, Perry A, Reifenberger G, Von Deimling A, Figarella-Branger D, Cavenee WK, et al. The 2016 World Health Organization classification of tumours of the central nervous system: A summary. *Acta Neuropathol.* 2016;131(6):803-20.
- [3] Louis DN, Giannini C, Capper D, Paulus W, Figarella-Branger D, Lopes MB, et al. cIMPACT-NOW update 2: Diagnostic clarifications for diffuse midline glioma, H3 K27M-mutant and diffuse astrocytoma/anaplastic astrocytoma, IDH-mutant. *Acta Neuropathol.* 2018;135(4):639-42.
- [4] Brat DJ, Aldape K, Colman H, Holland EC, Louis DN, Jenkins RB, et al. cIMPACT-NOW update 3: Recommended diagnostic criteria for "Diffuse astrocytic glioma, IDH-wild type, with molecular features of glioblastoma, WHO grade IV". *Acta Neuropathol.* 2018;136(5):805-10.
- [5] Louis DN, Perry A, Wesseling P, Brat DJ, Cree IA, Figarella-Branger D, et al. The 2021 WHO classification of tumours of the central nervous system: A summary. *Neuro-Oncol.* 2021;23(8):1231-51.
- [6] Brat DJ, Verhaak RG, Aldape KD, Yung WK, Salama SR, Cooper LA, et al. Cancer genome atlas research network. Comprehensive, integrative genomic analysis of diffuse lower-grade gliomas. *N Engl J Med.* 2015;372(26):2481-98.
- [7] Kyrtsis AP, Bondy ML, Hess KR, Cunningham JE, Zhu D, Amos CJ, et al. Prognostic significance of p53 immunoreactivity in patients with glioma. *Clin. Cancer Res.* 1995;1(12):1617-22.
- [8] Arita H, Narita Y, Yoshida A, Hashimoto N, Yoshimine T, Ichimura K. IDH1/2 mutation detection in gliomas. *Brain Tumour Pathol.* 2015;32:79-89.
- [9] Ryu JW, Lee MC, Jang WC. Detecting p53 gene mutation of breast cancer and defining differences between silver staining PCR-SSCP and immunohistochemical staining. *J Korean Med Sci.* 2000;15(1):73-77.
- [10] Diamandis P, Aldape K. World Health Organization 2016 classification of central nervous system tumours. *Neurol. Clin.* 2018;36(3):439-47.
- [11] Mack SC, Singh I, Wang X, Hirsch R, Wu Q, Villagomez R, et al. Chromatin landscapes reveal developmentally encoded transcriptional states that define human glioblastoma. *J Exp Med.* 2019;216(5):1071-90.
- [12] Lewandowska MA, Furtak J, Szyberg T, Roszkowski K, Windorbska W, Rytelwska J, et al. An analysis of the prognostic value of IDH1 (isocitrate dehydrogenase 1) mutation in Polish glioma patients. *Mol Diagn Ther.* 2014;18(1):45-53.
- [13] Deng L, Xiong P, Luo Y, Bu X, Qian S, Zhong W, et al. Association between IDH1/2 mutations and brain glioma grade. *Oncol. Lett.* 2018;16(4):5405-09.
- [14] Watanabe T, Nobusawa S, Kleihues P, Ohgaki H. IDH1 mutations are early events in the development of astrocytomas and oligodendrogliomas. *Am J Surg Pathol.* 2009;174(4):1149-53.
- [15] Chen N, Yu T, Gong J, Nie L, Chen X, Zhang M, et al. IDH1/2 gene hotspot mutations in central nervous system tumours: Analysis of 922 Chinese patients. *Pathology.* 2016;48(7):675-83.
- [16] Mellai M, Piazza A, Caldera V, Monzeglio O, Cassoni P, Valente G, et al. IDH1 and IDH2 mutations, immunohistochemistry and associations in a series of brain tumours. *J. Neuro-Oncol.* 2011;105(2):345-57.
- [17] Rasmussen BK, Hansen S, Laursen RJ, Kosteljanetz M, Schultz H, Nørgård BM, et al. Epidemiology of glioma: Clinical characteristics, symptoms, and predictors of glioma patients grade I-IV in the the Danish Neuro-Oncology Registry. *J Neuro-Oncol.* 2017;135(3):571-79.
- [18] Balss J, Meyer J, Mueller W, Korshunov A, Hartmann C, von Deimling A. Analysis of the IDH1 codon 132 mutations in brain tumours. *Acta Neuropathol.* 2008;116(6):597-602.
- [19] Hartmann C, Hentschel B, Wick W, Capper D, Felsberg J, Simon M, et al. Patients with IDH1 wild type anaplastic astrocytomas exhibit worse prognosis than IDH1-mutated glioblastomas, and IDH1 mutation status accounts for the unfavorable prognostic effect of higher age: Implications for classification of gliomas. *Acta Neuropathol.* 2010;120(6):707-18.
- [20] Capper D, Reuss D, Schittenhelm J, Hartmann C, Bremer J, Sahm F, et al. Mutation-specific IDH1 antibody differentiates oligodendrogliomas and oligoastrocytomas from other brain tumours with oligodendrogloma-like morphology. *Acta Neuropathol.* 2011;121(2):241-52.
- [21] Reuss DE, Sahm F, Schrimpf D, Wiestler B, Capper D, Koelsche C, et al. ATRX and IDH1-R132H immunohistochemistry with subsequent copy number analysis and IDH sequencing as a basis for an "integrated" diagnostic approach for adult astrocytoma, oligodendrogloma, and glioblastoma. *Acta Neuropathol.* 2015;129(1):133-46.
- [22] Lötsch D, Ghanim B, Laaber M, Wurm G, Weis S, Lenz S, et al. Prognostic significance of telomerase-associated parameters in glioblastoma: Effect of patient age. *Neuro-Oncol.* 2013;15(4):423-32.
- [23] Horbinski C, Kofler J, Kelly LM, Murdoch GH, Nikiforova MN. Diagnostic use of IDH1/2 mutation analysis in routine clinical testing of formalin-fixed, paraffin-embedded glioma tissues. *J. Neuropathol. Exp. Neurol.* 2009;68(12):1319-25.
- [24] Hu X, Miao W, Zou Y, Zhang W, Zhang Y, Liu H. Expression of p53, epidermal growth factor receptor, Ki-67 and O6 methylguanine DNA methyltransferase in human gliomas. *Oncol Lett.* 2013;6(1):130-34.
- [25] Cho MY, Jung SH, Kim TS. p53 protein overexpression in astrocytic neoplasms. *Yonsei Med. J.* 1995;36(6):521-26.
- [26] Popova SN, Bergqvist M, Dimberg A, Edqvist PH, Ekman S, Hesselager G, et al. Subtyping of gliomas of various WHO grades by the application of immunohistochemistry. *Histopathol.* 2014;64(3):365-79.
- [27] Arshad H, Ahmad Z, Hasan SH. Gliomas: Correlation of histologic grade, Ki67 and p53 expression with patient survival. *Asian Pac J Cancer Prev.* 2010;11(6):1637-40.

PARTICULARS OF CONTRIBUTORS:

1. Postgraduate, Department of Pathology, JSSAHER, Mysuru, Karnataka, India.
2. Associate Professor, Department of Pathology, JSSAHER, Mysuru, Karnataka, India.
3. Professor and Head, Department of Surgery, JSSAHER, Mysuru, Karnataka, India.

NAME, ADDRESS, E-MAIL ID OF THE CORRESPONDING AUTHOR:

Sapna Patel,
#3, Vth Main Road, Yadavagiri, Mysuru-570020, Karnataka, India.
E-mail: drsapnaharish@gmail.com

AUTHOR DECLARATION:

- Financial or Other Competing Interests: None
- Was Ethics Committee Approval obtained for this study? Yes
- Was informed consent obtained from the subjects involved in the study? Yes
- For any images presented appropriate consent has been obtained from the subjects. Yes

PLAGIARISM CHECKING METHODS: [Jain H et al.]

- Plagiarism X-checker: Feb 03, 2023
- Manual Googling: Apr 18, 2023
- iThenticate Software: May 24, 2023 (6%)

ETYMOLOGY: Author Origin

EMENDATIONS: 6

Date of Submission: Feb 04, 2023

Date of Peer Review: Mar 03, 2023

Date of Acceptance: May 25, 2023

Date of Publishing: Jun 01, 2023