

# Customized Sectional Stock Tray for a Patient with a Restricted Oral Opening: A Case Report

SHIVASAKTHY M., SYED ASHARAF ALI

## ABSTRACT

The branch of Prosthodontics is not only a science but also an art of handling patients who present with limitations in continuing with normal procedures. One such limitation is the difficulty in mouth opening of the patient due to various reasons like fracture due to trauma, oral sub mucous fibrosis, TMJ ankylosis, etc. Impressions can be made for patients with restricted mouth opening, with a sectional impression tray that can be assembled

and disassembled in the mouth and reassembled outside the mouth. This article describes a sectional stock tray system for making preliminary impressions. It may be used not only for individual dental arches, but also for patients with microstomia or constricted oral openings. This system allows many combinations of the right and left tray sizes and the forms to be assembled into a well-fitted anatomically-conforming tray in spite of the individual anatomic discrepancies.

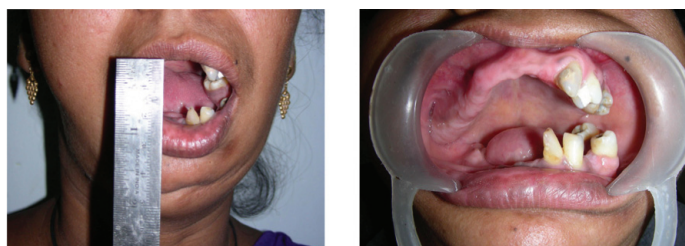**Key Words:** Sectional impression, restricted oral opening, stock tray

## INTRODUCTION

Quality diagnostic casts are critical for treatment planning. A stock tray which is fitted to the individual dental arch is usually adequate for this purpose. However, individual variables such as the size of the dental arch, the position of the remaining teeth and the amount of oral opening may make it difficult to make an acceptable preliminary impression by using a conventional stock tray. Various authors have described several techniques for making impressions for patients with a restricted oral opening [1-8].

Reduction in the maximal oral opening is a condition that may hinder the conventional prosthetic treatment procedures. The common reasons for this condition include scleroderma, orofacial malignancies, surgery, burns and TMJ ankylosis. The purpose behind the writing of this report was to describe a technique for customizing the plastic stock tray for making a preliminary impression for a partially edentulous patient.

A 33 year old female patient underwent gap arthroplasty and advancement genioplasty following ankylosis of the left side temporomandibular joint. The mouth opening of the patient post surgically was 28mm. The malaligned remaining teeth along with the restricted mouth opening created a difficulty in insertion of the stock tray for making a preliminary impression for the prosthetic treatment procedure.



[Table/Fig-1]: (a) Mouth opening (b) Intra oral view

## CUSTOMIZATION OF THE STOCK TRAY

Intra-oral measurements of the maxillary and mandibular arches of the patient were made for the selection of the appropriate sized stock tray. In the present case, insertion of the maxillary arch stock tray was impossible, whereas for the mandibular arch, an acceptable impression was made in a single step by using a conventional stock tray.

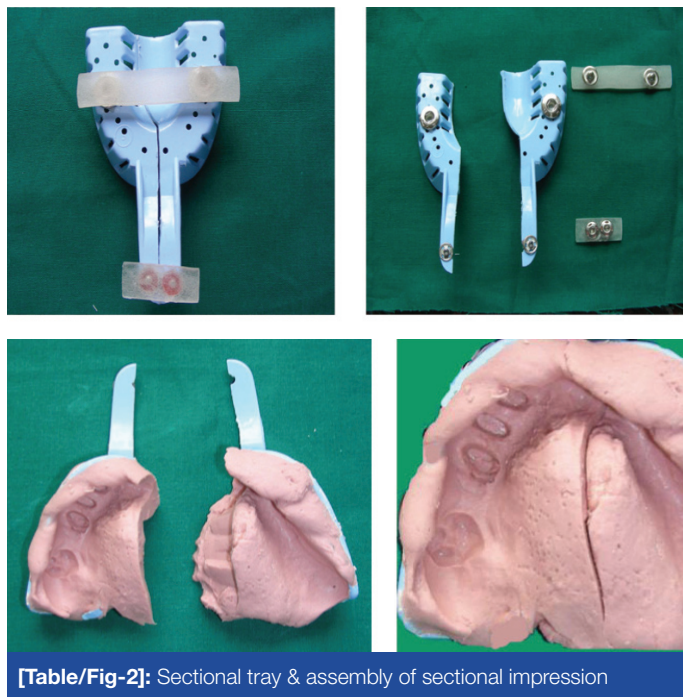
To the selected maxillary stock tray, four stainless steel press buttons were fixed. Two buttons were fixed one on either side of the midline of the handle and the other two were fixed one on either side of the arch area on the reverse side of the stock tray, by using an auto-polymerizing acrylic resin. The opposing parts of all the four press buttons were placed in their counterparts. Auto polymerizing acrylic plates were made and attached to the counterparts. After the resin was set, the acrylic plates along with the counterparts were detached and the maxillary plastic stock tray was sectioned along the midline of the handle and towards one side of the arch, leaving the center of the palate along with the other side of the arch. The sectioned tray can be reassembled accurately by using the press button attachments.

## IMPRESSION MAKING

A sectional, preliminary impression was made by using an irreversible hydrocolloid for one side of the arch. After the material was set, the impression was removed, it was washed and its open end was indexed by using a B.P. blade. The impression was resealed and the other half of the sectional tray was loaded with irreversible hydrocolloid, after which the impression was made. The set impression were removed sectionally from the oral cavity and reassembled outside by using the press button attachments and the cast was poured.

## DISCUSSION

Customization of the impression tray has been done for many years by using various methods [1-8].



[Table/Fig-2]: Sectional tray & assembly of sectional impression

Most of the cases require a modification in the stock trays than in the custom trays due to their size and rigidity.

For the above case, a plastic stock tray was used instead of a metal stock tray [2], as modifying a plastic tray is technically very simple as compared to a metal tray.

The novel technique of using stainless steel press buttons made the modification simpler without compromising on the accuracy. There was no need of special procedures or materials since the placement of the buttons was just done by using the regular auto cure polymerizing resin.

Conclusion : The technique of modification of the plastic stock tray provides the clinicians with a simple method for making impressions for a restricted mouth opening patient.

## REFERENCE

- [1] Cura C, et al. Fabrication of a sectional impression tray and a sectional complete denture for a patient with microstomia and trismus: A clinical report. *J Prosthet Dent* 2003;89:540-43.
- [2] Ohkubo C, et al. A sectional stock tray system for making impressions. *J Prosthet Dent* 2003;90:201-04.
- [3] McCord JF. A sectional complete denture for a patient with microstomia. *J Prosthet Dent* 1989;61:645-47.
- [4] Al-Hadi LA, Abbas H. Treatment of an edentulous patient with surgically induced microstomia: A Clinical report. *J Prosthet Dent* 2002;87:423-26.
- [5] Geckili O, et al. Impression procedures and construction of a sectional denture for a patient with microstomia: A Clinical report. *J Prosthet Dent* 2006;96:387-90.
- [6] Baker PS, et al. Impression procedure for patients with a severely limited mouth opening. *J Prosthet Dent* 2000; 84: 241-44.
- [7] Lubke RJ. Sectional impression tray for patients with a constricted oral opening. *J Prosthet Dent* 1984;52:135-37.
- [8] Bernetti R. Prosthetic rehabilitation for a patient with microstomia: A Clinical report. *J Prosthet Dent* 2004;92:322-27.

### AUTHOR(S):

1. Dr. Shivasakthy M.
2. Dr. Syed Asharaf Ali

### PARTICULARS OF CONTRIBUTORS:

1. MDS., Senior lecturer, Department of Prosthodontics, Indira Gandhi Institute of Dental Sciences, Sri Balaji Vidyapeeth, Puducherry.
2. MDS., Professor, Department of Prosthodontics, Rajah Muthiah Dental College & Hospital, Annamalai University, Chidambaram.

### NAME, ADDRESS, TELEPHONE, E-MAIL ID OF THE CORRESPONDING AUTHOR:

Dr. M. Shivasakthy MDS.,  
No.4, Fifth Cross Street,  
Thanthai Periyar Nagar  
Puducherry.  
E-mail: dreamshakthy@yahoo.co.in

### DECLARATION ON COMPETING INTERESTS:

No competing Interests.

Date of Submission: **Aug 18, 2011**  
Date of peer review: **Sep 22, 2011**  
Date of acceptance: **Nov 17, 2011**  
Date of Publishing: **Dec 25, 2011**