


Modified Coronally Advanced Tunnel Technique in the Treatment of Multiple Gingival Recessions Associated with and without Non Carious Cervical Lesions- A Prospective Clinical Study

P KAUSALYA DEVI¹, GAUTAMI S PENMETS², MOHAN KUMAR PASUPULETI³,
NVS SRUTHIMA GOTTUMUKKALA⁴, KSV RAMESH⁵, VIVEK BAIPALLI⁶



ABSTRACT

Introduction: Gingival Recession (GR) can be associated to periodontal disease-causing dentinal hypersensitivity, root caries and even aesthetic problems. A combination of the Modified Coronally Advanced Tunnel Technique (MCAT) with Subepithelial Connective Tissue Graft (SCTG) can be considered an option for treating multiple GR.

Aim: To evaluate the effectiveness of root coverage using MCAT along with SCTG in multiple GR with and without Non Carious Cervical Lesions (NCCL).

Materials and Methods: The present prospective clinical study was conducted in Department of Periodontology at Vishnu Dental College, Bhimavaram, Andhra Pradesh, India, from June 2018 to December 2019. A total of 24 patients seeking treatment for multiple GR in which 12 patients with recessions alone and 12 patients associated with NCCL were included in the study. Clinical measurements of Pocket Probing Depth (PPD), Clinical Attachment Level (CAL), Recession Depth (RD) and Recession Width (RW), Width of Keratinised Tissue (KTW), Gingival Thickness (GT), Pink Aesthetic Score

and hypersensitivity scores were determined at baseline and six months. Descriptive statistics, Independent samples t-test, repeated measures Analysis of Variance (ANOVA), and paired t-tests were used in data analysis. The p-value <0.05 would be considered statistically significant.

Results: The mean age of the patients was 30±10.16 years. The study group comprised of 18 males and six females, constituting male to female ratio as 3:1. A statistical significance in reduction of recession was seen from baseline to six months in both control and test groups which are (9.67±1.15 mm to 0.92±1.67 mm) and (10.92±0.99 mm to 0.67±1.23 mm) respectively and increase in KTW was seen from baseline to six months in both groups which are (1.58±0.66 mm to 3.2±0.75 mm) and (1.75±0.45 mm to 3.50±0.67 mm), respectively. However, a statistically significant decrease in hypersensitivity was observed in the MCAT+SCTG+NCCL group.

Conclusion: The results of the present study suggested that MCAT could be opted as a treatment of choice for multiple GR associated with non carious lesions, as well in terms of aesthetics and hypersensitivity.

Keywords: Connective tissue graft, Hypersensitivity, Root coverage

INTRODUCTION

The GR is the exposure of root surface due to displacement of gingival margin apical to the Cemento-Enamel Junction (CEJ) [1]. The exposed root surface may result in retention of plaque, teeth hypersensitivity, NCCL which contributes to poor oral hygiene substantially leading to tooth loss and compromised aesthetics of the patient [2]. To overcome the above mentioned shortcomings of the exposed roots, a well-planned surgical technique is required for Complete Root Coverage (CRC) with predictable treatment outcome. As mentioned earlier usually GR when associated with NCCL, results in patients discomfort in terms of hypersensitivity and aesthetics. A NCCL is the loss of hard tissue at the CEJ in the absence of caries. Zucchelli G et al., classified NCCLs and introduced guidelines for the clinical decision-making process [3].

Several surgical techniques were addressed for treating isolated GR, showing a high predictability in terms of root coverage, whereas treatment approach for multiple GR stood as challenging for the clinician to treat all recession defects at single surgical approach [4]. Evidence echoes that coronally advanced flap based procedures are considered as reliable approach for CRC, while treating recession defects [5-7]. However, there is lack of evidence on predictability of treatment outcome for coverage of multiple recession defects.

In spite of various surgical procedures such as envelope flap, pouch and tunnel technique, VISTA (Vestibular Incision Subperiosteal Tunneling Access), MCAT is a technique devoid of vertical incisions with a benefit of allowing the graft to be stabilised and gingiva can be placed in the most coronal position. This ensures good vascularisation, nourishment of the flap and faster healing at an early phase. SCTG, the gold standard procedure of perioplastic surgery is considered as the best to achieve a successful root coverage due to its dual blood supply from periosteal or osseous base and overlying flap which is responsible for the increased predictability of the procedure by helping in the revascularisation of the graft tissue [7,8]. A combined approach of periodontal and restorative procedures ensures successful treatment outcome which were maintained overtime [9,10]. The restorative procedure should always precede periodontal surgery as restorative material provides creeping attachment resulting in coronal positioning of gingival tissue attaining CRC. The choice of restorative material also plays a pivotal role for long term clinical success [10].

The restorative material should possess mechanical properties suitable for retention with appropriate aesthetic properties, and be biocompatible in order to ensure gingival reattachment. Studies have suggested the alternative use of micro-filled resin composites

and resin composites, with no significant differences observed in the gingival reattachment level between resin-modified GI and flowable resin composite [9,11]. There is a lack of evidence from randomised controlled clinical trials about the ability of combined procedure (coronal flap plus restoration) to provide sufficient soft tissue coverage and predictability of treatment outcome.

On the basis of the above-mentioned data, as well as, limitations of a clinical scenario such as multiple recessions associated with NCCL, the aim of present study was to evaluate the efficacy of MCAT technique with subepithelial connective tissue graft along with restoration in multiple recession defects with and without non carious cervical lesions.

MATERIALS AND METHODS

This prospective clinical study was conducted in Department of Periodontology at Vishnu Dental College, Bhimavaram, Andhra Pradesh, India, from June 2018 to December 2019. Patients who attended Outpatient Department (OPD) of Periodontics and Implantology were enrolled. The study was approved and ethical clearance was obtained from the Institutional Ethical Committee (Ref No: VDC/IEC/2017/08). All the procedures were followed according to the Consolidated Standards of Reporting Trials (CONSORT) guidelines and were in accordance with the ethical standards of the responsible committee on human experimentation (Institutional or regional) and with the Helsinki Declaration of 1975 that was revised in 2013.

Inclusion criteria: After obtaining the informed consent, patients aged between 18 to 60 years, who were systemically healthy with no contraindications for periodontal surgery with a minimum of two adjacent GR of Miller's Class-I [1] alone (Control group) and with NCCL Type-I or Type-II (Test Group) were included in the study.

Exclusion criteria: Patients with active gingival and periodontal disease, systemic conditions that would interfere with healing, habits like smoking and pregnant or lactating women were excluded.

Sample size calculation: Sample size of 24 multiple GR, divided into two groups was obtained using G Power software [9].

Input: t-tests-Means: Difference between two independent means (two groups)

Analysis: A priori: Compute required sample size

Input: Tail (s)=Two

Effect size $d=1.241350$ [2]

α err prob=0.05

Power (1- β err prob)=0.80

Allocation ratio N2/N1=1

Output: Non centrality parameter $\delta=3.0406741$

Critical $t=2.0738731$, Df=22, sample size group 1=12, sample size group 2=12, total sample size=24.

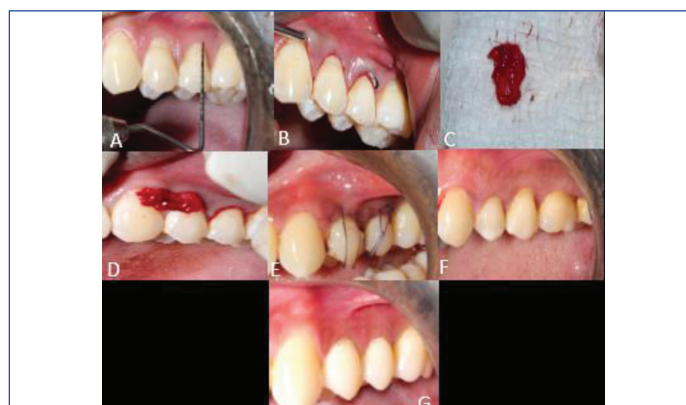Study Procedure

According to Zucchelli G et al., NCCL occurring on the root surface only are classified as NCCL Type-I and II [3]. All participants received a session of oral prophylaxis. Test group with non carious lesions were restored with resin modified GIC and fine polishing was done. Surgical treatment was performed, only when patients achieved adequate plaque control.

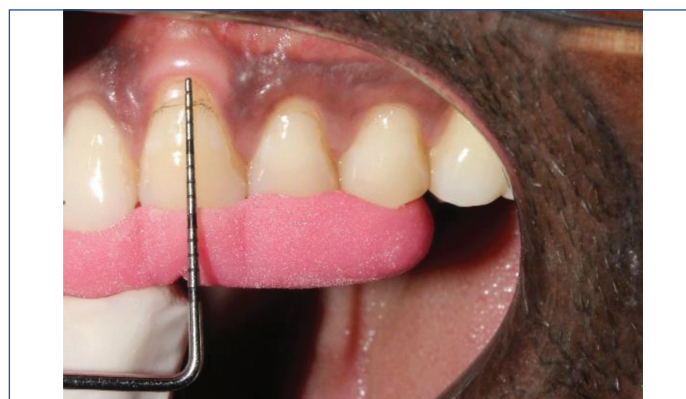MCAT procedure: Surgical site was anaesthetised using 1:2,00,000 Local Anaesthesia (LA). Approach of the surgical technique began with a sulcular incision using ophthalmic blade followed by elevation of papillae using papillae elevator (Blue Dent Papillae elevator, Bangalore). Tunnel was extended one or two teeth beyond the area of interest.

A microsurgical tunneling Knife 1 (Blue Dent) was used for initial tunnel preparation. Tunneling knife 2 was used to remove the attachment till the mucogingival junction, as well as, through the gingival sulcus of the teeth being augmented to allow for low-tension coronal

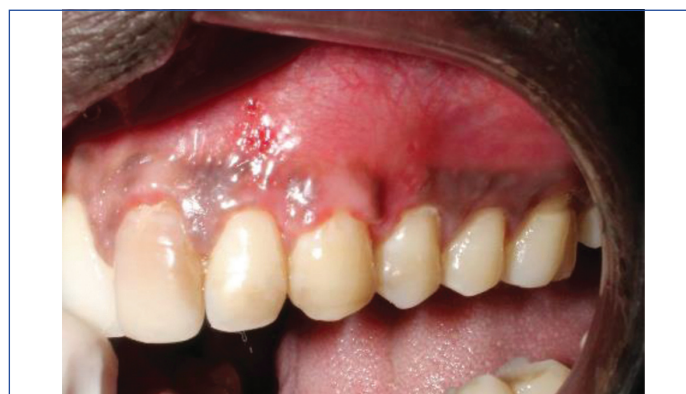repositioning of the gingiva. Furthermore, using a papillae elevator and tunnelling knife 2, the tunnel was extended interproximally under each papilla as far as the embrasure space allowed, without making any surface incisions into the papillae. After giving local anaesthetic, the palatal donor site was checked for 3 mm thickness using a periodontal probe. Two parallel incisions were created using a 15-number blade in the region between the first molar and the canine, and vertical incisions were made at the mesial and distal ends of the majority of exterior incisions. In order to retract the SCTG graft, 4-0 silk sutures were placed into the palatal tissue [10,11]. Sutures were used to close the palate wound in the vertical incisions, as well as, the suture used to retract palatal tissue for access. Graft was cut to the precise measurements of the operating room. A fine-tipped, curved, serrated forceps was used to insert the membrane and stabilise in the subperiosteal tunnel. A horizontal mattress suture using a 5-0 polypropylene suture and a C3 needle was then placed at roughly 2 to 3 mm apical to the gingival margin of each tooth, covering the breadth of the tooth, to maintain the membrane and mucogingival complex in its new location [Table/Fig-1-5].



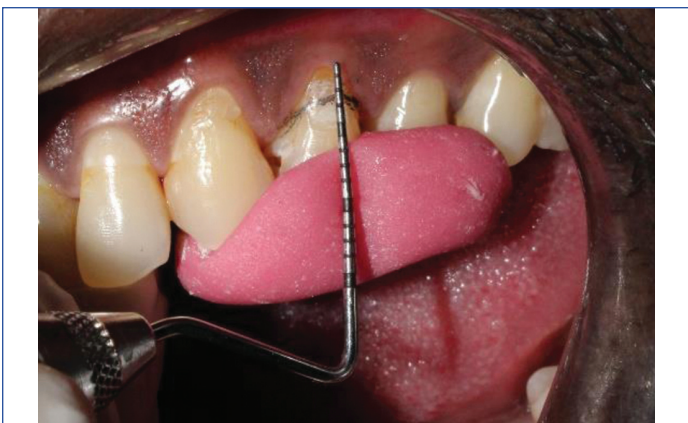[Table/Fig-1]: a) Preoperative photograph showing 3 mm of recession depth with cervical abrasion restored with GIC. b) Tunneling done using Tunneling knife 1 and 2. c) Connective Tissue Graft harvested d) Graft placed into the prepared tunnel e) Horizontal mattress sutures placed with vicryl 5-0 sutures and stabilised using composite. f) Suture removal done after 10 days. g) Complete coverage of recession seen after six months of follow-up.



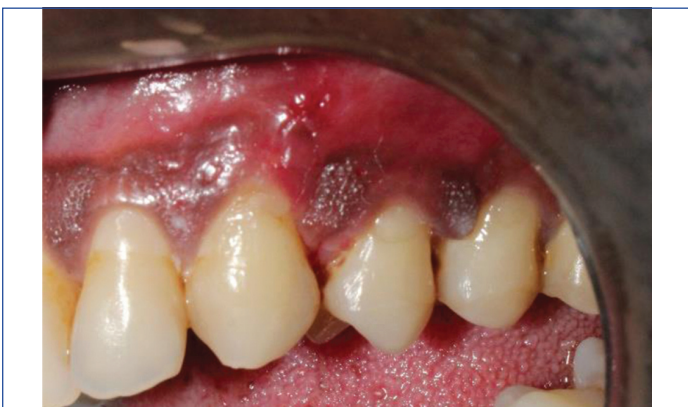[Table/Fig-2]: Test Group: Millers Class-I recession in 23.



[Table/Fig-3]: Six months postoperative test group.



[Table/Fig-4]: Control Group: Millers Class-I recession irt 24.



[Table/Fig-5]: Six months postoperative control group.

Parameters		Mean	SD	Mean difference	p-value*
Plaque Index (PI)	Control	0.87	0.30	0.75	0.062
	Test	1.62	0.37		
Gingival Index (GI)	Control	1.20	0.30	-0.07	0.641
	Test	1.13	0.37		
Recession Depth (RD)	Control	2.75	0.45	0.00	-
	Test	2.75	0.45		
Recession Width (RW)	Control	9.67	1.15	-1.25	0.057
	Test	10.92	0.99		
Keratinised Tissue Width (KTW)	Control	1.58	0.66	-0.17	0.326
	Test	1.75	0.45		
Aesthetics	Control	3.08	0.51	-0.34	0.527
	Test	3.42	0.51		
*Hypersensitivity	Control	2.77	0.13	-2.01	0.052
	Test	4.78	0.51		
Pocket Probing Depth (PPD)	Control	2.50	0.52	0.00	-
	Test	2.50	0.52		
Clinical Attachment Level (CAL)	Control	5.0	0.60	1.42	0.072
	Test	3.58	0.79		
Gingival Thickness (GT)	Control	0.8	0.13	0.00	-
	Test	0.8	0.10		
Visual Analogue Scale (VAS)	Control	8.58	0.62	0.17	<0.001*
	Test	8.75	0.51		

[Table/Fig-6]: Intergroup comparison of parameters at baseline. Mean±SD values presented in mm; *p-value <0.05 was considered statistically significant, Independent sample t-test

Parameters recorded: Recording of all the parameters such as the Gingival Index (GI) (Löe and Silness), Plaque Index (PI) (Silness and Loe), Probing Pocket Depth (PPD), Width and Depth of Recession (RW and RD), Keratinised Tissue Width (KTW), Clinical attachment level (CAL) and GT were done using UNC 15 probe at baseline and after six months [12]. Hypersensitivity, pain scores were recorded using Visual Analogue scale (VAS) at baseline and after six months. Professional aesthetic score was evaluated by using Pink Aesthetic Score at baseline and after six months [13].

STATISTICAL ANALYSIS

Data were analysed using Statistical Package for Social Sciences (SPSS) version 21.0 software (IBM SPSS, IBM Corp., Armonk, NY, USA). Descriptive statistics, Independent samples t-test and paired t-tests were used in data analysis. For all the analysis, p-value <0.05 was considered statistically significant.

RESULTS

The age of the patients was ranging between 18 to 60 years with the mean age of 30±10.16 years. The study group comprised of 18 males and six females, constituting male to female ratio as 3:1. The RD and RW at baseline in both control and test groups were (2.75 mm and 9.67 mm) and (2.75 mm and 10.92 mm), respectively. There were no significant difference between GI, PI, PPD, width and depth of recession, KTW, CAL between the test and control group at baseline (p>0.05) [Table/Fig-6]. There were no significant differences in the scores of GI, PI, width and depth of recession, width of keratinised issue and root coverage after six months of surgery when compared between the two groups. However, decrease in hypersensitivity scores was statistically significant in test group samples after six months of follow-up [Table/Fig-7].

A reduction in RD was seen from baseline to six months in both control and test groups which are (2.75±0.45 mm to 0.42±0.79 mm) and (2.75±0.45 mm to 0.33±0.65 mm), respectively. A statistical significance in reduction of Recession Width (RW) was seen from

Parameters		Mean	SD	Mean difference	p-value*
Plaque Index (PI)	Control	0.67	0.52	0.02	0.896
	Test	0.65	0.39		
Gingival Index (GI)	Control	0.54	0.20	0.23	0.432
	Test	0.30	0.10		
Recession Depth (RD)	Control	0.42	0.79	0.09	0.781
	Test	0.33	0.65		
Recession Width (RW)	Control	0.92	1.67	0.25	0.681
	Test	0.67	1.23		
Keratinised Tissue Width (KTW)	Control	3.25	0.75	-0.25	0.401
	Test	3.50	0.67		
Aesthetics	Control	8.58	0.66	0.17	0.482
	Test	8.75	0.45		
Hypersensitivity	Control	4.52	1.67	0.23	0.002
	Test	3.77	1.23		
Pocket Probing Depth (PPD)	Control	2.00	0.00	-0.16	0.152
	Test	2.17	0.38		
Clinical Attachment Level (CAL)	Control	2.33	0.49	0.08	0.670
	Test	2.25	0.45		
Gingival Thickness (GT)	Control	0.9	0.27	-1.75	<0.001*
	Test	1.09	0.08		
Pain [Visual Analogue Scale (VAS)]	Control	3.75	0.62	0.17	<0.001*
	Test	3.58	0.51		

[Table/Fig-7]: Intergroup comparison of parameters at six months. Mean±SD values presented in mm; *p-value <0.05 was considered statistically significant, Independent sample t-test

baseline to six months in both control and test groups which are (9.67±1.15 mm to 0.92 ±1.67 mm) and (10.92±0.99 mm to 0.67±1.23 mm) respectively and increase in KTW was seen from baseline to six months in both groups which are (1.58±0.66 mm to 3.2±0.75 mm) and (1.75±0.45 mm to 3.50±0.67 mm), respectively [Table/Fig-6-8]. Improvement in aesthetic scores was observed

after six months. The current study showed satisfactory results regarding CRC in both the groups, which were around 88.5%.

Parameters	Groups	Time points	Mean	SD	Mean difference	p-value*
Plaque Index (PI)	Control group	Baseline	0.87	0.30	0.67	<0.001*
		6 months	0.67	0.52		
	Test group	Baseline	1.62	0.37	0.82	<0.001*
		6 months	0.65	0.39		
Gingival Index (GI)	Control group	Baseline	1.20	0.30	0.67	<0.001*
		6 months	0.54	0.20		
	Test group	Baseline	1.13	0.37	0.82	<0.001*
		6 months	0.30	0.10		
Pocket Probing Depth (PPD)	Control group	Baseline	2.50	0.52	0.50	0.007*
		6 months	2.0	0.00		
	Test group	Baseline	2.50	0.52	0.33	0.104
		6 months	2.17	0.38		
Clinical Attachment Level (CAL)	Control group	Baseline	5.0	0.60	2.67	<0.001*
		6 months	2.33	0.49		
	Test group	Baseline	3.58	0.79	1.33	<0.001*
		6 months	2.25	0.45		
Recession Depth (RD)	Control group	Baseline	2.75	0.45	2.33	<0.001*
		6 months	0.42	0.79		
	Test group	Baseline	2.75	0.45	2.41	<0.001*
		6 months	0.33	0.65		
Recession Width (RW)	Control group	Baseline	9.67	1.15	8.75	<0.001*
		6 months	0.92	1.67		
	Test group	Baseline	10.92	0.99	10.25	<0.001*
		6 months	0.67	1.23		
Width of Keratinised Tissue (WKT)	Control group	Baseline	1.58	0.66	-1.67	<0.001*
		6 months	3.25	0.75		
	Test group	Baseline	1.75	0.45	-1.75	<0.001*
		6 months	3.50	0.67		
Gingival Thickness (GT)	Control group	Baseline	0.8	0.13	-1.67	<0.001*
		6 months	0.9	0.27		
	Test group	Baseline	0.8	0.10	-1.75	<0.001*
		6 months	1.09	0.08		
Aesthetic scores	Control group	Baseline	3.08	0.51	1.91	<0.001*
		6 months	8.58	0.93		
	Test group	Baseline	3.42	0.51	1.25	<0.001*
		6 months	8.75	0.45		
Pain (VAS)	Control group	Baseline	8.58	0.66	-4.83	<0.001*
		6 months	3.75	0.62		
	Test group	Baseline	8.75	0.45	-5.16	<0.001*
		6 months	3.58	0.51		
Hypersensitivity (VAS)	Control group	Baseline	2.77	0.13	-4.83	<0.001*
		6 months	4.52	1.67		
	Test group	Baseline	4.78	0.51	-5.16	<0.001*
		6 months	3.77	1.23		

[Table/Fig-8]: Intragroup comparison of parameters from baseline to six months. Mean±SD values presented in mm

DISCUSSION

In the current study, the mean PI, GI scores, when compared between test and control group at baseline and six months after surgery not showed any statistical significance. These results are in accordance with the study results by Carvalho PF et al., and Allegri

MA et al., [8,9]. In the current study, the mean PPD, and CAL scores when compared between test and control group at baseline and six months after surgery not showed any statistical significance. These results are in accordance with the study results by Bherwani C et al., and Alkan A et al., [10,11].

In the present study, the success and predictability of treatment outcomes like root coverage, increase in KTW, decrease in recession defects achieved by using MCAT technique and SCTG that improved GT and position of gingiva [6,14]. Due to dearth of literature on prospective clinical trials for evaluating the effectiveness in treatment of multiple recession defects when associated with NCCL using MCAT as surgical approach, the present study was undertaken to evaluate the effectiveness of MCAT, SCTG and Glass Ionomer Cement (GIC) on multiple recessions when associated with non carious lesions.

The treatment of NCCL associated with GR is always challenging for clinicians. The choice of surgical technique for root coverage as well as restorative material for treating of NCCL is important for long-term clinical success. The surgical technique opted must be precise with good vascularisation providing early healing and less discomfort to the patient by satisfying their aesthetic demands [14]. To achieve gingival reattachment, the material must be biocompatible, have the right cosmetic qualities, and have mechanical properties that are ideal for retention. Due to the excellent retention rates of these materials and their favourable biocompatibility for gingival reattachment, GIC or resin modified GIC advised for NCCLs [15].

In the present study, resin-modified GIC was used before the surgical procedure which helped in creeping movement of gingiva and resulted in coronal positioning of gingival tissue attaining CRC which were in accordance with the studies previously published in the literature [9,11]. The present study has shown improved results by reducing RD in both the groups from baseline to six months which were in accordance with Cairo F et al., showing improved results in reducing RD and RW [6].

In order to treat adjacent numerous GR, Cairo F et al., did a study in 2006 using a modified coronally advanced flap combined with a sub epithelial connective tissue graft. The results had shown improved results in all the clinical parameters especially, increased thickness of gingival biotype and the KTW in both the groups from baseline to six months which were in accordance with the present study which had shown improved thickness and amount of keratinised tissue [7]. Allegri MA et al., conducted a study on NCCL associated with multiple GR in the maxillary arch and obtained improved results in all the clinical parameters especially in achieving root coverage and reducing hypersensitivity when compared to baseline and six months postsurgical time. These results obtained the present research in reference to root coverage and reducing hypersensitivity are coincidental [9]. Bherwani C et al., and Alkan A et al., in their research studies by using connective tissue grafting to treat recession resulted in increasing the keratinised and attached gingiva when compared to baseline parameters. The results of the present study were in reference to increased keratinised and attached gingiva by using subepithelial connective graft in the study result of Bherwani C et al., and Alkan A et al., [10,11].

The current study has shown satisfactory results regarding CRC in both the groups which were around 88.5%. This was in accordance with the study of Santamaria MP et al., which showed coverage of non carious lesion around 91.14% for test group (CAF plus Restoration) and around 87.9% in groups treated with CAF alone [15]. These results were also similar to the results obtained in a study done by Aroca S et al., compared the efficacy of MCAT+CM (Collagen Matrix) with MCAT+SCTG in the treatment of Miller's Class-I and II recessions for 12 months [16]. The present study noted that

there was no statistical significance between Pink Aesthetic score, regarding the aesthetic analysis which was in accordance with a case series reported by Zucchelli G et al., [17]. It is interesting to note that, the results of the present study evaluated the hypersensitivity score of the patients before and after the surgery. There was decrease in the dentinal sensitivity of the patient from baseline to six months in both test and control groups but the test group showing better results from baseline to six months which was in accordance with a randomised clinical trial done by Santamaria MP et al., showing significant reduction in dentinal sensitivity [15].

There are many systematic reviews which have proven the success of coronal flap advancement in resulting predictable treatment outcomes in cases of multiple recessions with or without non carious lesions [6,7,12]. The present study has shown better results in terms of measured periodontal parameters but not much significance was found between two groups, except dentinal sensitivity which was much significant in test group. The results of similar studies have been tabulated in [Table/Fig-9] [3,8,15,16].

S. No.	Author's name and year	Place of study	Sample size	Parameters compared	Conclusion
1	P Kausalya Devi et al., 2023 (Present study)	Vishnu Dental College, Bhimavaram, Andhra Pradesh, India.	24	Gingival Index, Plaque index, Probing Pocket Depth, Width and Depth of recession, width of keratinized tissue, CAL and gingival thickness. hypersensitivity, pain scores and Pink Aesthetic Score.	Multiple gingival recessions with and without non carious cervical lesions could be effectively covered by a root-covering subepithelial connective tissue transplant and modified coronally advanced tunnel method. Choosing the MCAT approach to treat multiple recessions has the added benefits of reducing dentinal sensitivity and improving aesthetics.
2	Zucchelli G et al., 2011 [3]	School of Dentistry, University of Bologna, in the period between September 2007 and April 2008.	94	Bleeding on probing, probing depth, height of keratinised tissue, patient aesthetic evaluation.	The majority of NCCLs connected to gingival recessions had good aesthetic appearance and the right emergence profile thanks to the suggested treatments.
3	Carvalho PF et al., 2006 [8]	Department of Periodontics, São Leopoldo Mandic Dental Research Institute, Campinas, São Paulo (SP), Brazil.	10	Probing depth (PD), Clinical Attachment Level (CAL), Recession Depth (RD), and Keratinized Tissue (KTW).	The subepithelial connective tissue graft and modified coronally advanced flap together produced root coverage at numerous neighbouring gingival recessions along with gains in the CAL and in the breadth of KT.

4	Santamaria MP et al., 2008 [15]	Department of Prosthodontics and Periodontics, State University of Campinas, Piracicaba, SP, Brazil.	19	Bleeding On Probing (BOP), Pocket Probing Depth (PD), Relative Gingival Recession (RGR), Clinical Attachment Level (CAL), non carious Cervical Lesion Height (CLH), and dentin sensitivity (DS).	After six months, both surgeries offered comparable soft tissue covering. Despite the fact that a greater reduction in DS was observed after CAF+R, longitudinal observations are necessary to confirm these results.
5	Aroca S et al., 2013 [16]	Department of Periodontology, University of Bern, 3010 Bern, Switzerland.	22	Gingival Recession Depth (GRD), Probing Pocket Depth (PD), Clinical Attachment Level (CAL), Keratinised Tissue Width (KTW), Gingival Recession Width (GRW) and Gingival Thickness (GT).	While using CM in conjunction with MCAT resulted in lower CRC than CTG in the treatment of Miller Class-I and II MAGR, it may be an option to CTG in terms of surgical time and patient morbidity.

[Table/Fig-9]: Similar studies from the literature [3,8,15,16].

Limitation(s)

The study's limitation was the short period of time that is six months used to compare root coverage.

CONCLUSION(S)

The MCAT along with SCTG was effective in root coverage in multiple GR with and without NCCL. Reduction in dentinal sensitivity and improvement in aesthetics are added benefits in choosing MCAT technique in treating multiple recessions.

Acknowledgement

The authors are grateful to Professor Nimmakayala Deepthi, working at Kendriya Vidyalaya School, Hyderabad, Telangana as PGET, for her kind help in English proofreading of the manuscript.

REFERENCES

- [1] Kassab MM, Cohen RE. The etiology and prevalence of gingival recession. J Am Dent Assoc. 2003;134(2):220-25.
- [2] Albandar JM, Kingman A. Gingival recession, gingival bleeding, and dental calculus in adults 30 years of age and older in the United States, 1988-1994. J Periodontol. 1999;70(1):30-43.
- [3] Zucchelli G, Gori G, Mele M, Stefanini M, Mazzotti C, Marzadori M, et al., non carious cervical lesions associated with gingival recessions: A decision-making process. J Periodontol. 2011;82(12):1713-24.
- [4] Bartlett DW, Shah P. A critical review of non carious cervical (wear) lesions and the role of abfraction, erosion, and abrasion. J Dent Res. 2006;85(4):306-12.
- [5] Zucchelli G, Testori T, De Sanctis M. Clinical and anatomical factors limiting treatment outcomes of gingival recession: A new method to predetermine the line of root coverage. J Periodontol. 2006;77(4):714-21.
- [6] Cairo F, Pagliaro U, Nieri M. Treatment of gingival recession with coronally advanced flap procedures: A systematic review. J Clin Periodontol. 2008;35(8 Suppl):136-62.
- [7] Cairo F, Pagliaro U, Buti J, Baccini M, Graziani F, Tonelli P, et al. Root coverage procedures improve patient aesthetics. A systematic review and Bayesian network meta-analysis. J Clin Periodontol. 2016;43(11):965-75.
- [8] Carvalho PF, da Silva RC, Cury PR, Joly JC. Modified coronally advanced flap associated with a subepithelial connective tissue graft for the treatment of adjacent multiple gingival recessions. J Periodontol. 2006;77(11):1901-06.
- [9] Allegri MA, Landi L, Zucchelli G. Non carious cervical lesions associated with multiple gingival recessions in the maxillary arch. A restorative-periodontal effort for esthetic success. A 12-month case report. Eur J Esthet Dent. 2010;5(1):10-27.
- [10] Bherwani C, Kulloli A, Kathariya R, Shetty S, Agrawal P, Gujar D, et al. Zucchelli's technique or tunnel technique with subepithelial connective tissue graft for treatment of multiple gingival recessions. J Int Acad Periodontol. 2014;16(2):34-42.

- [11] Alkan A, Keskiner I, Yuzbasioglu E. Connective tissue grafting on resin ionomer in localized gingival recession. *J Periodontol.* 2006;77(8):1446-51.
- [12] Löe H. The gingival index, the plaque index and the retention index systems. *The J Periodontol.* 1967;38(6):610-16.
- [13] Belsler UC, Grütter L, Vailati F, Bornstein MM, Weber HP, Buser D. Outcome evaluation of early placed maxillary anterior single-tooth implants using objective esthetic criteria: A cross-sectional, retrospective study in 45 patients with a 2- to 4-year follow-up using pink and white esthetic scores. *J Periodontol.* 2009;80(1):140-51.
- [14] Cairo F, Nieri M, Pagliaro U. Efficacy of periodontal plastic surgery procedures in the treatment of localized facial gingival recessions. A systematic review. *J Clin Periodontol.* 2014;41(Suppl 15):S44-62.
- [15] Santamaria MP, Suaid FF, Casati MZ, Nociti FH, Sallum AW, Sallum EA. Coronally positioned flap plus resin-modified glass ionomer restoration for the treatment of gingival recession associated with non carious cervical lesions: A randomized controlled clinical trial. *J Periodontol.* 2008;79(4):621-28.
- [16] Aroca S, Molnár B, Windisch P, Gera I, Salvi GE, Nikolidakis D, et al., Treatment of multiple adjacent Miller Class-I and II gingival recessions with a Modified Coronally Advanced Tunnel (MCAT) technique and a collagen matrix or palatal connective tissue graft: A randomized, controlled clinical trial. *J Clin Periodontol.* 2013;40(7):713-20.
- [17] Zucchelli G, Mele M, Stefanini M, Mazzotti C, Mounssif I, Marzadori M, et al. Predetermination of root coverage. *J Periodontol.* 2010;81(7):1019-26.

PARTICULARS OF CONTRIBUTORS:

1. Postgraduate, Department of Periodontics, Vishnu Dental College, Bhimavaram, Andhra Pradesh, India.
2. Professor and Head, Department of Periodontics, Vishnu Dental College, Bhimavaram, Andhra Pradesh, India.
3. Associate Professor, Department of Periodontics, Vishnu Dental College, Bhimavaram, Andhra Pradesh, India. **Orcid: 0000-0001-7797-1890**
4. Professor, Department of Periodontics, Vishnu Dental College, Bhimavaram, Andhra Pradesh, India.
5. Associate Professor, Department of Periodontics, Vishnu Dental College, Bhimavaram, Andhra Pradesh, India.
6. Senior Professor, Department of Periodontics, Vishnu Dental College, Bhimavaram, Andhra Pradesh, India.

NAME, ADDRESS, E-MAIL ID OF THE CORRESPONDING AUTHOR:

Dr. Mohan Kumar Pasupuleti,
Associate Professor, Department of Periodontics, Vishnu Dental College,
Bhimavaram-534202, Andhra Pradesh, India.
E-mail: mosups@gmail.com

PLAGIARISM CHECKING METHODS: [\[Jain H et al.\]](#)

- Plagiarism X-checker: Nov 26, 2022
- Manual Googling: Feb 10, 2023
- iThenticate Software: Mar 01, 2023 (20%)

ETYMOLOGY: Author Origin**EMENDATIONS:** 9**AUTHOR DECLARATION:**

- Financial or Other Competing Interests: None
- Was Ethics Committee Approval obtained for this study? Yes
- Was informed consent obtained from the subjects involved in the study? Yes
- For any images presented appropriate consent has been obtained from the subjects. Yes

Date of Submission: **Nov 23, 2022**Date of Peer Review: **Jan 02, 2023**Date of Acceptance: **Mar 02, 2023**Date of Publishing: **Jul 01, 2023**