

# Venolymphatic Malformation over the Left Elbow and Left Breast: A Rare Case Report

DAKSHAYANI SATISH NIRHALE<sup>1</sup>, MAHENDRA WANTE<sup>2</sup>, VIJETHA BANDLA<sup>3</sup>, ANOOP BURRA<sup>4</sup>

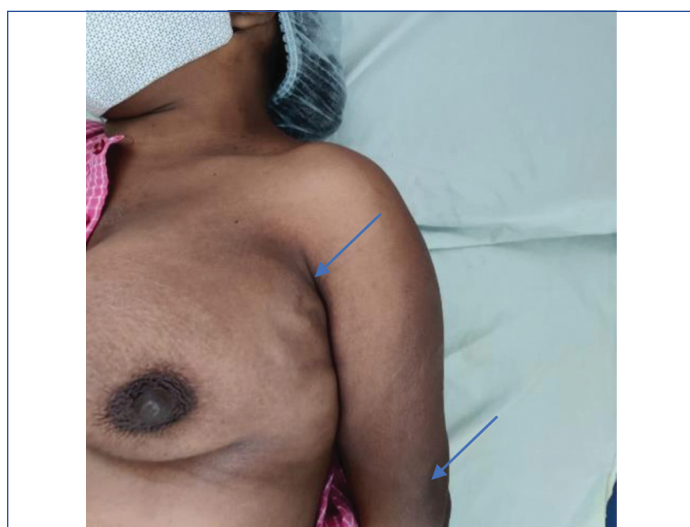
## ABSTRACT

Venolymphatic malformations occur due to dysplasia of lymphatic and venous vessel structures. These tumour-like lesions cause tissue abnormality with impaired function and have aesthetic importance when involving the craniofacial region. Vascular lesions are classified as haemangiomas and other vascular malformations. They are named after the vessels involved in malformation like arterial, venous, lymphatic, or mixed types. The present study represents a rare case report of a 23-year-old patient, who presented to the surgery Department with swelling over the left elbow and a lump over the left breast, which was diagnosed as venolymphatic malformation involving the left breast and left elbow joint, which is an unusually affected anatomical region by this congenital anomaly. Ultrasonography (USG), the primary tool for diagnosis, was performed. Later, the patient underwent Magnetic Resonance Imaging (MRI) for confirmation and to determine the extent of the lesion. Excision of the lesion was done over left elbow completely with a wide margin and histopathology confirmed the final diagnosis. Venous malformations (VM) are the most common among these congenital malformations, with an incidence of over 50%. Lymphatic Malformations (LM) have a much lower incidence than VM, but the combination of venous and LM has a very low incidence.

**Keywords:** Dysplasia, Magnetic resonance imaging, Vascular malformations, Venolymphatic type

## CASE REPORT

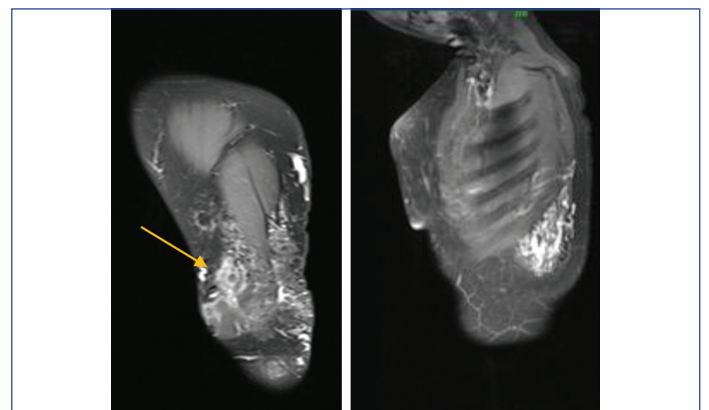
A 23-year-old female patient presented to the Outpatient Department (OPD) of surgery with chief complaints of swelling over the left elbow and left breast since childhood. History of associated pain noticed two months ago. The swelling was initially small and gradually increased during her adolescent years. On examination, a 4×3 cm swelling was observed over the lateral aspect of the left elbow joint. It was soft, mobile, non-tender, non-pulsatile, and compressible, with smooth borders. Nodularity was seen in the left elbow swelling. Additionally, a 3×2 cm lump was noted in the outer quadrant of the left breast. It was cystic in nature, non-tender, compressible and non-pulsatile with nodularity was present [Table/Fig-1]. There were no skin changes over the lump and no associated lymphadenopathy.



**[Table/Fig-1]:** Lump over left breast (upper Outer quadrant) and over left elbow joint (arrows).

All blood investigations, including complete blood count, renal function tests, and coagulation profile, were within normal limits. Ultrasonography (USG) of the left breast with Doppler revealed multiple small intercommunicating cystic areas measuring 3.3×0.7 cm in the outer upper quadrant of the left breast parenchyma. Venous Doppler of the left breast showed venolymphatic malformations in the

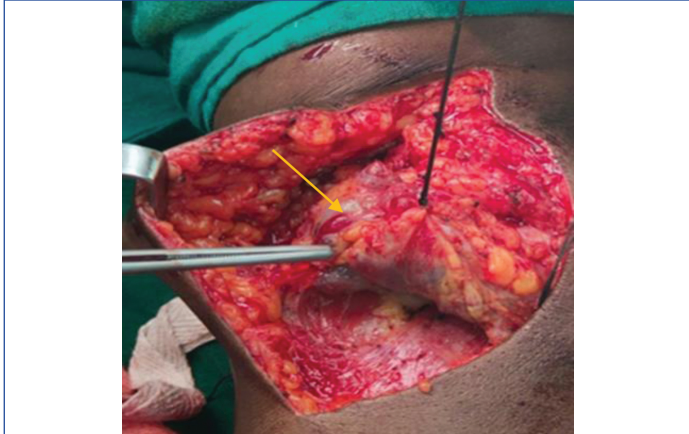
outer quadrants of the left breast and in the left lateral chest wall in the intermuscular planes. The left arm exhibited multiple hypoechoic tortuous lesions collectively measuring 5×4 cm, suggestive of slow-flow vascular/venolymphatic malformation. MRI of the left arm and left chest wall revealed ill-defined soft tissue intensity lesions in the anterolateral chest wall, extending to involve the latissimus dorsi and serratus anterior in the lateral thoracic wall, pectoralis major in the anterior chest wall beneath the left breast, extensor carpi radialis longus, extensor digitorum on the posterior aspect of the upper forearm, and supinator between the radius and ulna [Table/Fig-2]. Dilated cystic spaces with peripheral rim enhancement and lack of rim enhancement in the central portion were noted in the subcutaneous plane on the lateral aspect of the lower arm, elbow, and upper forearm, likely indicating thrombosis suggestive of a slow-flow vascular malformation predominantly venous and capillary. Fine Needle Aspiration Cytology (FNAC) was performed on the left breast lump and left elbow swelling, which suggested a cystic lesion as proteinaceous fluid with a few clusters of macrophages, degenerated epithelial cells, and a few lymphocytes were aspirated.



**[Table/Fig-2]:** MRI of left arm (orange arrow) and left breast showing ill-defined soft tissue intensity lesions.

Based on the presentation and imaging findings, the patient underwent surgery, during which the vascular malformation was identified in the subcutaneous plane. Excision of the swelling from the subcutaneous plane in the posterolateral aspect of the left elbow

was performed, along with ligation of multiple vascular and lymphatic channels going to deeper muscular planes near the elbow joint [Table/Fig-3]. Histopathological examination revealed fibroadipose tissue with multiple vessels of varying size and caliber arborising with each other. Thrombus formation was occasionally observed in the vessels, consistent with venolymphatic malformation. The patient was discharged on postoperative day 7. The left breast lump was managed conservatively for pain, and regular follow-up every three months has been advised.



**[Table/Fig-3]:** Intraoperatively, excision of vascular malformation over left arm (yellow arrow).

## DISCUSSION

Vascular malformations can involve veins, lymphatic vessels, or both, and in some cases, arteries and veins. These anomalies are present at birth but may become apparent at different ages. Vascular malformations is approximately apparent at different ages with the incidences of 0.3% to 0.5% [1]. Usually VMs are the most common type of congenital vascular malformation, with an incidence of one to two in 10,000, while venolymphatic malformations are unusual [1]. It is believed that vascular malformations result from developmental defects during embryogenesis, such as abnormalities in the signaling cascade that regulates vascular cell death, maturation, and proliferation. These defects lead to the persistence of vascular plexus cells with varying degrees of development [2]. The International Society for the Study of Vascular Anomalies (ISSVA) classifies vascular lesions as either haemangiomas or vascular malformations [3]. Vascular malformations are further classified based on the anatomical origin of the abnormal vessels, including Capillary Malformation (CM), VM, LM, and Arteriovenous Malformation (AVM). Capillary, venous, and lymphatic malformations are further divided into "slow flow," while arteriovenous malformations are classified as "fast flow" [4]. VMs present as congenital abnormalities with enlarged veins. Most cases are asymptomatic and may appear as a soft blue mass or patch anywhere on the body. The most common locations are the face, limbs, and trunk. VMs are characterised by slow blood flow.

The LMs are caused by abnormally expanded lymphatic vessels, which are formed by the dilated lymphatic channels or cysts lined with lymphatic endothelium [5]. Venolymphatic malformations occur due to dysplasia of lymphatic and venous vessel structures [6]. Approximately 50% of combined venolymphatic lesions commonly occur in the head and neck region [7]. LMs have a tendency to enlarge more than other VMs. The lymphatic component often enlarges more than the venous component in combined or complex vascular malformations. Excess fluid from tissues travels through lymphatic vessels and drains into the venous channel. However, this process is hindered in LMs due to slow flow, resulting in the pooling of lymphatic fluid in an enlarged area. Prolonged pooling of fluid can lead to infection, pain, skin leakage, or bleeding. Physical activity or prolonged dependent positions can also contribute to the enlargement of these malformations. Slow flow and the presence of

microthrombi can cause pain in the lesion, particularly upon waking in the morning [7].

The surgical treatment of LMs has limitations due to the infiltrative nature of LM. It is impossible to remove every endothelial cell during excision, and recurrence can occur in clumps of cells that are left behind, either early or after a long period of remission [2]. To reduce pain and functional impairment, the use of the squeezing technique, which involves compressing the mass by taking permanent sutures, is advocated. Percutaneous sclerotherapy is a gold standard modality used to diminish the volume of the malformation by causing damage to the endothelium, leading to inflammation and fibrosis [8]. Although absolute ethanol has the most severe local and systemic adverse effects, it is the most effective sclerotherapy agent with the lowest recurrence rate [9]. Tailored compression garments are used as the first line of treatment for symptomatic and severe venous abnormalities of the limbs to alleviate discomfort and reduce the risk of thrombosis. Most of the literature notes the occurrence of venous, lymphatic, or combined malformations in areas with rich lymphatics, such as the head and neck, axilla, mediastinum, intestine, heart, and lower extremities [10].

Venolymphatic malformations are produced by germline or somatic mutations in the TEK gene (chromosome 9p), which amplifies the endothelial cell tyrosine receptor TEK2. Phosphorylated TEK2 causes uncoupling between endothelial cells and hampers the formation of smooth muscles [10]. Endothelial cell hyperplasia causes vascular tumours to proliferate. On the other hand, vascular malformations have an inactive endothelium. Defects in vascular morphogenesis and remodeling locally are causative factors for vascular anomalies. VMs do not regress and continue to enlarge throughout life. Capillaro-lymphatic venous and capillary-VMs are combined vascular malformations that are slow-flow lesions involving both venous and lymphatic elements. Since it is an embryonic abnormality that presents at birth, muscles are rarely involved. They mainly involve the cutis and subcutis. These lesions grow with the child without regression or involution. Hormones, puberty, pregnancy, trauma, and infection can increase the size and deformity. They are locally invasive but benign in nature with a good prognosis [11].

The lesions in the index case involved very uncommon anatomical regions such as the breast and elbow region. Although, USG and Doppler have been useful, MRI has been shown to be the mainstay in diagnosing and delineating the full extent of the lesion. The diagnosis is confirmed by histopathology. Treatment depends on the size, location, symptoms, and proximity to vital structures. Steroids and beta-blockers may be used for capillary regression and inhibition of angiogenesis. Sclerosants, cryosurgery, laser, and embolisation are treatment methods, but surgical removal is usually the first choice [12].

## CONCLUSION(S)

Venolymphatic malformations are congenital anomalies with a very low incidence. They are rarely present over the chest wall and elbow regions. These lesions grow slowly throughout life and do not regress. MRI is the mainstay for diagnosis and determining the extent of the lesion. Excision is required if the lesion is impeding daily activities. The complex pathophysiology of mixed vascular lesions, which involve lymphatic and venous vessels, requires clinical and radiological knowledge for an adequate diagnosis, as well as management. Multidisciplinary team involvement remains key in the optimal management of patients.

## REFERENCES

- [1] Vikkula M, Boon LM, Mulliken JB. Molecular genetics of vascular malformations. *Matrix Biol.* 2001;20(5-6):327-35. Doi: 10.1016/s0945-053x(01)00150-0. PMID: 11566267.
- [2] Cohen Jr MM. Vascular update: Morphogenesis, tumours, malformations, and molecular dimensions. *Am J Med Genet A.* 2006;140(19):2013-38.

- [3] Fakhry N, Varoquaux A, Michel J, Giovanni A. Venolymphatic vascular malformation in the parapharyngeal space. *Otolaryngol Head Neck Surg.* 2012;147(4):796-98. Doi: 10.1177/0194599812442613. Epub 2012 Mar 23. PMID: 22447894.
- [4] Lowe LH, Marchant TC, Rivard DC, Scherbel AJ. Vascular malformations: Classification and terminology the radiologist needs to know. *Semin Roentgenol.* 2012;47(2):106-17. Doi: 10.1053/j.ro.2011.11.002. PMID: 22370189.
- [5] Wassef M, Blei F, Adams D, Alomari A, Baselga E, Berenstein A, et al. Vascular anomalies classification: Recommendations from the International society for the study of vascular anomalies. *Pediatrics.* 2015;136(1):e203-14. Doi: 10.1542/peds.2014-3673.
- [6] Kadota Y, Utsumi T, Kawamura T, Inoue M, Sawabata N, Minami M, et al. Lymphatic and venous malformation or "lymphangiohemangioma" of the anterior mediastinum: Case report and literature review. *Gen Thorac Cardiovasc Surg.* 2011;59(8):575-78.
- [7] Buckmiller LM, Richter GT, Suen JY. Diagnosis and management of hemangiomas and vascular malformations of the head and neck. *Oral Dis.* 2010;16(5):405-18.
- [8] Rosenblatt M. Endovascular management of venous malformations. *Phlebology.* 2007;22(6):264-75.
- [9] Ewing MJ, Zreik RT, Donner LR, Zehr KJ. Large lymphaticovenous malformation resection. *Interact Cardiovasc Thorac Surg.* 2013;17(1):205-06.
- [10] Soblet J, Limaye N, Uebelhoer M, Boon LM, Vikkula M. Variable somatic TIE2 mutations in half of sporadic venous malformations. *Mol Syndromol.* 2013;4(4):179-83.
- [11] Souza Junior EF, Sena DA, Lucena VR, Souza LB, Morais HH. Venolymphatic malformation in lateral edge of the tongue: Case report. *J Vasc Bras.* 2022;21:e20200113.
- [12] Li Y, Pang X, Yang H, Gao C, Peng B. Hemolymphangioma of the waist: A case report and review of the literature. *Oncol Lett.* 2015;9(6):2629-32.

**PARTICULARS OF CONTRIBUTORS:**

1. Professor and Head, Department of General Surgery, Dr. D. Y. Patil Medical College and Hospital, Pune, Maharashtra, India.
2. Associate Professor, Department of General Surgery, Dr. D. Y. Patil Medical College and Hospital, Pune, Maharashtra, India.
3. Postgraduate, Department of General Surgery, Dr. D. Y. Patil Medical College and Hospital, Pune, Maharashtra, India.
4. Postgraduate Resident, Department of General Surgery, Dr. D. Y. Patil Medical College and Hospital, Pune, Maharashtra, India.

**NAME, ADDRESS, E-MAIL ID OF THE CORRESPONDING AUTHOR:**

Dr. Vijetha Bandla,  
402, 2-2-21 to 23/A, Indu Residency, Baghamburpet,  
Hyderabad-500013, Telangana, India.  
E-mail: vijethabandla@gmail.com

**PLAGIARISM CHECKING METHODS:** [\[Jain H et al.\]](#)

- Plagiarism X-checker: Feb 06, 2023
- Manual Googling: May 23, 2023
- iThenticate Software: Jun 19, 2023 (7%)

**ETYMOLOGY:** Author Origin**EMENDATIONS:** 7**AUTHOR DECLARATION:**

- Financial or Other Competing Interests: None
- Was informed consent obtained from the subjects involved in the study? Yes
- For any images presented appropriate consent has been obtained from the subjects. Yes

Date of Submission: **Feb 03, 2023**Date of Peer Review: **Apr 11, 2023**Date of Acceptance: **Jun 20, 2023**Date of Publishing: **Jul 01, 2023**