

Acute Mesenteric Ischaemia: A Case Series

C ARUN BABU¹, T JEYALAKSMI², N SRIVIDHYA³

ABSTRACT

Acute Mesenteric Ischaemia (AMI) is a group of disorders characterised by a sudden occlusion of blood supply to varying portions of the small intestine, eventually progressing to ischaemia and peritonitis. The present case series highlights a total of seven cases, three of which are classified as acute superior mesenteric artery thrombosis and four as acute superiomesenteric vein thrombosis. The typically symptoms reported were sudden onset of abdominal pain, distension, and melena (a late finding). Among the seven cases, four patients who received early intervention had favourable outcomes. All patients presented late with peritonitis symptoms, except for one patient. Emergency laparotomy was performed on all patients, except for one who underwent diagnostic laparoscopy. Therefore, although abdominal pain is an uncommon symptom, physicians need to exercise a high level of diligence. If left untreated, the overall mortality rate consistently exceeds 70-90%. This case series emphasises the importance of timely diagnosis, early intervention, and immediate postoperative heparinisation, which significantly decrease morbidity and mortality.

Keywords: Abdominal pain, Melena, Superior mesenteric artery thrombosis

INTRODUCTION

Acute Mesenteric Ischaemia (AMI) is defined as an abrupt interruption of the blood supply to a segment of the small intestine, leading to ischaemia, cellular damage, intestinal necrosis, and eventual patient death, if left untreated [1]. Conventionally, AMI is classified as Non Occlusive Mesenteric Ischaemia (NOMI) or occlusive, with the primary aetiology further defined as mesenteric arterial embolism (50%), mesenteric arterial thrombosis (15%), or mesenteric venous thrombosis (5-15%) [1]. Intestinal viability is the most important factor that influences outcomes in AMI. Currently, emerging technologies have an edge of high resolution contrast-enhanced imaging in the arterial/ venous phase, which has a leverage in early diagnosis and management.

Despite the fact that various models have been designed to predict the course of AMI and prevent worse outcomes, mortality from AMI yet remains high. This series of cases vividly describes the plethora of presentations and intraoperative findings associated with various outcomes of AMI [Table/Fig-1].

CASE SERIES

Case 1: A 50-year-old male presented to the Emergency Department (ED) with abdominal pain, distension, vomiting (five episodes), and melena for two days. Upon admission the patient was haemodynamically stable. Clinically, the abdomen was distended with diffused tenderness and guarding. Without bowel sounds and blood-stained stools were noted on digital rectal examination. Contrast-enhanced Computed Tomography (CECT) abdomen revealed a thrombus in the superior mesenteric vein. Emergency laparotomy showed a gangrenous small bowel segment extending 30 cm from the Duodenojejunal (DJ) flexure to 15 cm proximal to the ileocecal (IC) junction [Table/Fig-2]. The gangrenous bowel segment was resected, and a proximal jejunostomy with distal ileal mucous fistula. Total parenteral nutrition and liquid diet was initiated on Postoperative Day (POD) 2. However, on POD 4, the patient deteriorated to renal failure and required haemodialysis. Total parenteral nutrition and nutritional supplements were used to manage postoperative short bowel syndrome and acid-base

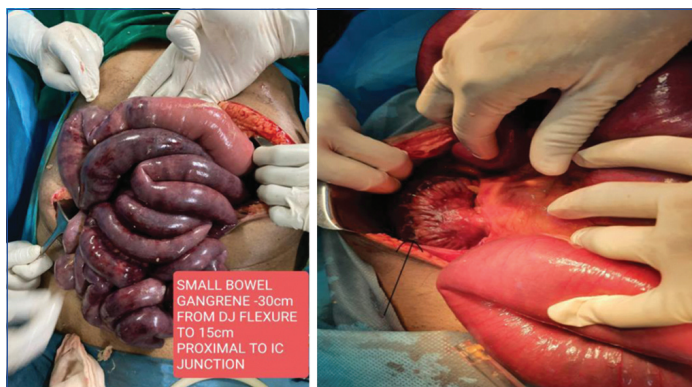
Parameters	Case 1	Case 2	Case 3	Case 4	Case 5	Case 6	Case 7
Age (years)/sex	50/male	45/male	50/male	62/male	45/male	50/male	65/female
Clinical presentation	Abdominal pain, vomiting and melena	Abdomen pain diarrhoea	Abdomen pain and melena	Abdomen pain, vomiting and melena	Diffuse abdominal pain	Abdomen pain and obstipation	Abdominal pain and diarrhoea
Co-morbidities	T2DM/CAD	-	-	-	CAD	PTB	SHTN/Hypothyroid
CECT abdomen	Thrombus in the SMV	Complete thrombotic occlusion of SMV	Complete thrombotic occlusion of SMV extending into portal vein and intrahepatic IVC	Thrombus noted in SMV for a length of 5.8 cm	70% occlusion of SMA with multiple collaterals	Complete occlusion of SMA at its origin	Complete occlusion of SMA and 70% occlusion of celiac artery
Intraoperative findings	Small bowel gangrene- 30 cm from DJ flexure to 15 cm proximal to IC junction	Massive bowel gangrene- 15 cm from DJ flexure to middle 3 rd of ascending colon	Small bowel gangrene- 15 cm from DJ flexure to 150 cm proximal to IC junction	Bowel was viable, multiple mesenteric lymph nodes noted	Pale small bowel loops-30 cm from DJ flexure to 200 cm proximal to IC junction	Small bowel gangrene- 30 cm from DJ flexure to 50 cm proximal to IC junction	Small bowel gangrene- 20 cm from DJ flexure to 50 cm proximal to IC junction
Complications	Short bowel syndrome, acute renal failure	Short bowel syndrome, MODS	Electrolyte imbalance, MODS	-	-	Short bowel syndrome	Burst abdomen, short bowel syndrome and MODS
Outcome	Ostomy reversal (jejunioileal anastomosis) done on POD 40, and discharged	Expired on POD 2	Expired on POD 6	Discharged on POD 14	Discharged on POD 8	Ostomy reversal (jejunioileal anastomosis) was done on POD 54 and discharged	Expired on POD 7

[Table/Fig-1]: Clinical presentation, management, and outcome of cases with AMI.

T2DM: Type 2 diabetes mellitus; CAD: Coronary artery disease; PTB: Pulmonary tuberculosis; SHTN: Sustained hypertension; SMV: Superior mesenteric vein; IVC: Inferior vena cava; SMA: Superior mesenteric artery; DJ: Duodenojejunal; IC: Ileocecal; POD: Postoperative day; MODS: Multiple organ dysfunction syndrome

imbalance. Jejunioileal anastomosis was performed on POD 40, and the patient was discharged on POD 50 with oral anticoagulants.

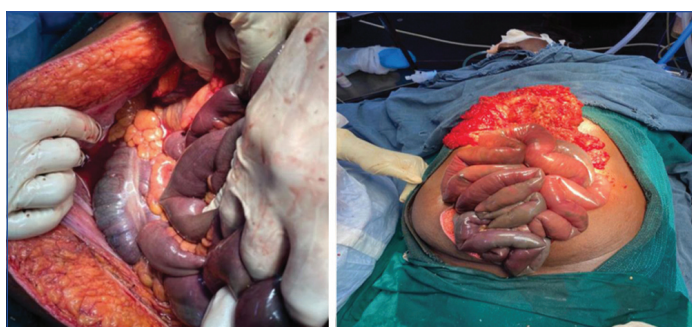Case 2: A 45-year-old male, chronic alcoholic and smoker, presented with vague, diffuse abdominal pain and diarrhoea for past two days. On clinical examination, abdomen was distended, tense and rigid. The patient was haemodynamically unstable. Initial resuscitation with crystalloids and inotropes was initiated. Emergency laparotomy showed massive gangrenous bowel loops extending 15 cm from the DJ flexure to the middle 1/3rd of the ascending colon [Table/Fig-3,4]. The gangrenous segment was resected, and a proximal jejunostomy with distal transverse colostomy was performed. However, due to sepsis and haemodynamic instability, the patient required mechanical ventilation. Unfortunately, the patient succumbed to multiorgan dysfunction syndrome on day 2.



[Table/Fig-2]: Small bowel gangrene.

[Table/Fig-3]: Gangrene of the ascending colon. (Images from left to right)

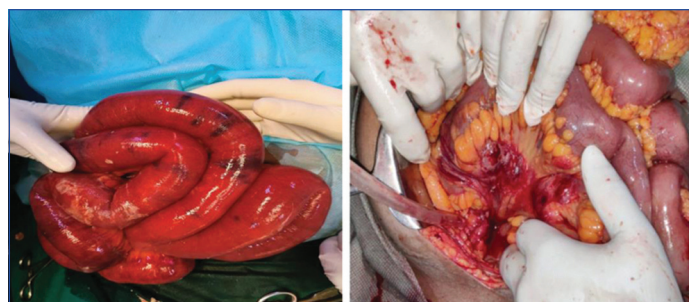
Case 3: A 50-year-old male chronic alcoholic, presented with abdominal pain and melena for past two days. Clinically, he was icteric, with an abdominal finding of splenomegaly, and diffuse tenderness and guarding. Laboratory parameters showed leucocytosis with elevated serum total and direct bilirubin levels of 8 mg/dL and 4 mg/dL, respectively. CECT abdomen revealed mesenteric haziness with complete occlusion of the superior mesenteric vein by a thrombus extending into the portal vein and intrahepatic inferior vena cava. Emergency laparotomy showed gangrenous bowel loops extending 15 cm distal to the DJ flexure up to 150 cm from the IC junction [Table/Fig-5,6]. On POD 5, the patient developed electrolyte imbalance with Multiple Organ Dysfunction Syndrome (MODS) and died on POD 6.



[Table/Fig-4]: Gangrene of the ascending colon.

[Table/Fig-5]: Small bowel gangrene. (Images from left to right)

Case 4: A 62-year-old male presented with abdominal pain for 10 days, along with vomiting and melena. Laboratory parameters showed leucocytosis and elevated serum total and direct bilirubin levels of 6 mg/dL and 3 mg/dL, respectively. CECT abdomen revealed a partial thickness thrombus in the superior mesenteric vein, extending 5.8 cm into one of its branches and causing complete occlusion. A corresponding short segment of ileal loops (10 cm) showed no enhancement, along with surrounding mesenteric haziness and features of a liver abscess. Intraoperatively, multiple enlarged necrotic mesenteric lymph nodes were noted [Table/Fig-7]. The bowel was viable, and tissue nodal biopsy showed non specific



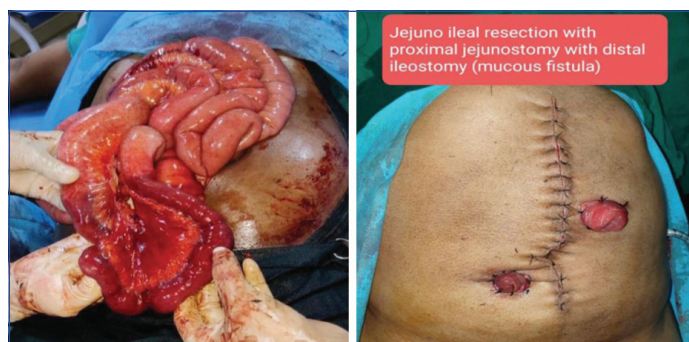[Table/Fig-6]: Patchy small bowel gangrene.

[Table/Fig-7]: Mesenteric node abscess. (Images from left to right)

inflammation without evidence of malignancy or tuberculosis. The patient was discharged on POD 14.

Case 5: A 45-year-old male, a chronic smoker, presented with abdominal pain lasting for one day. On examination, the abdomen was soft with diffused tenderness. Due to the disproportionate abdominal pain to clinical findings, a CECT abdomen was performed, which revealed 70% occlusion of the superior mesenteric artery with multiple collaterals. Emergency diagnostic laparoscopy showed pale small bowel loops extending proximally 30 cm from the DJ flexure to 200 cm proximal to the IC junction.

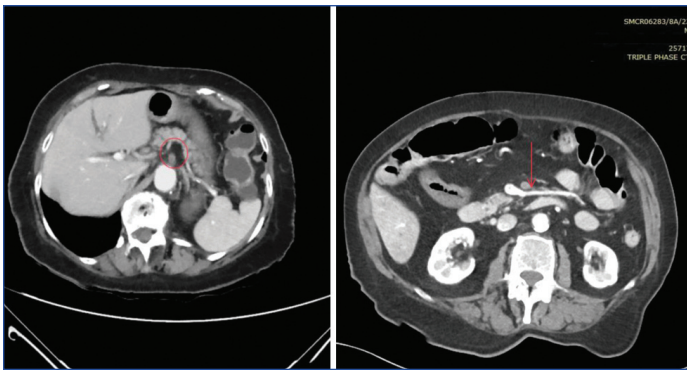
Case 6: A 50-year-old male presented with abdominal pain and obstipation for the past two days. Urgent CECT abdomen revealed mesenteric haziness, free fluid, and complete occlusion of the superior mesenteric artery at its origin. Emergency laparotomy showed a gangrenous small bowel segment extending 30 cm from the DJ flexure to 50 cm proximal to the IC junction. The gangrenous segment was resected, and a proximal jejunostomy with distal ileal mucous fistula was started. Intravenous anticoagulants were initiated, and oral medications started on POD 2. Postoperatively, the patient developed short bowel syndrome with electrolyte imbalance, which was managed with total parenteral nutrition and nutritional supplements. Jejunioileal anastomosis was performed on POD 54 [Table/Fig-8,9]. The patient recovered with oral anticoagulants.



[Table/Fig-8]: Small bowel gangrene.

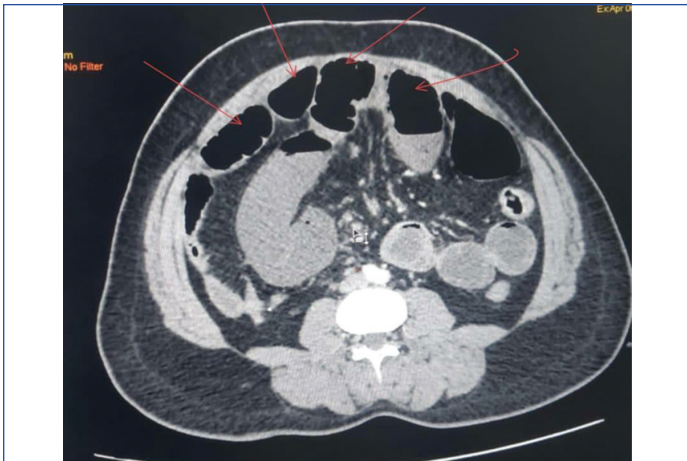
[Table/Fig-9]: Jejunostomy with mucous fistula. (Images from left to right)

Case 7: A 65-year-old female presented with abdominal pain and diarrhoea for past two days and initially was admitted to the medicine ED. Emergency CECT abdomen revealed complete occlusion of the superior mesenteric artery and 70% occlusion of the celiac artery, with fluid-filled bowel wall and dilated bowel loops were observed [Table/Fig-10-12]. Emergency laparotomy was performed, revealing a gangrenous small bowel segment extending 20 cm from the DJ flexure up to 50 cm proximal to the IC junction. Resection of the gangrenous small bowel segment was done, along with the creation of a proximal jejunostomy and distal ileal mucous fistula. On POD 4, she developed a burst abdomen and underwent emergency relaparotomy. It was found that gangrene had further progressed proximally in the jejunum, and there was also gangrenous discoloration in the gallbladder and cystic duct. The gangrenous segment was resected, and a proximal tube jejunostomy, tube cholecystostomy, and distal mucous fistula were created. Unfortunately, the patient expired on POD 7 due to severe sepsis and MODS.



[Table/Fig-10]: CECT abdomen showing SMA thrombosis.

[Table/Fig-11]: CECT abdomen showing portal vein thrombosis. (Images from left to right)



[Table/Fig-12]: CECT abdomen showing fluid filled bowel wall and dilated bowel loops.

DISCUSSION

Typically occurrence of AMI is considered as a disease of the elderly in Western nations with an average diagnosis age of 65 years, is being diagnosed at least a decade earlier in the Indian population [2,3]. The present study represents, the average age of diagnosis was 52 years, significantly younger than the Western population. While SMA disease is more commonly encountered than SMV disease, the present case series is predominantly characterised by SMV thrombosis [4]. Proximal occlusion leads to extensive bowel necrosis, whereas distal disease is often associated with patchy intestinal necrosis. Similarly, complete occlusion is linked to increased morbidity and mortality, while partial occlusion or occlusion with collaterals is associated with milder disease. Among the seven patients in the present case series, only two had viable bowel, while the remaining five experienced extensive bowel gangrene. Three patients who underwent extensive bowel resections succumbed to death due to various factors, while the survivors experienced short gut syndrome and required immediate bowel anastomosis to establish intestinal continuity. AMI presents with a wide spectrum of symptoms, ranging from non specific abdominal pain to signs of diffuse peritonitis. Unfortunately, most patients are identified after the critical period due to paucity of abdominal signs, as observed in the present study [5]. The patients in the present study, who presented late with guarding and rigidity could not be successfully resuscitated, while those with non specific symptoms had a better prognosis. Therefore, a high index of suspicion is crucial for early diagnosis and prevention of mortality. While the prognosis in AMI is influenced by multiple factors, and multivariate analysis in previous studies has identified leucocytosis, elevated lactate, bilirubin, and creatinine as independent predictors of mortality [6]. In the current case series, the association of leucocytosis and hyperbilirubinemia increased the morbidity rate but was not significantly associated with mortality. Overall, the mortality rate associated with AMI is

high, with certain literature studies reporting over 50% [7,8]. In the present case series patient group, three out of seven patients died (42%) as a result of sepsis-induced MODS. Several studies have highlighted the relationship between smoking and alcoholism, with some suggesting a causal relationship and others demonstrating a synergistic relationship [9]. Nicotine smoke has various toxic substances which is considered as one of the aetiological factors for AMI [10]. In the present study, three patients reported a history of smoking or alcoholism, and two of them died due to MODS. The direct role of these addictive habits in mortality is yet to be determined. Anticoagulation therapy plays a critical role in patients presenting with intestinal necrosis, as surgical revascularisation procedures may not be feasible [11]. All patients in the current case series were initiated with intravenous unfractionated heparin initially, and those who were discharged continued oral warfarin therapy with close monitoring of prothrombin time. We ruled out Coronavirus Disease 2019 (COVID-19) infection and COVID-19-associated pneumonia as rare causes of mesenteric thromboembolism leading to bowel gangrene, as all the present study patients tested negative for COVID-19 and had no history of COVID-19 vaccination [12]. CT angiography is considered the gold standard for diagnosing AMI, with a sensitivity of 0.96 and specificity of 0.94 [13]. Different endovascular revascularisation techniques, combined with pharmacological agents, have gained popularity in recent years [14,15]. However, these techniques are contraindicated in cases of bowel ischaemia and infarction. The choice of permanent maintenance nutrition treatment should be determined on an individual basis. Long-term total parenteral nutrition plays a significant role in determining the prognosis and survival of the patient. Small bowel transplantation is an option for cases of long-term parenteral nutrition and short bowel syndrome, but it carries a higher risk of graft rejection due to increased immunogenicity and infection compared to solid organ transplantation [4].

CONCLUSION(S)

As AMI frequently affects the elderly population, physicians need to be aware and cautious of the possibility of this condition, even with mild sudden onset of abdominal pain. The diagnosis of AMI is challenging and often delayed, leading to irreversible bowel ischaemia which necessitates emergency surgery. CECT of the abdomen is the frontrunner for early diagnosis and appropriate management. Mortality and morbidity rates for AMI remain high, and the survival rate is low in cases requiring extensive bowel resection.

Acknowledgement

The authors express their heartfelt thanks to Dr. Bhavik Rajesh Shah for the help and support evinced to complete the present study.

REFERENCES

- [1] Klar E, Rahmanian PB, Bucker A, Hauenstein K, Jauch KW, Luther B. Acute mesenteric ischemia: A vascular emergency. *Dtsch Arztebl Int.* 2012;109(14):249-56. Doi: 10.3238/arztebl.2012.0249. Epub 2012 Apr 6. PMID: 22536301; PMCID: PMC3336145.
- [2] Jagielski M, Piątkowski J, Jackowski M. Challenges encountered during the treatment of acute mesenteric ischemia. *Gastroenterol Res Pract.* 2020;31:2020:5316849.
- [3] Nagaraja R, Rao P, Kumaran V, Yadav A, Kapoor S, Varma V, et al. Acute mesenteric ischaemia-an Indian perspective. *Indian J Surg.* 2015;77(Suppl 3):843-49.
- [4] Bala M, Kashuk J, Moore EE, Kluger Y, Biffl W, Gomes CA, et al. Acute mesenteric ischemia: Guidelines of the World Society of Emergency Surgery. *World J Emerg Surg.* 2017;12:38. Doi: 10.1186/s13017-017-0150-5. PMID: 28794797; PMCID: PMC5545843.
- [5] Martin J, Depietro R, Bartoli A, Markarian T, De Maria L, Di Bisceglie M, et al. Acute mesenteric ischemia: Which predictive factors of delayed diagnosis at emergency unit? *Eur J Trauma Emerg Surg.* 2023;49(5):1999-2008. Epub 2022 Sep 21.
- [6] Treskes N, Persoon AM, van Zanten ARH. Diagnostic accuracy of novel serological biomarkers to detect acute mesenteric ischemia: A systematic review and meta-analysis. *Intern Emerg Med.* 2017;12(6):821-36. Doi: 10.1007/s11739-017-1668-y. Epub 2017 May 6. PMID: 28478489; PMCID: PMC5559578.

- [7] Otto CC, Czigan Z, Heise D, Bruners P, Kotelis D, Lang SA, et al. Prognostic factors for mortality in acute mesenteric ischemia. *J Clin Med*. 2022;11(13):3619.
- [8] Reintam Blaser A, Forbes A, Björck M. Acute mesenteric ischaemia. *Curr Opin Crit Care*. 2022;28(6):702-08.
- [9] Wei CW, Wang YC, Hung DZ, Chung YT, Chen WK, Kao CH. Increased risk of mesenteric ischemia in patients with alcohol use disorder: A population-based retrospective cohort study. *Mayo Clin Proc*. 2016;91(2):189-95. Doi: 10.1016/j.mayocp.2015.09.023. Epub 2015 Dec 24. PMID: 26725146.
- [10] Severinsen MT, Kristensen SR, Johnsen SP, Dethlefsen C, Tjønneland A, Overvad K. Smoking and venous thromboembolism: A Danish follow-up study. *J Thromb Haemost*. 2009;7(8):1297-303.
- [11] Moiz B, Muslim Z, Siddiqui ZF, Zafar H. Acute mesenteric thrombosis: A hematologist perspective. *Clin Appl Thromb*. 2020;26:1076029620932999.
- [12] Nada A, Shabana A, Elsaadany A, Abdelrahman A, Gaballah AH. Superior mesenteric artery thrombosis and small bowel necrosis: An uncommon thromboembolic manifestation in COVID-19 pneumonia. *Radiol Case Rep*. 2022;17(3):821-24.
- [13] Kanasaki S, Furukawa A, Fumoto K, Hamanaka Y, Ota S, Hirose T, et al. Acute mesenteric ischemia: Multidetector CT findings and endovascular management. *Radiographics*. 2018;38(3):945-61. Doi: 10.1148/rg.2018170163. PMID: 29757725.
- [14] Liao G, Chen S, Cao H, Wang W, Gao Q. Review: Acute superior mesenteric artery embolism: A vascular emergency cannot be ignored by physicians. *Medicine (Baltimore)*. 2019;98(6):e14446. Doi: 10.1097/MD.00000000000014446. PMID: 30732209; PMCID: PMC6380707.
- [15] Singh M, Long B, Koyfman A. Mesenteric ischemia: A deadly miss. *Emerg Med Clin North Am*. 2017;35(4):879-88. Doi: 10.1016/j.emc.2017.07.005. PMID: 28987434.

PARTICULARS OF CONTRIBUTORS:

1. Associate Professor, Department of General Surgery, Government Stanley Medical College and Hospital, Chennai, Tamil Nadu, India.
2. Assistant Professor, Department of General Surgery, Government Stanley Medical College and Hospital, Chennai, Tamil Nadu, India.
3. Assistant Professor, Department of General Surgery, Government Stanley Medical College and Hospital, Chennai, Tamil Nadu, India.

NAME, ADDRESS, E-MAIL ID OF THE CORRESPONDING AUTHOR:

Dr. T Jeyalaksmi,
157/4, Golden Jubilee Flats, Padikuppam Road, Anna Nagar West,
Chennai-600001, Tamil Nadu, India.
E-mail: jeyatr@gmail.com

AUTHOR DECLARATION:

- Financial or Other Competing Interests: None
- Was informed consent obtained from the subjects involved in the study? Yes
- For any images presented appropriate consent has been obtained from the subjects. Yes

PLAGIARISM CHECKING METHODS: [Jain H et al.]

- Plagiarism X-checker: Apr 20, 2023
- Manual Googling: May 09, 2023
- iThenticate Software: Jun 15, 2023 (7%)

ETYMOLOGY: Author Origin**EMENDATIONS:** 8Date of Submission: **Apr 19, 2023**Date of Peer Review: **May 08, 2023**Date of Acceptance: **Jun 18, 2023**Date of Publishing: **Aug 01, 2023**