

Skene's Duct Cyst in an Elderly Female: A Case Report

ANJI REDDY KALLAM¹, GUDELI VAHINI²

(CC) BY-NC-ND

ABSTRACT

Paraurethral glands and ducts are the rudimentary female homologues of the prostate, which empty into the vaginal vestibule near the urethral meatus. The two largest ducts are referred to as Skene's ducts. Skene's duct cysts are rare across all age groups and are only noticed when they cause complications such as dysuria. The causes of Skene's duct cysts include duct obstruction due to infection, inflammation, or cystic degeneration of embryonic remnants of the paraurethral glands. In this case report, the authors present the findings of a 50-year-old female who had a painless swelling in the left labial region for a duration of three years. Upon local examination, a pedunculated swelling measuring 6x2.8 cm was observed in the left labia minora. The entire swelling, including the pedicle, was excised under regional anaesthesia through a vertical elliptical incision. Histopathological examination confirmed the diagnosis, and the patient experienced complete satisfaction and relief from her symptoms.

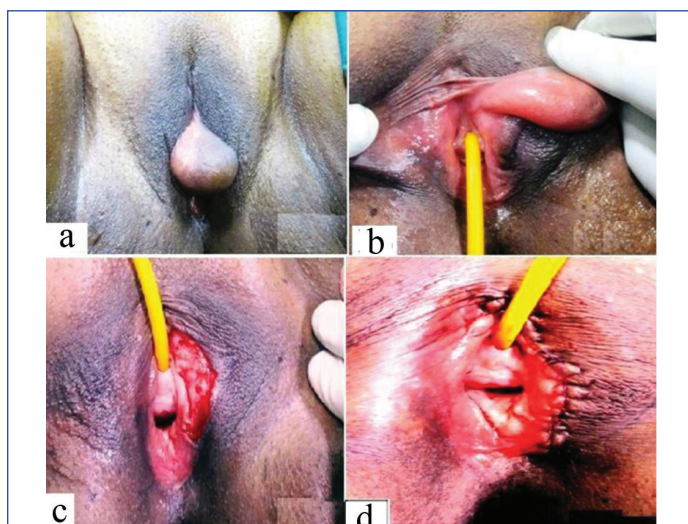
Keywords: Embryonic remnants, Paraurethral glands, Periurethral cyst

CASE REPORT

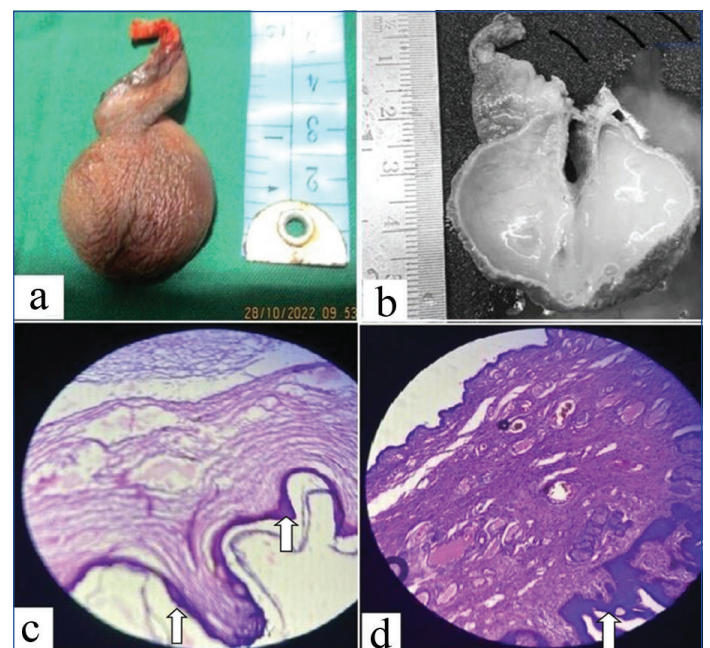
A 50-year-old female presented to the Department of Plastic Surgery at a Tertiary Care Hospital with a complaint of a painless swelling in the left labial region that had been present for three years. The swelling had gradually increased in size. Apart from the swelling, she had no other complaints. She had a history of well-controlled diabetes mellitus. Upon local examination, a pedunculated swelling measuring 6x2.8 cm was observed in the left labia minora. The pedicle of the swelling was located to the left of the external urethral meatus, and the swelling extended down to the vulvar fourchette inferiorly along the labia minora. The swelling was covered by labial mucosa and was situated in the submucosal plane. It had a well-demarcated, smooth surface, was transparent, and had a uniformly firm consistency. The urethral opening and vaginal orifice appeared normal. The cystic swelling measured 3x2x2 cm [Table/Fig-1a], and the cyst was excised in its entirety with a pedicle on the left side of the external urethral meatus [Table/Fig-1b]. The patient was admitted after undergoing regular investigations and underwent surgery the following day under regional anaesthesia.

The entire swelling, including the pedicle, was excised under regional anaesthesia by performing a vertical elliptical incision after

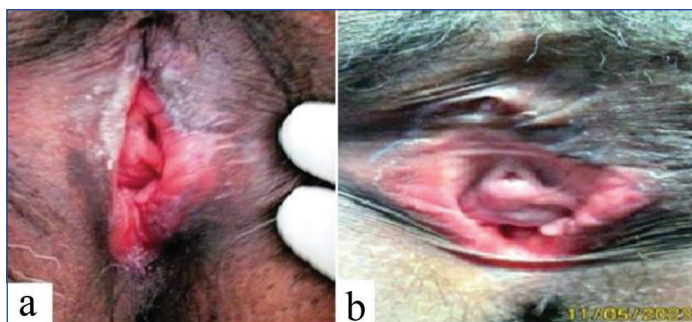
complete exposure of the cyst and its pedicle at the level of the external urethral meatus towards the left side. The wound in the labia minora was closed using 3/0 vicryl sutures. An indwelling Foley catheter was inserted for urinary drainage [Table/Fig-1c,d]. A grey-brown, pedunculated mass measuring 5x2.8x1.5 cm [Table/Fig-2a] was received for histopathological examination. The cut section revealed a cyst measuring 3x2x1 cm, filled with white, transparent jelly-like material [Table/Fig-2b]. Microscopic examination showed a stratified squamous epithelial lining with subepithelial fibrous stroma, sebaceous glands, a few congested dilated blood vessels, and a cyst wall partially lined by stratified ciliated columnar epithelium. The histological findings were consistent with Skene's duct cyst [Table/Fig-2c,d]. The postoperative period was uneventful, and the patient was discharged on the 3rd postoperative day after the removal of the Foley catheter. The patient returned for a follow-up visit after two months of discharge and was doing well without any problems [Table/Fig-3a,b].



[Table/Fig-1]: a) Swelling presenting out through vulvar outlet, b) Cystic swelling is seen in the left periurethral region, c) Perioperative area after the complete excision of the cyst, d) Perioperative area after the mucosal defect's repair in the left labia minora region.



[Table/Fig-2]: a) Gross examination shows a grey-brown pedunculated mass, b) Cut section shows a cyst filled with white jelly like material, c) Microscopic examination in Hematoxylin and Eosin (H&E) stained section, x10 magnification showed cyst lined by stratified squamous epithelium with subepithelial fibrous stroma, also partly by ciliated columnar lining, d) Microscopic examination showed a cyst lined by stratified squamous epithelium.



[Table/Fig-3a,b]: Follow-up after two months.

DISCUSSION

Skene's gland cysts are rare, especially in adults, and one possible cause is duct obstruction due to infection [1,2]. However, there were no evident signs of infection in the patient described in this case. In this particular case, a middle-aged female patient presented with a painless swelling in the labial region that had been present for three years. The swelling was excised and confirmed as a Skene's duct cyst on histopathological examination. Excision of Skene's duct cyst is the main surgical protocol followed in paediatric patients [3-6]. These cysts consist of numerous small glands located in the lamina propria of the lower third of the female urethra [7,8]. They have common ducts that open on the lateral aspect of the external urethral orifice and secrete mucoid material, which lubricates the urethral meatus [9,10].

Differential diagnoses for a mass of Skene's origin include solid tumours such as villous adenoma, malignant tumours of the prostate (of which Skene's glands are a homologue), and Skene's abscess of gonococcal origin [8,9]. According to the criteria proposed by Das, paraurethral cysts can be classified into four groups: epithelial inclusion, Mullerian, Gartner duct, hymenal cysts, and Skene's duct cysts, which are cystic dilations of the Wolffian duct remnant located in the anterolateral wall of the vagina and typically present as an interlabial mass [7]. Other differential diagnoses include urethral diverticulum, ectopic ureterocele, and cystocele [11-13]. Pathological examination would reveal a transitional, squamous, or columnar epithelium [14].

A comprehensive urogenital evaluation, including a thorough physical examination, radiological imaging, and endoscopic examination, is necessary to rule out differential diagnoses before surgery. However, in this particular case, the diagnosis was evident, and the patient had no other complaints, so unnecessary investigations were avoided. Various therapeutic options are available, such as needle aspiration, marsupialisation, partial excision, unroofing, and ablation [8]. Due to the small size of the cyst in this case, excision was performed. In children with very small congenital cysts, needle aspiration is a more common technique, while all these techniques have been described for adults with good results, although they have only been tested in a few cases [2,14-17]. In men, there is increased production of sex hormones in various pathological conditions such as prostate cancer

and benign prostatic hyperplasia. Although there are no reports on the relationship between Skene's gland cysts and sex hormones, a recent study has focused on the similarity between Skene's adenocarcinoma (an uncommon malignant tumour derived from Skene's gland) and prostate cancer [18,19].

CONCLUSION(S)

Skene's gland cyst, also known as Skene's duct cyst, is a benign cystic swelling that arises from the Skene's gland or paraurethral glands located beside the external urethral opening in females. It occurs due to blockage of the duct and may cause symptoms such as dysuria or dyspareunia. Complete excision of the cyst is the preferred method of treatment. In cases where there are difficulties, marsupialisation of the cyst (deroofing and peripheral suturing) can be considered as an alternative method of treatment for the cyst.

REFERENCES

- [1] Shin T, Sato R, Shibuya T, Ando T, Mimata H. Adult-onset Skene's gland cyst following a history of multiple gynecological treatment interventions. *Urol Case Rep.* 2021;36:101586. Doi: 10.1016/j.eur.2021.101586. PMID: 33552920; PMID: PMC7856313.
- [2] Yayla D, Demitas G, Tagcı S, Karabulut B, Tiryaki HT. Para urethral Skene's cyst case in puberty. *Journal of Pediatric Surgery Case Reports.* 2021;68:101788.
- [3] Foster J, Lemack G, Zimmern P. Skene's gland cyst excision. *Int Urogynecol J.* 2016;27(5):817-20.
- [4] Fathi K, Pinter A. Paraurethral cysts in female neonates. *Case reports. Acta Paediatr.* 2003;92(6):758-59.
- [5] Lucioni A, Rapp DE, Gong EM, Fedunok P, Bales GT. Diagnosis and management of periurethral cysts. *Urol Int.* 2007;78(2):121-25.
- [6] Johnson CT, Millard SE, Wang MH. Prenatal diagnosis of a paraurethral cyst. *J Pediatr Urol.* 2013;9(1):e91-93.
- [7] Nickles SW, Burgis JT, Menon S, Bacon JL. Prepubertal Skene's abscess. *J Pediatr Adolesc Gynecol.* 2009;22(1):e21-22.
- [8] Moralioğlu S, Bosnalı O, Celayı AC, Şahin C. Paraurethral Skene's duct cyst in a newborn. *Urol Ann.* 2013;5(3):204-05.
- [9] Ishigooka M, Hayami S, Hashimoto T, Tomaru M, Yaguchi H, Sasagawa I, et al. Skene's duct cyst in adult women: Report of 2 cases. *Int Urol Nephrol.* 1995;27:775-78.
- [10] Miller EV. Skene's duct cyst. *J Urol.* 1984;131(5):966-67.
- [11] SAMI, Rodeigues AJ, Ferreira L. Fetal vulvar cysts with spontaneous resolution. *BMJ Case Rep.* 2014;2014PIL:bor2014206180.
- [12] Busto Martin L, Barguti I, Andraca AZ, IR Gómez, LB Castañón. Cyst of the skene's gland; report of four cases and bibliographic review. *Arch Esp Urol.* 2010;63(3):238-42.
- [13] Taeng MH, Lin SH. Inter labial mass in a neonate with paraurethral cyst. *World J Pediatr.* 2016;12(1):121.
- [14] Mino A, Rodriguez J. Skene duct cyst in female new borns-case reports. *Rev Chil Pediatr.* 2014;85(5):584-87.
- [15] Costantino E, Ganesan GS. Skene's gland cyst as an inter labial mass in a new born girl. *BMJ Case Rep.* 2016;2016pii:her2016215042.
- [16] Kalinderi K, Kalinderis M, Linos K, Salpigidis G, Papanikolaou E, Chalkidou M, et al. Highlighting the importance of multidisciplinary approach: A rare case of primary periurethral poorly differentiated carcinoma. *Taiwan J Obstet Gynecol.* 2020;59(1):150-53. Doi: 10.1016/j.tjog.2019.11.025.
- [17] Nakamura E, Shintaku S, Horii M, H Manabe, Y Hirano, K Muro. Early regression of paraurethral cyst in a neonate. *Pediatr Neonatol.* 2014;55(3):225-27.
- [18] Kaufman ME, Miller DT, Ullah A, White J, Singh G, Kolhe R, et al. Skene's gland adenocarcinoma: Borrowing from prostate cancer experience for the evaluation and management of a rare malignancy. *Urology.* 2021;151:182-87. Doi: 10.1016/j.urol.2020.05.032. Epub 2020 Jun 3.
- [19] Trenango AC, Epstein J. Skene's glands Adenocarcinoma: A series of 4 cases. *AM J Surg Pathol.* 2018;42(11):1513-21.

PARTICULARS OF CONTRIBUTORS:

1. Medical Director, Department of Plastic Surgery, Asram Medical College and Hospital, Eluru, Andhra Pradesh, India.
2. Professor, Department of Pathology, Asram Medical College and Hospital, Eluru, Andhra Pradesh, India.

NAME, ADDRESS, E-MAIL ID OF THE CORRESPONDING AUTHOR:

Dr. Anji Reddy Kallam,
Medical Director, Department of Plastic Surgery, Asram Medical College and Hospital,
Eluru, West Godavari District-534005, Andhra Pradesh, India.
E-mail: reddykanji@gmail.com

AUTHOR DECLARATION:

- Financial or Other Competing Interests: None
- Was informed consent obtained from the subjects involved in the study? NA
- For any images presented appropriate consent has been obtained from the subjects. Yes

PLAGIARISM CHECKING METHODS: [Jan H et al.]

- Plagiarism X-checker: Nov 26, 2022
- Manual Googling: May 18, 2023
- iThenticate Software: Jun 03, 2023 (15%)

ETYMOLOGY: Author Origin

EMENDATIONS: 6

Date of Submission: **Nov 23, 2022**
Date of Peer Review: **Mar 22, 2023**
Date of Acceptance: **Jun 05, 2023**
Date of Publishing: **Aug 01, 2023**