

# A Combination of Ultrasound-guided Popliteal Sciatic Nerve Block and Adductor Canal Block as a Sole Anaesthetic Technique for below Knee Amputation in High-risk Patients: A Case Series

MK SANDHYA<sup>1</sup>, SAMBHRAM SHENOY<sup>2</sup>, SUDHAM RAMESH SHETTY<sup>3</sup>, ADIRAJU CHANAKYA<sup>4</sup>

## ABSTRACT

Below-knee amputation in high-risk patients is associated with significant mortality and morbidity. Spinal anaesthesia is linked to an increased incidence of hypotension and bradycardia, and it is relatively contraindicated in patients with coagulation abnormalities. General anaesthesia is used as an alternative when spinal anaesthesia is contraindicated, but it is associated with a considerable increase in perioperative morbidity and the need for postoperative ventilatory support and Intensive Care Unit (ICU) care. A combination of sciatic nerve block and femoral block has been employed for below-knee surgeries as it provides complete anaesthesia below the knee. Adductor canal block, compared to femoral nerve block, is motor-sparing and, when combined with popliteal sciatic nerve block, offers complete anaesthesia below the knee. Below-knee amputation requires complete motor and sensory blockage, making regional block for below-knee amputation more challenging for the anaesthesiologist. Present case series is of five cases of below-knee amputation performed under a combination of ultrasound-guided popliteal sciatic nerve block and adductor canal block. Ultrasound-guided popliteal sciatic nerve block was administered with a combination of 10 mL of bupivacaine 0.5% and 5 mL of lignocaine 2% with adrenaline (1:200,000) diluted with 5 mL of distilled water to a total volume of 20 mL. Ultrasound-guided adductor canal block was performed with 8 mL of bupivacaine 0.5% and 4 mL of lignocaine 2% with adrenaline (1:200,000), diluted with 4 mL of distilled water to a total volume of 16 mL. All patients achieved adequate surgical anaesthesia, and none experienced any anaesthesia-related complications.

**Keywords:** Regional nerve block, Saphenous nerve block, Subsartorial block

## INTRODUCTION

A combination of femoral and sciatic nerve block has been employed as an anaesthetic technique for below-knee surgeries. The sciatic nerve is blocked at the popliteal region, providing anaesthesia below the knee joint, except for the medial aspect of the leg. Adductor canal block is used to block the terminal branches of the femoral nerve and has been utilised to provide analgesia for knee surgeries. It has also been used in combination with popliteal sciatic nerve block to provide analgesia and complete anaesthesia for below-knee surgeries [1-3]. Present case series is of five below-knee amputation cases performed using a combination of adductor canal block and popliteal sciatic nerve block [Table/Fig-1].

## CASE SERIES

### Case-1

A 57-year-old female patient was scheduled for a right below-knee amputation due to right diabetic foot gangrene. The patient had a medical history of coronary artery disease for five years, diabetes

for five years (treated with insulin), and hypertension for five years. The patient was on amlodipine 5 mg, a combination of losartan/hydrochlorothiazide, and rosuvastatin 10 mg at night. The patient was also taking aspirin 150 mg and clopidogrel 75 mg, which were discontinued before two days. The patient's vital signs were stable, and a systemic examination revealed no abnormalities. The investigation reports were as follows: haemoglobin level was 9.6 gm%, total leukocyte count was 14,100 cells/mm<sup>3</sup>. Renal function tests were normal. An Electrocardiography (ECG) showed T-wave inversion in the lateral leads. An Echocardiogram (ECHO) showed left ventricular hypertrophy, an ejection fraction of 35%, Grade-I diastolic dysfunction, and regional wall motion abnormality in the left anterior descending artery territory. The patient was instructed to be Nil Per Oral (NPO) and posted for surgery under American Society of Anaesthesiologists (ASA) III risk.

### Case-2

A 60-year-old male patient presented with left diabetic foot with gangrene and sepsis, requiring emergency left below-knee

Parameters	Case-1	Case-2	Case-3	Case-4	Case-5
Age (years)	57	60	58	76	66
Gender (M/F)	F	M	M	F	M
Diagnosis	Diabetic foot gangrene, Right leg (R)	Diabetic foot gangrene with sepsis, Left leg (L)	Diabetic foot gangrene (L)	Diabetic foot gangrene with peripheral vascular disease (R)	Diabetic foot (R)
Co-morbid conditions	Diabetes for five years, Hypertension for five years, Coronary artery disease for five years	Diabetes for 15 years, Acute on CKD	Diabetes for 21 years, CKD	Diabetes for 30 years, Hypertension for 30 years	Diabetes for 25 years, CKD for 4 years

Medications/treatment for co-morbid conditions	Insulin, Amlodipine 5 mg Losartan hydrochlorothiazide combination, Rosuvastatin 10 mg, Aspirin 150 mg Clopidogrel 75 mg	Insulin, On conservative management for CKD	Insulin, On dialysis for CKD	Amlodipine 5 mg	Insulin for diabetes, Conservative management for CKD
Relevant physical examination findings	P: 76/min, BP:100/60 mm of Hg	HR: 120/min, BP: 160/90	HR: 96/min BP: 130/90	HR: 108/min, BP: 110/70, RR:16/min	HR: 112/min, BP: 110/70
Abnormal laboratory investigations	Hb: 9.6 gm/dL, TLC: 14,100 cells/mm <sup>3</sup> Ecg: T wave inversion in lateral leads. ECHO: Left ventricular hypertrophy, EF: 35%, Grade-I diastolic dysfunction regional wall motion abnormality to the left anterior descending artery territory	Hb: 8.2 gm%, TLC: 13,430, S.Creatinine: 3.9 mg/dL, Urea: 36 mg/dL, ECG: Sinus Tachycardia	Hb: 8.2 gm%, TLC: 18,540, Urea: 78 mg/dL Creatinine: 2.9 mg/dL	Hb: 13gm/dL, TLC: 11,000 and ECG showed left ventricular hypertrophy	Hb:8.9 gm/dL, TLC: 15,540 cells/mm <sup>3</sup> , Urea: 50 mg/dL, Creatininie:3 mg/dL
ASA class	III	III	III	II	III

**[Table/Fig-1]:** Patient parameters.

M: Male; F: Female; ASA: American society of anaesthesiologists; CKD: Chronic kidney disease; P: Pulse; BP: Blood pressure; Hb: Haemoglobin; TLC: Total leukocyte count; ECG: Electrocardiography; ECHO: Echocardiogram; EF: Ejection fraction; HR: Heart rate

amputation. The patient had been NPO for four hours. He had history of diabetes for 15 years and was on insulin. Additionally, he had acute-on-Chronic Kidney Disease (CKD) and he was on conservative management for the same. On examination, the patient was febrile, with a heart rate of 120/min and blood pressure of 160/90 mmHg. Systemic examination revealed no abnormalities. The investigation results were as follows: haemoglobin level was 8.2 gm%, total leukocyte count was 13,430 cells/mm<sup>3</sup>, serum creatinine was 3.9 mg/dL, and serum urea was 36 mg/dL. The remaining blood investigation reports were within normal limits. His ECG showed sinus tachycardia, and chest X-ray was normal. The patient was classified as ASA III and taken up for surgery.

### Case-3

A 58-year-old male patient presented with left diabetic foot gangrene. The patient had history of diabetes for 21 years and was on insulin. Additionally, he had been diagnosed with Chronic Kidney Disease (CKD) three years ago and had been undergoing dialysis for the past three months. The patient's last dialysis session was one week ago. Vital signs were stable, and systemic examination revealed no abnormalities. The investigation reports were as follows: haemoglobin level was 8.2 gm%, total leukocyte count was 18,540 cells/mm<sup>3</sup>, urea level was 78 mg/dL, and serum creatinine was 2.9 mg/dL. The remaining blood investigations were within normal limits. The patient was classified as ASA III and taken up for the procedure.

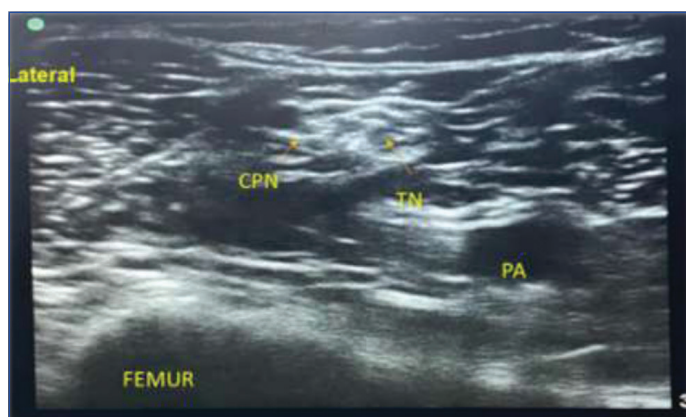
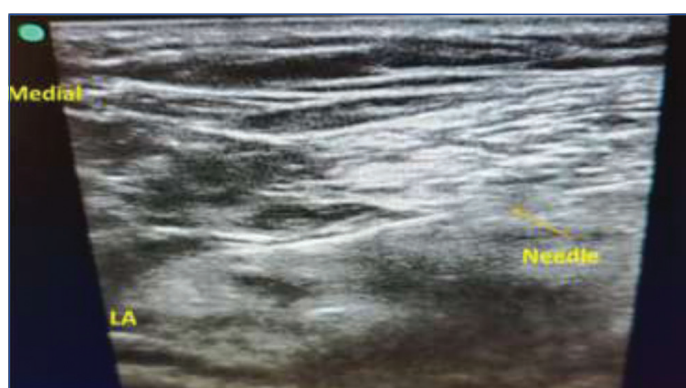
### Case-4

A 76-year-old female patient with gangrene in the right lower limb due to peripheral vascular disease was scheduled for below-knee amputation. The patient was diabetic for 30 years on diet control. Patient was also hypertensive for 30 years, on treatment with amlodipine 5 mg twice daily. On examination, the patient was afebrile. Her heart rate was 108 beats per minute, blood pressure was 110/70 mmHg, and respiratory rate was 16 breaths per minute. Systemic examination revealed no abnormalities. Haemoglobin level was 13 mg/dL, total leukocyte count was 11,000, and ECG showed left ventricular hypertrophy. All other investigations were within normal limits. The patient was classified as ASA II, but a high-risk consent was obtained considering her age.

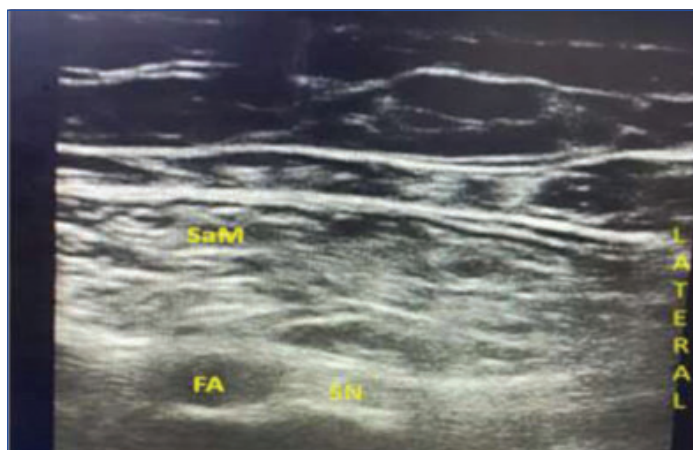
### Case-5

A 66-year-old male patient with peripheral vascular disease in the right diabetic foot was scheduled for below-knee amputation. He had history of diabetes for 25 years and was on insulin. Additionally, he had CKD for four years and was managed conservatively. The patient's vital signs were stable, and systemic examination revealed no abnormalities. The investigation reports were as follows: haemoglobin level was 8.9 gm%, total leukocyte count was 15,540 cells/mm<sup>3</sup>, urea level was 50 mg/dL, and creatinine level was 3 mg/dL. The remaining blood investigations were within normal limits. The patient was instructed to be NPO for six hours and was classified as ASA III. Informed consent was obtained prior to the procedure.

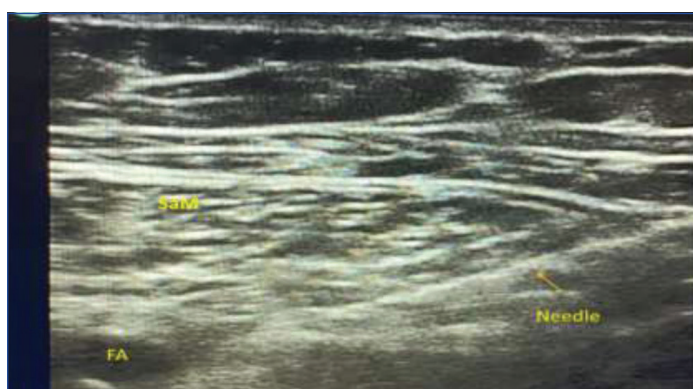
Routine monitoring, including pulse oximetry, non Invasive Blood Pressure (NIBP), and ECG, was applied to all patients. Popliteal sciatic nerve block was performed with the patient in lateral position. An antiseptic solution was applied to the area around the popliteal crease, and sterile drapes were used. A high-frequency linear probe was placed at the popliteal crease to identify the popliteal artery and vein in the transverse axis. The common peroneal and posterior tibial nerves were also identified. These nerves were traced proximally until the vlock's sheath was identified [Table/Fig-2]. After anaesthetising the skin and subcutaneous tissue, a 23-gauge spinal needle was inserted using an in-plane technique from the lateral side, directed towards the sciatic nerve [Table/Fig-3]. Once the positioning of the needle within the nerve sac was confirmed, a local anaesthetic solution consisting of 10 mL of 0.5% bupivacaine and 5 mL of 2% lignocaine with adrenaline (1:200,000), diluted with 5 mL of distilled water to a total volume of 20 mL, was injected. A post scan was performed confirm the spread of the local anaesthetic along the common peroneal and posterior tibial nerves. Following the popliteal sciatic nerve block, the adductor canal block was performed. The patient was placed in supine position, and the affected limb was abducted and externally rotated at the hip joint.

**[Table/Fig-2]:** Ultrasound-guided popliteal sciatic nerve block. CPN: Common peroneal nerve; TN: Tibial nerve; PA: Popliteal artery**[Table/Fig-3]:** Ultrasound-guided popliteal sciatic nerve block. LA: Local anaesthetic

A high-frequency linear probe was placed on the medial aspect of the thigh, 10 centimeters above the knee joint, in the transverse axis. The femur, vastus medialis muscle, and sartorius muscle were identified [Table/Fig-4]. The saphenous nerve and femoral artery were visualised. A needle was inserted using an in-plane technique from lateral to medial, confirming the position of the needle tip in the adductor canal below the sartorius muscle [Table/Fig-5]. A local anaesthetic solution consisting of 8 mL of 0.5% bupivacaine and 4 mL of 2% lignocaine with adrenaline (1:200,000), diluted with distilled water to a total volume of 16 mL, was injected. All patients achieved adequate surgical anaesthesia within 20 to 25 minutes after the block. Tourniquet was not required in any of the patients due to their peripheral vascular disease. After the procedure, all patients were observed in the recovery room for 24 hours, and their vital parameters remained within normal limits. All patients, except for patient four, received one pint of blood transfusion in the postoperative recovery room. Additionally, all patients received 1 gm paracetamol as an infusion three times a day. According to institutional protocols, all patients received intravenous tramadol at a dose of 2 mg/kg when they complained of pain (VAS >4). The time to the first dose of tramadol after the block was 10 hours for Case-1, eight hours for Case-2, six hours for Case-3, seven hours for Case-4 and eight hours for Case-5. None of the patients developed hypotension, bradycardia, or any anaesthesia-related complications.



**[Table/Fig-4]:** Ultrasound guided adductor canal block.  
SaM: Sartorius muscle; FA: Femoral artery; SN: Saphenous nerve



**[Table/Fig-5]:** Ultrasound guided adductor canal block.  
SaM: Sartorius muscle; FA: Femoral artery

## DISCUSSION

Patients requiring emergency below-knee amputation often present with sepsis, Multiple Organ Dysfunction Syndrome (MODS), and other co-morbid conditions. A combination of femoral nerve block/adductor canal block, along with sciatic nerve block (subgluteal or popliteal approach), has been successfully used for below-knee surgeries and postoperative analgesia [1-3]. Descriptive studies and case reports have been published regarding the combined use of adductor canal and popliteal sciatic nerve block for below-knee

surgeries [1-3]. Studies conducted by Arjun BK et al., and Ara M et al., included patients undergoing below-knee surgeries, such as below-knee amputation, diabetic foot debridement, and distal tibial plating. Both studies concluded that ultrasound-guided combined popliteal sciatic nerve block and adductor canal block offer a safe and effective alternative to spinal anaesthesia for below-knee surgeries [1,2]. Below-knee amputation requires anaesthesia below the knee, and there are a few published articles on below-knee amputation under femoral and popliteal sciatic nerve block [4-8]. Choi YS et al., published a case report on below-knee amputation under combined ultrasound-guided popliteal sciatic and femoral block in a patient with a recent history of myocardial infarction while on anticoagulants [5]. In adductor canal block, the local anaesthetic solution is deposited in the adductor canal, which contains the saphenous nerve and nerve to vastus medialis [9]. Branches of the anterior obturator nerve may also be present in the adductor canal [10]. The local anaesthetic injected in the adductor canal is known to spread proximally and provide anaesthesia over the medial aspect of the leg [10,11]. Combined popliteal sciatic nerve block produces complete anaesthesia of the lower limb below the knee joint. While sensory innervation of the lower leg is attributed to the saphenous and sciatic nerves, the posterior femoral cutaneous nerve may also play a role in sensory innervation of the lower leg [12,13]. However, all patients in present case series experienced complete anaesthesia below the knee. A combination of bupivacaine and lignocaine with adrenaline was used as the combination is associated with faster onset and longer duration of action [14]. This case series affirms that below knee amputation can be safely performed under a combination of adductor canal block and popliteal sciatic nerve block in high-risk patients. Further studies are required to compare adductor canal block with femoral block, in addition to popliteal sciatic nerve block, in patients undergoing below-knee amputation.

## CONCLUSION(S)

The combination of ultrasound-guided popliteal sciatic nerve block and adductor canal block provides complete surgical anaesthesia below the knee joint without any haemodynamic complications. It can be used as a sole anaesthetic technique in high-risk patients undergoing below-knee amputation.

## REFERENCES

- [1] Arjun BK, Prijith RS, Sreeraghu GM, Narendrababu MC. Ultrasound-guided popliteal sciatic and adductor canal block for below-knee surgeries in high-risk patients. *Indian J Anaesth.* 2019;63(8):635-39.
- [2] Ara M, Sheikh TA, Benazir K. USG guided popliteal sciatic and adductor canal block for below knee surgeries and postoperative analgesia in high-risk patients. *Int J Med Anesthesiol.* 2021;4(3):15-18.
- [3] Zhu L, Gong C, Zhang Z, Zhang Q, Peng P, Ni Y. Efficacy and safety of ultrasound-guided above-knee lateral approach for popliteal sciatic nerve block in surgeries below the knee: A randomized controlled trial. *Annals of Palliative Medicine.* 2021;10(5):5188-97.
- [4] Lo Q, Thomas L. Echocardiographic evaluation of diastolic heart failure. *Australas J Ultrasound Med.* 2010;13(1):14-26.
- [5] Choi YS, Shin HJ, Park JY, Kim HJ, Yun SH. Ultrasound-guided femoral and popliteal sciatic nerve blocks for below knee surgery in patients with severe cardiac disease. *Korean J Anesthesiol.* 2015;68(5):513-15.
- [6] Shamim F, Hameed M, Siddiqui N, Abbasi S. Ultrasound-guided peripheral nerve blocks in high-risk patients, requiring lower limb (Above and below knee) amputation. *Int J Crit Illn Inj Sci.* 2018;8(2):100-03.
- [7] Maamoon R, Ibrahim D, Hamed I. Ultrasound-guided sciatic nerve block in below knee amputation surgery: Sub gluteal versus popliteal approach: The open Anesth Journal. 2018;12(1):19-25.
- [8] Cheran K, Bastina J. A case report of below knee amputation in patient with very low ejection fraction under ultrasound guided popliteal sciatic and femoral nerve block. *Int J of Current Advanced Research.* 2021;10(08):24912-14.
- [9] Hadzic's Textbook of Regional Anaesthesia and Acute Pain Management. 2<sup>nd</sup> edition; pp. 615-635.
- [10] Burckett-St Laurant D, Peng P, Girón Arango L, Niazi AU, Chan VW, Agur A, et al. The nerves of the adductor canal and the innervation of the knee: An anatomic study. *Reg Anesth Pain Med.* 2016;41(3):321-27.
- [11] Tao Y, Zheng SQ, Xu T, Wang G, Wang Y, Wu AS, et al. Median effective volume of ropivacaine 0.5% for ultrasound-guided adductor canal block. *J Int Med Res.* 2018;46(10):4207-13.

- [12] Li H, Cho DH, Tokhner V. Unique considerations for complete surgical analgesia for below-the-knee amputations. *Cureus*. 2021;13(3):e14224.
- [13] Feigl GC, Schmid M, Zahn PK, Avila González CA, Litz RJ. The posterior femoral cutaneous nerve contributes significantly to sensory innervation of the lower leg: An anatomical investigation. *Br J Anaesth*. 2020;124(3):308-13.
- [14] Sripriya R, Sivashanmugam T, Rajadurai D, Parthasarathy S. Equal mixture of 2% lidocaine with adrenaline and 0.5% bupivacaine 20 mL provided faster onset of complete conduction blockade during ultrasound-guided supraclavicular brachial plexus block than 20 mL of 0.5% bupivacaine alone: A randomized double-blinded clinical trial. *Regional Anesthesia and Pain Medicine*. 2023;rapm-104542.

**PARTICULARS OF CONTRIBUTORS:**

1. Associate Professor, Department of Anaesthesiology, Kanachur Institute of Medical Sciences, Mangalore, Karnataka, India.
2. Assistant Professor, Department of Anaesthesiology, Kanachur Institute of Medical Sciences, Mangalore, Karnataka, India.
3. Assistant Professor, Department of Anaesthesiology, Kanachur Institute of Medical Sciences, Mangalore, Karnataka, India.
4. Junior Resident, Department of Anaesthesiology, Kanachur Institute of Medical Sciences, Mangalore, Karnataka, India.

**NAME, ADDRESS, E-MAIL ID OF THE CORRESPONDING AUTHOR:**

Dr. MK Sandhya,  
Associate Professor, Department of Anaesthesiology, Kanachur Institute of Medical Sciences, University Road, Natekal, Mangalore, Karnataka, India.  
E-mail: sandhyamohanmk@gmail.com

**PLAGIARISM CHECKING METHODS:** [Jain H et al.]

- Plagiarism X-checker: Jun 28, 2023
- Manual Googling: Aug 08, 2023
- iThenticate Software: Aug 26, 2023 (13%)

**ETYMOLOGY:** Author Origin**EMENDATIONS:** 7**AUTHOR DECLARATION:**

- Financial or Other Competing Interests: None
- Was informed consent obtained from the subjects involved in the study? Yes
- For any images presented appropriate consent has been obtained from the subjects. Yes

Date of Submission: **Jun 26, 2023**Date of Peer Review: **Aug 01, 2023**Date of Acceptance: **Aug 29, 2023**Date of Publishing: **Sep 01, 2023**