

Dorsal Lingual Lipoma (Yellow Epulis): A Case Report

JIGNESH GANDHI¹, PRAVIN SHINDE², TARUN SHETTY³, AARSH GAJJAR⁴

(CC) BY-NC-ND

ABSTRACT

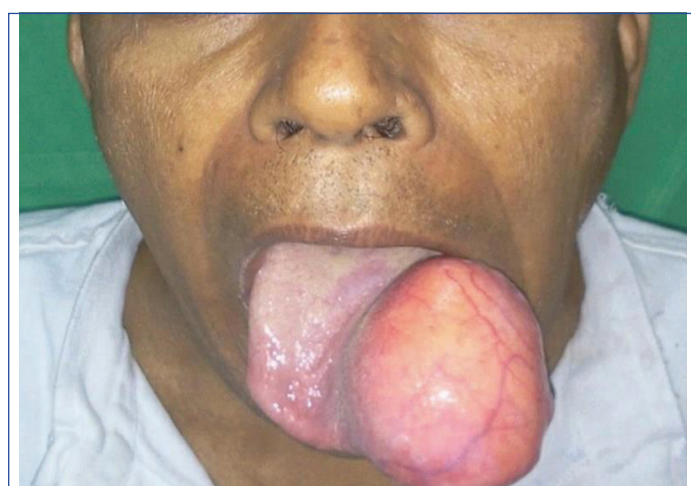Lipoma is a common soft tissue tumour. Its occurrence in the oral mucosa is rare, accounting for 1% to 5% of all benign oral tumours. Typically, it presents as an asymptomatic yellowish mass. The overlying epithelium remains intact, and superficial blood vessels are often visible on the tumour's surface. The present report presents a case of tongue lipoma in a 50-year-old man who was referred to the department due to a tongue mass. The duration of the mass's presence was unknown. Clinical examination revealed a yellowish nodular lesion. Histological examination confirmed the diagnosis of classic lipoma, showing mature adipocytes and vessels of varying sizes within the adipocyte lobules. The lesion was surgically excised, and no recurrence was observed during the one-year follow-up period.

Keywords: Benign tumour, Dorsum of tongue, Local excision

CASE REPORT

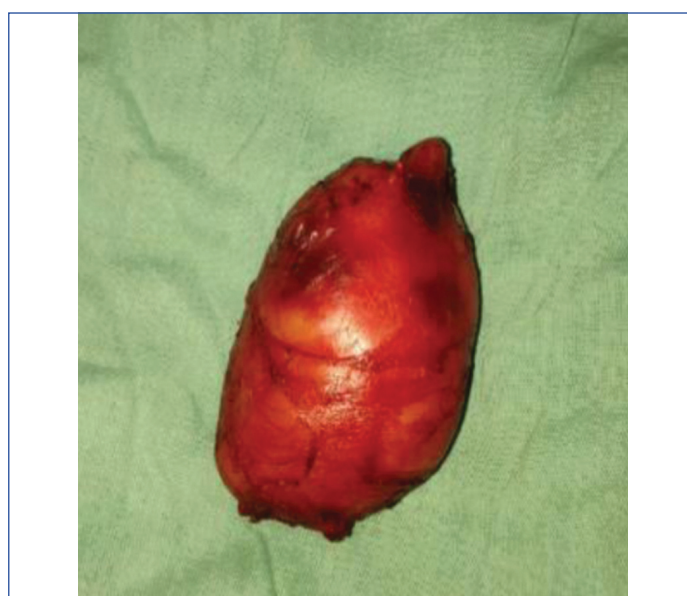A 50-year-old male presented to the Department of General Surgery with a large mass on the dorsum of his tongue. The swelling had been present for two years and recently grew rapidly, causing significant cosmetic and functional impairment. The patient had difficulty in talking but did not complain of dysphagia or dyspnea. He tolerated oral intake well but mentioned difficulty in forming a bolus for the past 15 days. There was no associated bleeding or pain. The patient's medical history was otherwise unremarkable.

Clinical examination revealed a solitary, giant, rubbery mass on the dorsal aspect of the lateral left border of the tongue, measuring approximately 6×4 cm. The lesion was soft, round, sessile, and movable, with intact superficial epithelium and normal mucosal coverage [Table/Fig-1]. Palpation revealed a well-defined mass without tenderness or pus discharge. Facial symmetry was maintained, and no cervical lymphadenopathy was present. Based on these findings, a provisional clinical diagnosis of lipoma was made.

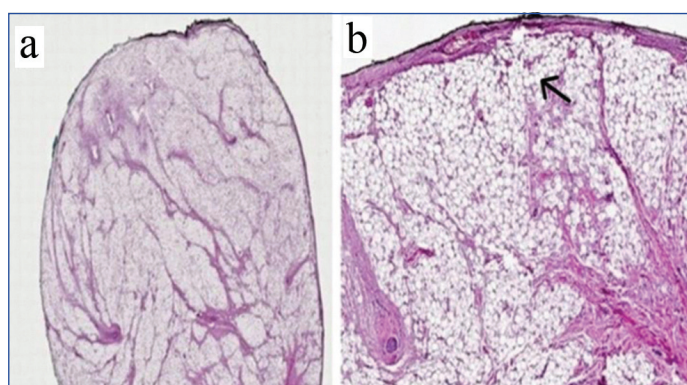


[Table/Fig-1]: Clinical examination reveals large, smooth and rubbery masses on the dorsal aspect of the left border of the tongue.

Surgical excision of the lipoma was performed under general anaesthesia. The excised specimen was rubbery and lobulated, with a maximum anteroposterior diameter of 6×4 cm [Table/Fig-2]. The mass was well separated from the surrounding tissues and had a fatty-yellow appearance with a well-defined capsule. Histological examination confirmed the presence of clear lobules of mature fat cells, consistent with the diagnosis of a classic lipoma [Table/Fig-3].

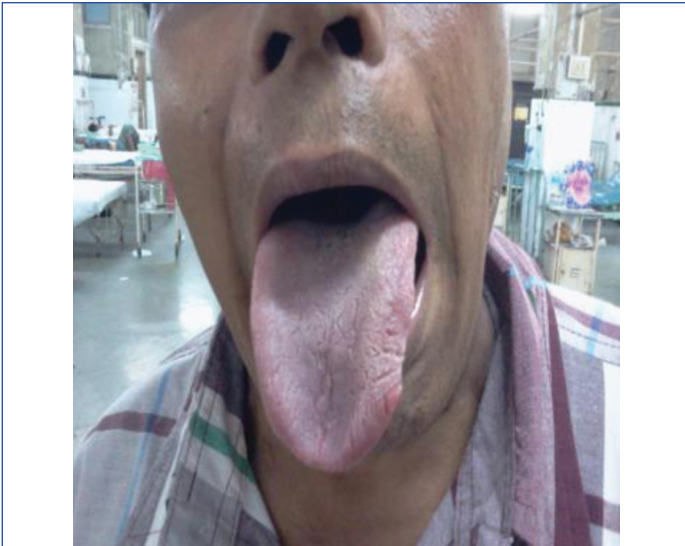

[Table/Fig-2]: The surgical specimen, measuring 6×4 cm.



[Table/Fig-3]: a) A histopathologic examination shows an encapsulated, multinodular mass with mature adipose tissue (Haematoxylin and Eosin (H&E) stain, original magnification ×12.5); b) Mature adipocytes marked by the arrow, exhibit variable size and shape with small eccentric nuclei arranged randomly (H&E stain; original magnification ×200).

Following the surgery, the patient experienced a complete recovery of their pronunciation and feeding abilities, with no sensory or motor function loss. Their tongue fit comfortably in their mouth, and a 1-year postoperative follow-up showed no significant issues [Table/Fig-4].



[Table/Fig-4]: Postoperative image showing complete recovery.

DISCUSSION

Dorsal lingual lipomas, also known as yellow epulis, are rare benign neoplasms of the tongue that arise from mature adipose tissue. The incidence of dorsal lingual lipomas worldwide is not well-established due to their rarity, but it is estimated to be less than 1% of all oral tumour [1]. In India, the reported incidence of oral lipomas is approximately 0.84% of all benign tumour of the oral cavity, with dorsal lingual lipomas accounting for a small proportion of these cases [2].

The clinical presentation of dorsal lingual lipomas can vary depending on the size and location of the mass. In the present case report, the patient presented with a large mass on the dorsum of the tongue, causing significant cosmetic and functional impairment. Other common clinical presentations include painless swelling, difficulty in chewing or speaking, and dysphagia [3].

Furlong MA et al., reviewed 125 cases of oral and maxillofacial lipomas and found that only 15 were of the tongue, with a mean duration of the tumour prior to excision being 3.2 years, ranging from six weeks to 15 years, and a size range of 0.5 to 8 cm [4]. Baonerkar HA et al., reviewed 64 cases of tongue lipomas and found that the occurrence was more frequent after 40 years of age, and all cases reported were between the age group of 20 to 81 years. There was a slight male predilection. Most of the cases presented clinically as slow-growing and asymptomatic masses, with surgical excision being the treatment of choice in all cases [5].

Imaging modalities such as Computed Tomography (CT) and Magnetic Resonance Imaging (MRI) can aid in the diagnosis of dorsal lingual lipomas, but histological examination remains the gold

standard for diagnosis [6]. CT scans show a high density of 83-143 Hounsfield units, with no sharp or well-defined borders by the capsule. Ultrasonography shows round or oval lesions with intact or nearly intact capsules. Most lipomas are hypoechoic with echogenic lines or spots [7].

Differential diagnoses to be considered include ranula, dermoid cyst, thyroglossal cyst, ectopic thyroid tissue, pleomorphic adenoma, mucoepidermoid carcinoma, other benign oral tumour such as fibromas, haemangiomas, and schwannomas, as well as malignant tumour such as squamous cell carcinoma and lymphoma [8].

Histological examination after lipoma removal is mandatory to rule out liposarcomatous degeneration and detect lost capsules and requires continued follow-up due to the high likelihood of recurrence. The recurrence rate for dorsal lingual lipomas is low, and surgical excision remains the primary management option. The surgical approach can vary depending on the size and location of the mass, but complete excision with adequate margins is necessary to prevent recurrence [9].

CONCLUSION(S)

Dorsal lingual lipomas are rare benign neoplasms of the tongue that can present with a variety of clinical manifestations. Imaging modalities can aid in the diagnosis, but histological examination remains the gold standard. Surgical excision with adequate margins is the primary management option, and the recurrence rate is low. Further studies are needed to establish the worldwide incidence and prevalence of dorsal lingual lipomas and to investigate potential risk factors for their development.

REFERENCES

- [1] Fitzgerald K, Sanchirico PJ, Pfeiffer DC. Large intramuscular lipoma of the tongue. *Radiol Case Rep.* 2018;13(2):361-64.
- [2] Bajpai M, Arora M, Chandolia B. Prevalence of oral lipomas in Indian population: An institutional retrospective study of 12 years and analysis of 49 published cases from 1976-2017 reported in Indian patients. *Eur J Gen Med.* 2016;13(3):42-46.
- [3] Agarwal R, Kumar V, Kaushal A, Singh RK. Intraoral lipoma: A rare clinical entity. *BMJ Case Rep.* 2013;2013:bcr2012007889.
- [4] Furlong MA, Fanburg-Smith JC, Childers EL. Lipoma of the oral and maxillofacial region: Site and subclassification of 125 cases. *Oral Surg Oral Med Oral Pathol Oral Radiol Endod.* 2004;98(4):441-50.
- [5] Baonerkar HA, Vora M, Sorathia R, Shinde S. The lipoma of tongue-A rare site for a tumor: Case report and review of the literature. *Indian J Dent.* 2015;6(4):207-10.
- [6] Colella G, Biondi P, Caltabiano R, Vecchio GM, Amico P, Magro G. Giant intramuscular lipoma of the tongue: A case report and literature review. *Cases J.* 2009;2:7906.
- [7] Zhong LP, Zhao SF, Chen GF, Ping FY. Ultrasonographic appearance of lipoma in the oral and maxillofacial region. *Oral Surgery, Oral Medicine, Oral Surg Oral Med Oral Pathol Oral Radiol Endod.* 2004;98(6):738-40.
- [8] Magadum D, Sanadi A, Agrawal JM, Agrawal MS. Classic tongue lipoma: A common tumour at a rare site. *BMJ Case Rep.* 2013;2013:bcr2012007987.
- [9] Maglito F, Norino G, Arena A, Friscia M, Barone S, Committeri U, et al. A giant intramuscular lipoma of tongue: A case report and literature review. *Oral and Maxill Surg Cases.* 2023;9(1):100287.

PARTICULARS OF CONTRIBUTORS:

1. Professor, Department of General Surgery, Seth GSMC and KEM Hospital, Mumbai, Maharashtra, India. **ORCID ID: 0000-0001-7888-4828**
2. Associate Professor, Department of General Surgery, Seth GSMC and KEM Hospital, Mumbai, Maharashtra, India. **ORCID ID: 0000-0002-5972-1561**
3. Resident, Department of General Surgery, Seth GSMC and KEM Hospital, Mumbai, Maharashtra, India. **ORCID ID: 0000-0002-1905-6245**
4. Undergraduate Student, Department of General Surgery, Seth GSMC and KEM Hospital, Mumbai, Maharashtra, India. **ORCID ID: 0000-0002-2256-0039**

NAME, ADDRESS, E-MAIL ID OF THE CORRESPONDING AUTHOR:

Aarsh Gajjar,
Undergraduate Student, Department of General Surgery, Seth GSMC and KEM Hospital, Mumbai-400012, Maharashtra, India.
E-mail: aarshgajjar@gmail.com

PLAGIARISM CHECKING METHODS: [Jain H et al.]

- Plagiarism X-checker: Dec 13, 2023
- Manual Googling: Mar 16, 2023
- iThenticate Software: Sep 22, 2023 (13%)

ETYMOLOGY: Author Origin

EMENDATIONS: 7

AUTHOR DECLARATION:

- Financial or Other Competing Interests: None
- Was informed consent obtained from the subjects involved in the study? Yes
- For any images presented appropriate consent has been obtained from the subjects. Yes

Date of Submission: **Dec 12, 2022**

Date of Peer Review: **Feb 21, 2023**

Date of Acceptance: **Apr 05, 2023**

Date of Publishing: **Sep 01, 2023**