

Excessive Immunoglobulin Lambda (λ) Light Chain Production with Thrombocytopenia and Anaemia in a Patient with Smoldering Multiple Myeloma: A Case Report

BANDANA MEHROTRA¹, ASHOK KUMAR KAPOOR², RAJESH KUMAR SRIVASTAVA³, HARI SHYAM⁴, SUPRIYA MEHROTRA⁵



ABSTRACT

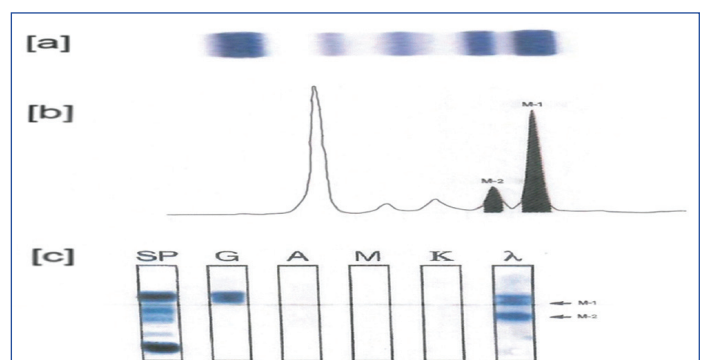
Smoldering Multiple Myeloma (SMM) is defined as focal premalignant plasma cell proliferation in the bone marrow, along with the presence of monoclonal or biclonal protein bands in the patient's serum. The current patient complained of severe weakness six months after knee arthroplasty. The patient exhibited a monoclonal (M-1) band on Serum Protein Electrophoresis (SPEP), which was observed in the γ -globulin region in combination with γ -heavy chains. Another protein band (M-2) was identified in the β -globulin region. These paraproteins were later confirmed by Immunofixation Electrophoresis (IFE), and both proteins reacted with anti- λ antibody. The concentration of the M-1 band was 32% (2.82 gm/dL), while the concentration of the M-2 protein band was 7.9% (0.7 gm/dL). Additionally, the total serum proteins measured 8.84 gm/dL. The plasma cell count in the Bone Marrow (BMPC) was approximately 20%. Provisionally, the patient was diagnosed as a case of gammopathy, with non-IgM Monoclonal Gammopathy of Undetermined Significance (MGUS), light chain MGUS, SMM, and MM considered in the differential diagnosis. However, the final diagnosis for the current patient was SMM. The patient responded well to treatment with cyclophosphamide and prednisone.

Keywords: Immunofixation electrophoresis, Monoclonal gammopathy, Serum protein electrophoresis

CASE REPORT

A 63-year-old female presented a history of bilateral severe, gradually increasing pain in the knee joints. The pain became unbearable and hindered her normal routine, leading to bilateral knee joint replacement surgery (arthroplasty). Following the operation, the patient experienced relief from joint pain and achieved functional recovery. However, six months after the surgery, she developed generalised weakness, which necessitated hospitalisation. Upon admission, her haemoglobin was 6.2 gm/dL, and her platelet count was 78,000/mm³. Bone marrow examination revealed an increased number of plasma cells, approximately 20% of all nucleated cells. Serum IgM measured 44 mg/dL, serum IgA was 60 mg/dL, and serum IgG was 2,298 mg/dL. The concentration of lambda (λ) light chain in the serum was 80 mg/dL [Table/Fig-1]. Serum calcium levels were within the normal range (9 mg/dL), and serum creatinine measured 1.4 mg/dL. Two units of whole blood transfusion were administered, resulting in an increase in haemoglobin levels to 9.0 gm/dL. Findings supporting the final diagnosis included a monoclonal protein spike of approximately 3 gm/dL and plasma cells comprising about 20% of nucleated cells in the bone marrow (BMPC) [Table/Fig-1]. No other CRAB features were detected apart from anaemia. Serum Protein Electrophoresis (SPEP) revealed two distinct M-1 and M-2 protein peaks. The M-1 peak appeared in the γ -globulin region, while a minor M-2 peak was observed in the β -globulin region [Table/Fig-1]. Immunofixation Electrophoresis (IFE) results indicated that both peaks consisted of λ light chains. The current patient received treatment with orally administered cyclophosphamide (200 mg/m² per day) and prednisone (40 mg/m² per day). The drugs were given for seven days followed by a month-long gap before repeating the cycle three times.

Cyclophosphamide and prednisone were chosen as the preferred treatment due to the lower toxicity of cyclophosphamide compared to lenalidomide. After six months of therapy, the patient's haemoglobin



[Table/Fig-1]: a) showed results of Serum Protein Electrophoresis (SPEP). Sharp distinct separate monoclonal M-1 and M-2 bands were seen; b) Densitometric analysis showed sharp major peak of M-1 and minor peak as M-2. c) Results of precipitation reaction in serum IFE. After electrophoresis, different lanes were treated with various antibodies. SP denotes anti-whole serum protein (SP) antibody. G denotes anti- γ antibody. A denotes anti- α antibody, M denotes anti- μ antibody, k denotes anti-kappa antibody and λ denotes anti- λ antibody. Monoclonal (M-1) λ major band was seen in γ -globulin region. Minor b and (M-2) was seen in β -globulin region.

level increased to 11 gm/dL, and the platelet count rose to 1.6 lac/mm³. We hereby present the interesting findings of the present case of SMM.

DISCUSSION

The serum 'M' component was initially identified as a tall, narrow spike in a case of MM by Longsworth LG et al., [1]. It was later referred to as the 'M' protein by Moore DH et al., [2]. The risk of SMM progressing to MM is higher (10% each year for five years) [1-3]. Bone Marrow Plasma Cells (BMPC) are CD138+ and positive for either kappa (k) or lambda (λ) light chains. The incidence of MM is lowest in individuals from developing countries. In the current case, two monoclonal protein bands were observed on SPEP. The M-1 band appeared in the γ -globulin region, while the M-2 band was detected in the β -globulin region. Densitometric analysis confirmed the bands as spikes. Subsequently, IFE was performed

to characterise the protein bands, and both bands exhibited a precipitation reaction with anti- λ antibody [Table/Fig-1].

The most important finding in the present case was the detection of two immunoglobulin λ protein light chain bands by IFE. Both protein bands had different charges, resulting in variable migration patterns. The M-2 band was observed in the β -globulin region and migrated more quickly, while the M-1 band migrated slowly. However, both bands had similar antigenic determinants. Immunoglobulin λ light chain bands have been previously observed in MM [4,5].

Another significant feature in this case was the presence of severe anaemia and thrombocytopenia. Anaemia is a known occurrence in MM patients, while thrombocytopenia is rarely detected. These conditions may develop due to the plasma cell tumour burden and the inhibition of haematopoiesis by cytokines secreted by the tumour cells [6]. Mild haemolysis may also contribute to anaemia. The patient experienced generalised weakness as a result of severe anaemia. Additionally, anaemia may occur in 80% of myeloma patients. The patient did not exhibit hypercalcaemia or elevated serum creatinine levels. Instead, she presented with severe anaemia and moderate thrombocytopenia alone. Therefore, not all the CRAB features could be fulfilled. The patient appeared to be in the early stages of MM (pre-malignant). Differential diagnoses considered included non-IgM Monoclonal Gammopathy of Undetermined Significance (MGUS), light chain MGUS, SMM, and MM [7]. Ultimately, the patient was diagnosed with SMM [8].

In patients with MM, bacterial infections may be a presenting symptom. The catabolic rate of IgG is higher in MM patients compared to normal subjects, which may contribute to the increased incidence of bacterial infections. Another interesting aspect of this case was the production of λ light chains. Immunoglobulin λ chains appeared to be associated with normal intact IgG in the M-1 band. Additionally, an excess of λ chains was found in the β -globulin region. The excess λ light chains migrated more quickly compared to λ light chains associated with γ -heavy chains. Although eosinophilia is known to occur in MM, it was not observed in this case [9]. Furthermore, λ light chains are more likely to damage the kidney tubules compared to κ light chains. Myeloma cells bind to the extracellular matrix and cell adhesion molecules in the bone marrow, which may facilitate the proliferation of pre-malignant plasma cells. The etiopathogenesis of MM is still unknown. Previous reports have indicated an association between MM and systemic lupus erythematosus [10]. Moreover, MM is more commonly observed in farmers, wood and leather workers, and individuals exposed to petroleum products. In rare cases, patients may have a history of previous radiation exposure with an approximately 20-year latency period. Additionally, metallosis

can develop following knee arthroplasty. It may occur due to friction between the femoral and tibial prosthetic surfaces, resulting in damage to the tibial polyethylene, T-cell stimulation, and cytokine release [11]. Severe weakness in this case may have developed due to metallosis following knee arthroplasty.

CONCLUSION(S)

The present case involved a patient who underwent joint replacement therapy and subsequently developed generalised weakness. Serum Protein Electrophoresis (SPEP) revealed the presence of two monoclonal (M) bands, with one (M-1) detected in the γ -globulin region and the other (M-2) in the β -globulin region. Both bands reacted with anti- λ antibody, indicating antigenic similarity. This could be a result of an imbalance in immunoglobulin synthesis by plasma cells. Another important feature of the present case was the presence of severe anaemia and moderate thrombocytopenia. Reduction in platelet count is relatively rare in MM. The severe anaemia and thrombocytopenia may have developed due to an increased plasma cell tumour mass and the inhibition of haematopoiesis by cytokines. The patient showed a good response to treatment with prednisone and cyclophosphamide.

REFERENCES

- [1] Longworth LG, Shedlovsky T, Macinnes DA. Electrophoretic patterns of normal and pathological human blood serum and plasma. 1939;70(4):399-413.
- [2] Moore DH, Kabat EA, Gutman AB. Bence-Jones proteinemia in multiple myeloma. J Clin Invest. 1943;22:67-75.
- [3] Srinivasan VK, Bhagat P, Bansal F, Chhabra S. Occurrence of double monoclonal bands on protein electrophoresis: An unusual finding. Indian J Hematol Blood Transfus. 2016;32(Suppl 1):184-88.
- [4] Misra S, Anu S, Kumar V. Plasma cell myeloma with double M-bands on serum protein electrophoresis: A diagnostic Conundrum? MAMC J Med Sciences. 2021;7(3):265-68.
- [5] Kapoor AK, Mehrotra S, Srivastava RK. Immunoglobulin light-chain isotype switch (IS) during Lenalidomide therapy in multiple myeloma and its association with increased M protein production and military TB. J Clin Diag Res. 2019;13(4):ED04-ED05.
- [6] Longo DL, Broder S. Plasma cell disorders. In 'Harrison's principles of Internal medicine 11th edition. Braunwald E, Isselbacher KJ, Petersdorf RG, Wilson JD, Martin JB, Fauci AS (editors), McGraw-Hill book company (publishers), New York, Pp.1398-1401.
- [7] Rajkumar SV, Kumar S, Lonial S, Mateos MV. Smoldering multiple myeloma current treatment algorithms. Blood Cancer J. 2022;12:129.
- [8] Atkin C, Richter A, Sapey E. What is the significance of monoclonal gammopathy of undetermined significance? Royal College of Physicians. 2018;18(5):391-95.
- [9] Glantz L, Rintels P, Samoszuk M, Medeiros LJ. Plasma cell myeloma associated with eosinophilia. Amer J Clin Pathol. 1995;103(5):583-87.
- [10] Esselmani H, Yassine A, Akhtar B, Touzani O, Lfakir A. Biclinal gammopathy of Iga kappa variant in a patient with systemic lupus erythematosus: A Case Report. Clinical Med Reviews. 2021;8(6):353.
- [11] Panni AS, Vasso M, Cerciello S, Maccauro G. Metallosis following arthroplasty: A histopathological and immunohistochemical study. Pharmacol. 2011;24(3):711-19.

PARTICULARS OF CONTRIBUTORS:

1. Pathologist, Department of Pathology, RML Mehrotra Pathology Pvt. Ltd., Nirala Nagar, Lucknow, Uttar Pradesh, India.
2. Pathologist, Department of Pathology, RML Mehrotra Pathology Pvt. Ltd., Nirala Nagar, Lucknow, Uttar Pradesh, India.
3. Technologist, Department of Pathology, RML Mehrotra Pathology Pvt. Ltd., Nirala Nagar, Lucknow, Uttar Pradesh, India.
4. Technologist, Department of Pathology, RML Mehrotra Pathology Pvt. Ltd., Nirala Nagar, Lucknow, Uttar Pradesh, India.
5. Pathologist, Department of Pathology, RML Mehrotra Pathology Pvt. Ltd., Nirala Nagar, Lucknow, Uttar Pradesh, India.

NAME, ADDRESS, E-MAIL ID OF THE CORRESPONDING AUTHOR:

Dr. Ashok Kumar Kapoor,
A-21, RML Mehrotra Pathology Pvt. Ltd., Lucknow-226020, Uttar Pradesh, India.
E-mail: drashokkapoor2016@gmail.com

AUTHOR DECLARATION:

- Financial or Other Competing Interests: None
- Was informed consent obtained from the subjects involved in the study? Yes
- For any images presented appropriate consent has been obtained from the subjects. Yes

PLAGIARISM CHECKING METHODS: [Jain H et al.]

- Plagiarism X-checker: Jan 25, 2023
- Manual Googling: Mar 22, 2023
- iThenticate Software: Jul 05, 2023 (5%)

ETYMOLOGY: Author Origin

EMENDATIONS: 8

Date of Submission: Jan 21, 2023

Date of Peer Review: Mar 03, 2023

Date of Acceptance: Jul 07, 2023

Date of Publishing: Sep 01, 2023