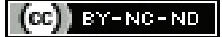

Surgical Transversus Abdominis Plane Block for Postoperative Analgesia in Lower Abdominal Surgeries: A Prospective Interventional Study

NANDINI BHUPAL¹, RAJIV KUMAR SAXENA², MEGHA HITTINHALLI³, ANUBHA KATARIA⁴, ALISHA SINGH⁵

ABSTRACT

Introduction: Pain from lower abdominal surgeries originates from the abdominal wall incision. The Transversus Abdominis Plane (TAP) is a fascial plane between the internal oblique and the transversus abdominis muscle, which contains the nerve bundles. TAP block involves infiltrating this plane with anaesthetic drugs that block the somatic component of postoperative pain. Traditionally, the TAP block is given by anaesthesiologists as a blind procedure or under Ultrasound (US) guidance. In 2010, an innovative surgical TAP block method was developed, where the surgeon gives TAP block under direct vision before closing the abdomen during abdominal surgery. Many studies have recommended surgical TAP block as an intervention for achieving postoperative pain relief.

Aim: To evaluate the efficacy of the surgical TAP block technique for postoperative analgesia following lower abdominal surgeries using Visual Analogue Scale (VAS) scores and by comparing the need for rescue analgesia and the total amount of analgesic drugs utilised within the first 24 hours of surgery.

Materials and Methods: This hospital-based prospective interventional study was conducted in the Department of Obstetrics and Gynaecology at The Oxford Medical College Hospital and Research Centre, Bengaluru, Karnataka, India, from January 2022 to December 2022. The study participants included 108 women undergoing lower abdominal surgeries under spinal or epidural or combined regional anaesthesia and belonging to the American Society of Anaesthesiologists (ASA) physical status classification system ASA I or ASA II or ASA IIE. The study group included 54 women who received surgical TAP block with 20 mL 0.25% bupivacaine and 4 mg of dexamethasone, intraoperatively on either side before

closure of the abdomen. Postoperative pain was assessed using VAS at regular intervals within 24 hours of surgery. VAS was also recorded whenever the participants demanded rescue analgesia. The control group included 54 women who received intravenous tramadol 50 mg eight hourly for postoperative pain relief, while the study group received rescue analgesia on demand or if the VAS score was recorded as three or more. The time for the first request for rescue analgesia and the total dose of rescue analgesic required in the first 24 hours after surgery were also recorded. Data were analysed using Statistical Package for Social Sciences (SPSS) version 25.0. For inferential statistics, numerical data were analysed by Chi-square test, and for continuous data, the Student's t-test was used. A p-value <0.05 was considered statistically significant.

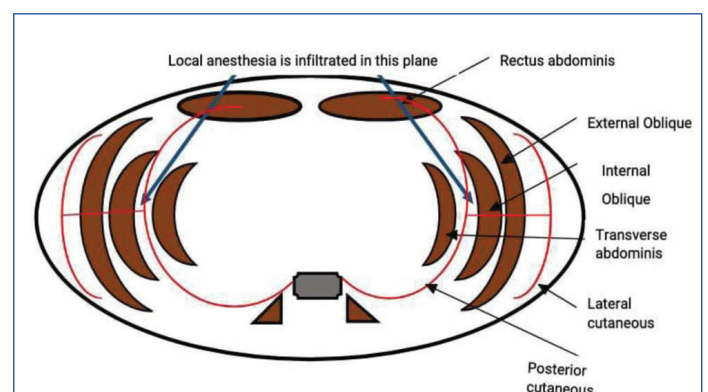
Results: The study group had significantly lower postoperative pain VAS scores when compared to the control group at four hours and beyond time intervals. The mean VAS scores at six hours were 1.85 in the study group and 2.35 in the control group (p-value=0.01), at 24 hours it was 2.04 in the study group and 2.24 in the control group (p-value=0.04). The mean time for the first rescue analgesia in the study group and control group was 11 hours 25 minutes and 2 hours 43 minutes, respectively, and the total tramadol consumption was 77.78±46.24 mg and 117.59±36.55 mg, respectively. Both results were statistically significant (p-value <0.001).

Conclusion: Surgical TAP block significantly delays the need for rescue analgesia and decreases the total analgesia required in the first 24 hours after surgery. It is an effective, safe, and simple technique for achieving postoperative pain relief.

Keywords: Analgesia, Bupivacaine, Dexamethasone, Nerve block, Tramadol, Visual analog scale

INTRODUCTION

Pain from lower abdominal surgeries is mostly somatic in origin, derived from the abdominal wall incision. The Transversus Abdominis Plane (TAP) is a fascial plane between the internal oblique and transversus abdominis muscles, which contains nerve bundles arising from the anterior rami of T6 to L1 (intercostal, subcostal, iliohypogastric, and ilioinguinal nerves) [Table/Fig-1]. TAP block involves infiltrating this plane with anaesthetic drugs that block the somatic component of postoperative pain [1]. TAP block has been used effectively for a variety of lower abdominal surgeries, including caesarean deliveries, abdominal hysterectomies, and hemicolectomy [2-5]. Ipsilateral TAP block has been used for appendectomy in children [6]. Conventionally, TAP block is performed by anaesthesiologists using a blind technique (two 'pop' techniques) through the Petit triangle. More recently,



[Table/Fig-1]: Transverse section of abdominal wall.

US-guided TAP block is being practiced. This procedure requires expert training, a good resolution Ultrasound (US) machine, and it is time-consuming. TAP block technique has the potential to cause complications like intraperitoneal injection, visceral trauma, and liver injury [7].

Owen DJ et al., first described the novel surgical TAP block technique in 2010, wherein the operating surgeon administers TAP block intraoperatively, under direct vision, before closing the abdomen [8]. Theoretically, this should reduce the incidence of procedure-related complications as it is performed under direct vision. Few Indian studies have evaluated the efficacy of surgical TAP block with bupivacaine and found it to be an effective means of reducing postoperative pain and reducing the overall opioid requirement after lower abdominal surgery [2,7].

Dexamethasone is frequently used as an adjuvant to bupivacaine to prolong the duration of peripheral nerve blocks [9]. The addition of dexamethasone enhances the effect of anaesthetic drugs, as evidenced by the lower VAS score and a reduction in the total rescue analgesic needed [10]. The novelty of this study was the addition of dexamethasone to bupivacaine in TAP block to increase the duration of analgesia.

The aim of this study was to evaluate the efficacy of the surgical TAP block technique for postoperative analgesia following lower abdominal surgeries. The null hypothesis was that surgical TAP block is ineffective and does not reduce postoperative pain. The alternate hypothesis was that surgical TAP block is an effective means of reducing postoperative pain. The objective was to evaluate pain relief using the VAS scores within the first 24 hours of surgery. The need for rescue analgesia and the total analgesic used within the first 24 hours of surgery were evaluated. The ease of performing the surgical TAP block technique was also analysed.

MATERIALS AND METHODS

This hospital-based prospective interventional study was conducted in the Department of Obstetrics and Gynaecology at The Oxford Medical College Hospital and Research Centre, Bengaluru, Karnataka, India, from January 2022 to December 2022 and was approved by the hospital ethics committee, IEC/TOMCHRC/192/2022. All participants gave written informed consent.

Inclusion criteria: Women undergoing lower abdominal surgeries under spinal or epidural or combined regional anaesthesia and belonging to ASA I or ASA II or ASA IIE were included in the study.

Exclusion criteria: Women with coagulopathy, thrombocytopenia, or receiving anticoagulation treatment (INR >1.5) or taking Non Steroidal Anti-Inflammatory Drugs (NSAIDs) or opiates 48 hours prior to surgery or having an allergy to the study drug (bupivacaine) were excluded from the study.

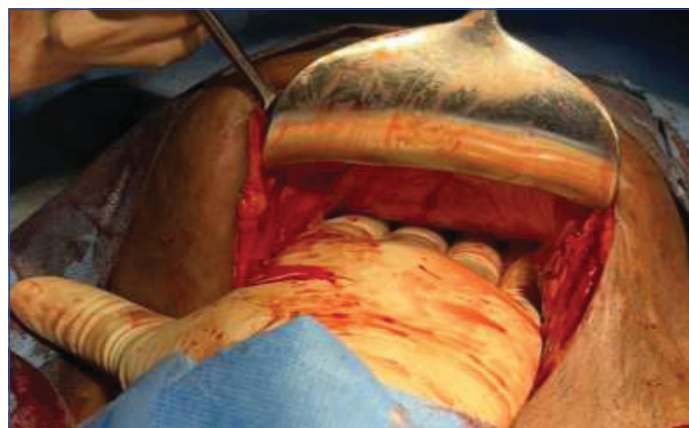Sample size: A sample size of 108 women was calculated based on the study conducted by Sravani P et al., using VAS score for postoperative pain at 12 hours [2].

These 108 women were allocated either to the study or control group using an opaque envelope method. In this single-blinded study, the participants were blinded to their allocation to the study or control group.

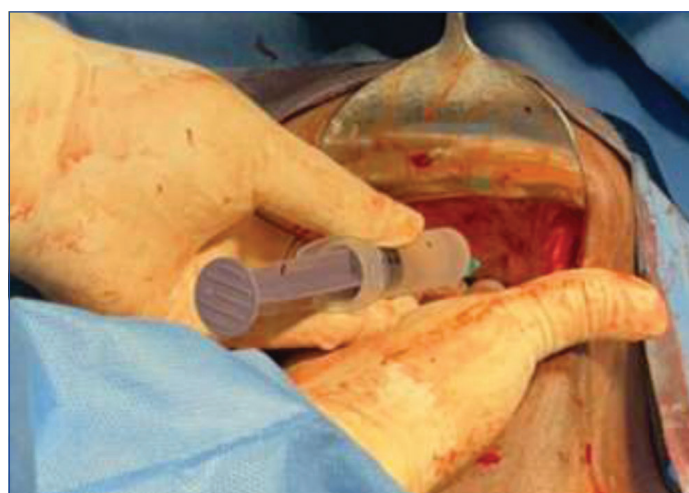
Procedure

After completion of the surgical procedure and before closing the abdomen, surgical TAP block was given by the operating surgeon. An assistant elevated the anterior abdominal wall so that the surgeon could visualise and palpate the lateral border of the rectus muscle at the level of the umbilicus, on one side [Table/Fig-2]. Safe entry into TAP was ensured by inserting a blunt needle (BD Blunt needle, 18G) through the parietal peritoneum just lateral (1 cm)

to the lateral border of the rectus muscle. This was necessary to avoid injury to the inferior epigastric vessels. The needle was gently advanced until there was an appreciable loss of resistance (one 'pop'), indicating piercing of the transversus muscle fascia. After careful aspiration to ensure that no vascular injury had occurred, 20 mL 0.25% bupivacaine with 4 mg of dexamethasone was injected slowly without any undue resistance [Table/Fig-3]. A similar procedure was repeated on the opposite side, and then the surgeon proceeded to close the abdomen. The time of the end of surgery was noted when the last skin suture was secured. Patients in both groups received a diclofenac 100 mg rectal suppository before shifting to the postoperative ward.



[Table/Fig-2]: Doyen's retractor is used to retract the anterior abdominal wall, for better visualisation and palpation of lateral border of rectus muscles.



[Table/Fig-3]: A blunt needle (18G) is inserted through the parietal peritoneum, lateral to the left lateral border of rectus muscle, at the level of umbilicus. It is gently advanced further until there is an appreciable loss of resistance ('one pop'), indicating piercing of the transversus muscle fascia. 20 mL of 0.25% Bupivacaine + 4 mg of dexamethasone is injected, into this transversus abdominis plane. The procedure was repeated on the opposite side.

The end of surgery time was used as a reference point for the calculation of the time of the request for the first rescue analgesia and the total dose of tramadol used within 24 hours of surgery. Participants in the control group received intravenous injection tramadol 50 mg, eight hourly for pain relief. Study group participants did not receive any further analgesic until they requested it. All participants were monitored postoperatively for the severity of pain, sedation, nausea, and vomiting. Postoperative pain was assessed using VAS Scores (i.e., 0-no pain, 5-worst imaginable pain) at 60 minutes, 2 hours, 4 hours, 6 hours, 12 hours, and 24 hours after surgery and SOS whenever a patient demanded analgesia. If the VAS score was 3 or more, rescue analgesia with intravenous injection tramadol 50 mg was administered, and the time for the first analgesic request was recorded. The total dose of rescue analgesics needed within the first 24 hours was also recorded for each participant. The occurrence of any other

postoperative complications like haematoma, visceral trauma was also recorded.

STATISTICAL ANALYSIS

Observed data were entered in MS Excel and analysed using SPSS version 25.0. For descriptive analysis, categorical data were analysed using percentages, and continuous data were analysed using the mean and standard deviation. For inferential statistics, numerical data were analysed by the Chi-square test, and for continuous data, Student's t-test and ANOVA were used. A p-value <0.05 was considered statistically significant.

RESULTS

The study group and control group participants were well matched with regards to their age, height, and weight, and the difference was statistically not significant [Table/Fig-4]. Most of the participants undergoing caesarean delivery could not recall their pre-pregnancy weight; hence, BMI could not be assessed.

Variables	Study	Control	t value	p-value
	Mean±Std. Dev	Mean±Std. Dev		
Age (years)	31.00±9.467	30.15±9.62	0.215	0.644
Height (cm)	155.35±4.29	160.56±8.45	14.718	0.109
Weight (kg)	65.47±8.51	63.79±10.80	0.805	0.372

[Table/Fig-4]: Association of demographic details-age, height and weight among study and control group.

The study group had significantly lower VAS scores compared to the control group at four hours and beyond time intervals, highlighting the efficacy of longer duration of pain relief with surgical TAP block [Table/Fig-5].

VAS score	Study group	Control group	p-value
	Mean±Std. Deviation	Mean±Std. Deviation	
1 h	1.26±0.78	0.85±0.36	0.001
2 h	1.52±0.79	1.13±0.58	0.005
4 h	1.81±0.97	2.54±0.86	0.001
6 h	1.85±1.01	2.35±0.96	0.010
12 h	2.43±1.09	2.61±0.76	0.009
24 h	2.04±0.83	2.24±0.99	0.044

[Table/Fig-5]: Postoperative pain using VAS. t-test was used

The mean time to request for the first rescue analgesia was significantly delayed in the study group (11 hours 25 minutes) compared to the control group (2 hours 43 minutes) (p-value <0.001). In the control group, the mean total analgesic (tramadol) required within the first 24 hours was 117.59±36.55 mg, whereas in the study group, the requirement was reduced to 77.78±46.24 mg. The total analgesic (tramadol) required for patients in the study group within the first 24 hours of surgery was around 40% less than that utilised in the control group, and this difference was statistically highly significant (p-value <0.001) [Table/Fig-6].

Time	Study group	Control group	t value	p-value
	(Mean±Std. Dev)	(Mean±Std. Dev)		
1 st rescue analgesia in hours	11:25±6:55	2:43±1:19	9.09	p<0.001
Total analgesic dose required in first 24 hours	77.78±46.24 (mg)	117.59±36.55 (mg)	24.641	p<0.001

[Table/Fig-6]: Mean time to first rescue analgesia and total analgesia (Tramadol) required in 1st 24 hours.

Seven (12.96%) participants from the study group did not require any postoperative rescue analgesia within the first 24 hours of surgery. There was no difference in the outcome when surgical TAP block was administered by surgeons with varying levels of professional

experience [Table/Fig-7]. This suggests that surgical TAP block is easy to learn and administer. Surgical TAP block could be performed with ease in all lower abdominal gynecological surgeries. There was no difficulty encountered in administering surgical TAP block in obese patients, as well as in obstetric cases with a lax abdomen. There was no drug-related complications like infection or haematoma or any adverse effects of bupivacaine in the study.

Doctors	N	Time of first rescue analgesia	F value	p-value
		Mean±Std. Deviation (Hours:minutes)		
Professor	8	13:21±7:52	0.4784	0.622
Assistant Professor	26	10:43±7:52		
Junior Resident	20	11:04±6:12		
Total	54	11:25±6:55		

[Table/Fig-7]: Ease of performance. ANOVA test was used

DISCUSSION

The study group had significantly lower VAS scores compared to the control group at four hours and beyond. This was attributed to the efficacy of the surgical TAP block procedure. Similar results were seen in studies conducted by Sravani P et al., and Kakade A and Wagh G both the studies involved surgical TAP block given to 100 women who underwent caesarean delivery [2,7]. Lower postoperative VAS scores were also reported by Geng ZY et al., [11] with the preoperative US-guided TAP block technique and Kahsay DT et al., with the postoperative blind TAP block technique [3]. Similar results are also seen in a study conducted by Carney J et al., which included 50 females who underwent elective total abdominal hysterectomy and TAP block using ropivacaine [4]. This is a testimony to the efficacy of TAP block in providing postoperative pain relief, irrespective of the technique used.

Low VAS scores signify the patients' comfort level due to effective postoperative pain relief. This single measure has been shown to encourage early mobilisation and thereby reduce the risk of thromboembolic disease in postoperative patients [12]. Hence, a simple intraoperative intervention like the surgical TAP block has a major role to play in postoperative patient care.

In present study, 20 mL of 0.25% bupivacaine with the addition of 4 mg of dexamethasone for giving the surgical TAP block on either side was used. The mean time to request for the first rescue analgesia was 11 hours 25 minutes, while it was 2 hours 43 minutes in the control group. Some other studies have reported varying durations of postoperative analgesia with the TAP block. Kakade A and Wagh G reported the effects of surgical TAP block given using 0.25% bupivacaine alone. They reported the duration of postoperative analgesia in the study group as 5.14±1.63 hours and 2.61±0.89 hours in the control group [7]. Sravani P et al., also studied surgical TAP block using 0.25% bupivacaine alone and reported a duration of postoperative analgesia in the study group as 11.7±7.344 hours in the study group and 2.1±1.125 hours in the control group [2]. The addition of dexamethasone to bupivacaine in present study enhanced the duration of postoperative analgesia of the surgical TAP block.

Støving K et al., noted that the duration of US-guided unilateral TAP block with 20 mL 7.5 mg/mL ropivacaine was about 10 hours with a wide variation [13]. Adding dexamethasone as an adjuvant to ropivacaine was associated with improved postoperative pain relief [10].

The use of opioids for postoperative pain relief is fraught with dose-related adverse side-effects such as nausea, vomiting, and respiratory depression. TAP block is one intervention that can

provide effective postoperative pain relief while simultaneously reducing the total dose of opioids needed for pain relief in the postoperative period [11,14]. In present study, the total tramadol required within the first 24 hours of surgery was 117.59 ± 36.55 mg in the control group and 77.78 ± 46.24 mg in the study group. There was a substantial reduction in the total amount of opioid use within 24 hours of surgery in the study group (p -value < 0.001). Other studies have also reported a similar reduction in the total amount of opioids required for postoperative pain relief with TAP block. The study by Mrunalini P et al., included 60 adult patients undergoing emergency laparotomy, and the study by Srivastava U et al., included 62 women who underwent caesarean delivery with TAP block, both reporting similar results [Table/Fig-8] [2,7,15,16]. Geng ZY et al., also reported similar results when US-guided TAP block was given with ropivacaine [11]. A meta-analysis of randomised controlled trials concerning the efficacy of TAP block for pain control also reported a similar reduction in opioid consumption and incidence of postoperative nausea and vomiting after surgery [17].

Study	VAS score post-op in study group	Time of rescue analgesia Study (S)/ Control (C)	Total tramadol required Study (S)/Control (C)	Drug and dose	Complications
Present study	Significant	S: 11:25±6:55 (Hours: minutes)	S: 77.78±46.24 mg	20 mL 0.25% bupivacaine with 4 mg of dexamethasone	None
		C: 2:43±1:19 (Hours: minutes)	C: 117.59±36.55 mg		
Sravani P et al., [2]	Significant	S: 11:7±7:344 (Hours)	S: 50±28.571 mg	20 mL 0.25% bupivacaine	None
		C: 2:1±1:125 (Hours)	C: 180±26.726 mg		
Kakade A and Wagh G [7]	Significant	S: 5.14±1.63 (Hours)		0.25 mL/kg of 0.25% bupivacaine	None
		C: 2.61±0.89 (Hours)			
Mrunalini P et al., [15]	Significant		S: 281.33±69.66 mg	20 mL 0.25% bupivacaine	None
			C: 439±68.59 mg		
Srivastava U et al., [16]	Significant	S: 12 (Hours)	S: 75±22 mg	20 mL 0.25% bupivacaine	None
		C: 6 (Hours)	C: 168±45 mg		

[Table/Fig-8]: Comparison of 'Study group' results with similar studies [2,7,15,16].

There are various studies reporting the wide application of TAP block in various abdominal surgeries, such as unilateral TAP block in appendectomy patients using ropivacaine 0.75% [6]. Another study included patients who underwent right hemicolectomy for colonic cancer and open TAP block with 0.5% levobupivacaine [5]. These studies also reported a reduction in opioid analgesics used in the first 24 hours postoperatively, and there were no recorded complications attributable to the TAP block procedure.

Studies comparing Surgical TAP Block with US-guided TAP block reported technical difficulties in obese patients with US probe placement and distinction of the abdominal muscle layers. The needle-related visceral organ damage during US-guided TAP block can be negated by visualising the visceral organs during the surgical TAP block procedure [18].

There was no significant difference noted in the outcome of TAP block when administered by surgeons with varying levels of professional experience. This implies that the surgical TAP block technique is easy to learn and perform. Similar results were reported in the study by Sravani P et al., [2]. Surgical TAP block with bupivacaine and dexamethasone is a safe and easy method

of delivering postoperative analgesia and should be an important component of postoperative multimodal analgesia.

Limitation(s)

Studies suggest that TAP block may provide insufficient analgesia in midline abdominal incisions as the drug distribution may not cross the midline [13]. However, this aspect of TAP block was not evaluated in present study as all the patients received bilateral TAP block. Additionally, present study evaluated a single anaesthetic drug with a single dose and concentration for all patients. Larger studies will be needed to evaluate different doses and concentrations of various drugs to determine the ideal combination.

CONCLUSION(S)

Surgical TAP block is an effective, safe, and easy method for managing postoperative analgesia. It significantly delays the need for rescue analgesia and reduces the total dose of postoperative analgesics required within the first 24 hours of surgery. This low-cost technique of surgical TAP block makes it an essential tool in the armamentarium of every doctor performing lower abdominal surgeries.

REFERENCES

- Dwivedi D, Bhatnagar V, Goje HK, Ray A, Kumar P. Transversus abdominis plane block: A multimodal analgesia technique-our experience. *J Mar Med Soc.* 2017;19(1):38-42.
- Sravani P, Indrani C, Rajanna SP, Saxena RK. Efficacy of surgical transversus abdominis plane block in patients undergoing cesarean delivery. *J South Asian Feder Obst Gynae.* 2020;12(5):302-06.
- Kahsay DT, Elsholz W, Bahta HZ. Transversus abdominis plane block after caesarean section in an area with limited resources. *South Afr J Anaesth Analg.* 2017;23(4):90-95. Doi: 10.1080/22201181.2017.1349361.
- Carney J, McDonnell JG, Ochana A, Bhinder R, Laffey JG. The transversus abdominis plane block provides effective postoperative analgesia in patients undergoing total abdominal hysterectomy. *Anaesth Analg.* 2008;107(6):2056-60. Doi: 10.1213/ane.0b013e3181871313.
- Brady RR, Ventham NT, Roberts DM, Graham C, Daniel T. Open transversus abdominis plane block and analgesic requirements in patients following right hemicolectomy. *Ann R Coll Surg Engl.* 2012;94(5):327-30. Doi: 10.1308/003588412X13171221589856.
- Carney J, Finnerty O, Rauf J, Curley G, McDonnell JG, Laffey JG. Ipsilateral transversus abdominis plane block provides effective analgesia after appendectomy in children: A randomized controlled trial. *Anaesth Analg* 2010;111(4):998-1003. Doi: 10.1213/ANE.0b013e3181e7bba.
- Kakade A, Wagh G. Evaluate the feasibility of surgical transversus abdominis plane block for postoperative analgesia after cesarean section. *J Obstet Gynaecol India.* 2019;69(4):330-33.
- Owen DJ, Harrod I, Ford J, Luckas M, Gudimetla V. The surgical transversus abdominis plane block- A novel approach for performing an established technique. *BJOG.* 2011;118(1):24-27.
- Abdelwahab WAEM, Elzahaby HM, ElGendy HAA, Elwahab ATSA, Hussien RM. Safety and efficacy of dexamethasone as an adjuvant to bupivacaine in bilateral transversus abdominis plane block in children undergoing major abdominal surgery. *Ain-Shams J Anaesthesiol.* 2020;12:52. <https://doi.org/10.1186/s42077-020-00105-7>.
- Kartalov A, Jankulovski N, Kuzmanovska B, Zdravkovska M, Shosholcheva M, Spirovska T, et al. Effect of adding dexamethasone as a ropivacaine adjuvant in ultrasound-guided transversus abdominis plane block for inguinal hernia repair. *Pril (Makedon Akad Nauk Umet Odd Med Nauki).* 2015;36(3):35-41. Doi: 10.1515/prilozi-2015-0076. PMID: 27442394.
- Geng ZY, Zhang Y, Bi H, Zhang D, Li Z, Jiang L, et al. Addition of preoperative transversus abdominis plane block to multimodal analgesia in open gynecological surgery: A randomized controlled trial. *BMC Anaesthesiol.* 2023;23(1):21. <https://doi.org/10.1186/s12871-023-01981-w>.
- Gadsden J, Hart S, Santos AC. Post-cesarean delivery analgesia. *Anaesth Analg.* 2005;101(5 Suppl):S62-69.
- Stoving K, Rothe C, Rosenstock CV, Aasvang EK, Lundstrøm LH, Lange KH. Cutaneous sensory block area, muscle-relaxing effect, and block duration of the transversus abdominis plane block: A randomized, blinded, and placebo-controlled study in healthy volunteers. *Reg Anaesth Pain Med.* 2015;40(4):355-62. Doi: 10.1097/AAP.0000000000000252. PMID: 25923818.
- Young MJ, Gorlin AW, Modest VE, Quraishi SA. Clinical implications of the transversus abdominis plane block in adults. *Anaesthesiol Res Pract.* 2012;2012:731645. Doi: 10.1155/2012/731645. Epub 2012 Jan 19. PMID: 22312327; PMCID: PMC3270549.
- Mrunalini P, Rama Raju NV, Nath VN, Saheb SM. Efficacy of transversus abdominis plane block in patients undergoing emergency laparotomies. *Anaesth Essays Res.* 2014;8(3):377-82.
- Srivastava U, Verma S, Singh TK, Gupta A, Saxena A, Jagar KD, et al. Efficacy of trans abdominis plane block for post cesarean delivery analgesia: A double-blind, randomized trial. *Saudi J Anaesth.* 2015;9(3):298-302.

- [17] Wang W, Wang L, Gao Y. A meta-analysis of randomized controlled trials concerning the efficacy of transversus abdominis plane block for pain control after laparoscopic cholecystectomy. *Front Surg.* 2021;8:700318. Doi: 10.3389/fsurg.2021.700318.
- [18] Urfalioğlu A, Bakacak M, Boran ÖF, Yazar FM, Arslan M, Öksüz H. Ultrasound-guided versus surgical transversus abdominis plane block in obese patients following cesarean section: A prospective randomised study. *Rev Bras Anesthesiol [Internet].* 2017;67(5):480-86. Available from: <https://doi.org/10.1016/j.bjane.2016.07.009>.

PARTICULARS OF CONTRIBUTORS:

1. Junior Resident, Department of Obstetrics and Gynaecology, The Oxford Medical College Hospital, Bengaluru, Karnataka, India.
2. Professor and Head, Department of Obstetrics and Gynaecology, The Oxford Medical College Hospital, Bengaluru, Karnataka, India.
3. Assistant Professor, Department of Obstetrics and Gynaecology, The Oxford Medical College Hospital, Bengaluru, Karnataka, India.
4. Junior Resident, Department of Obstetrics and Gynaecology, The Oxford Medical College Hospital, Bengaluru, Karnataka, India.
5. Senior Resident, Department of Obstetrics and Gynaecology, The Oxford Medical College Hospital, Bengaluru, Karnataka, India.

NAME, ADDRESS, E-MAIL ID OF THE CORRESPONDING AUTHOR:

Dr. Rajiv Kumar Saxena,
The Oxford Medical College, Hospital and Research Centre, Yadavanahalli,
Attibele, Behind La Classic Hotel, Bengaluru-562107, Karnataka, India.
E-mail: dirrajivsaxena60@gmail.com

PLAGIARISM CHECKING METHODS: [\[Jain H et al.\]](#)

- Plagiarism X-checker: May 25, 2023
- Manual Googling: Jul 28, 2023
- iThenticate Software: Aug 08, 2023 (14%)

ETYMOLOGY: Author Origin

EMENDATIONS: 6

AUTHOR DECLARATION:

- Financial or Other Competing Interests: None
- Was Ethics Committee Approval obtained for this study? Yes
- Was informed consent obtained from the subjects involved in the study? Yes
- For any images presented appropriate consent has been obtained from the subjects. Yes

Date of Submission: **May 25, 2023**Date of Peer Review: **Jul 18, 2023**Date of Acceptance: **Aug 11, 2023**Date of Publishing: **Sep 01, 2023**