

Pyrogenic Granuloma Treated with Topical Timolol: A Case Series

MANJEET NARESH RAMTEKE¹, USHA NARAINDAS KHEMANI²

(CC) BY-NC-ND

ABSTRACT

Pyrogenic Granulomas (PGs) are benign vascular tumours primarily treated with surgical procedures. Recently, topical Timolol, a beta-adrenergic receptor antagonist, has been used for the treatment of PG due to its vasoconstrictive, anti-angiogenic, and wound healing properties. Herein, the authors presented a case series of 12 patients (10 males and two females) with red papules and nodules that spontaneously bleed. The age of the patients ranged from 7-51 years, and the duration of lesions ranged from one week to nine months. The lesions were located on the face, neck, hand, and mucosa. All patients were treated with topical Timolol maleate 0.5% drops twice daily for four weeks and followed-up weekly for four weeks. The treatment efficacy was evaluated based on complete response, partial response, or no response. Changes in colour, size, bleeding tendency, and adverse events were also assessed. Two patients showed complete resolution, while the bleeding tendency improved in the other patients. No side effects were encountered, except in one patient where the lesion increased in size and became secondarily infected. Thus, topical timolol appeared to provide symptomatic improvement by reducing bleeding and lesion size without any side effects. It can be considered as an alternative therapeutic option for small, uncomplicated classical PG.

Keywords: Beta adrenergic receptor antagonist, Efficacy, Vascular tumours

INTRODUCTION

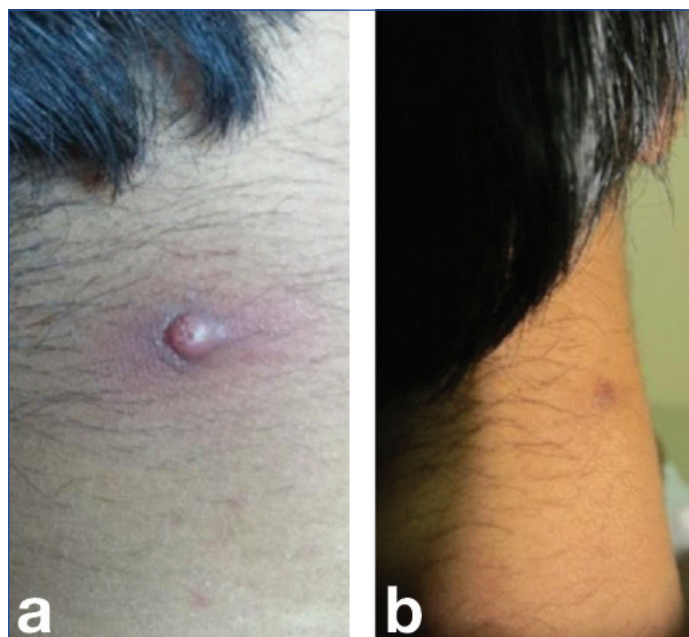
The PG, also known as lobular capillary haemangioma, is a benign acquired vascular tumour that presents as a solitary, red, rapidly growing papule or nodule on the skin and mucosa. Occasionally, it can be found subcutaneously or intravascularly [1]. The definitive cause of PGs is unknown, but factors such as low-grade chronic irritation, trauma, and hormonal imbalances may be associated with their development [2]. The natural course of the lesion can be categorised into three distinct phases: (i) early or cellular phase, (ii) established or capillary phase/vascular phase, and (iii) healing or involutionary phase [2]. The disease can affect people of all age groups and is quite common in children and young adults, but there is no clarity on the male:female ratio [3]. Various therapeutic modalities for PG include shave removal, surgical excision, curettage, chemical or electrocauterisation, cryotherapy, sclerotherapy, microembolisation, laser [4,5], and topical imiquimod [6]. However, these procedures are invasive and can result in scarring and recurrence.

Topical timolol is a newly developing non invasive modality of treatment for PG. It is a non selective beta-adrenergic receptor antagonist that has recently been used for the treatment of superficial infantile haemangiomas [7]. The mechanism of action of timolol in vascular tumours involves vasoconstriction by blocking nitric oxide release, anti-angiogenesis by inhibiting the synthesis of proangiogenic factors such as Vascular Endothelial Growth Factor (VEGF) and basic Fibroblast Growth Factor (bFGF), and apoptosis of proliferating endothelial cells via Src tyrosine kinase, Mitogen-activated Protein Kinase (MAPK), and caspase cascades [8,9].

Additionally, it has been found to enhance cutaneous wound healing by increasing the rate of keratinocyte galvanotaxis and single cell migration, ultimately accelerating skin re-epithelialisation of chronic refractory wounds [10]. Although topical timolol appears effective in treating PG, the response is not universal as in infantile haemangioma [11]. It has a gradual effect on treating PGs, and the treatment period may take more than six weeks, but it can avoid the adverse effects of other treatments, including scar formation, and eliminate the need for local or general anaesthesia [12,13].

Case 1

A 24-year-old male patient presented in the Department of Dermatology with an asymptomatic red raised lesion that spontaneously bled on the neck following trauma for the past three months. There was no history of medical or surgical illness. Cutaneous examination revealed an erythematous papule with a diameter of 4 mm on the posterior aspect of the neck [Table/Fig-1a]. The patient showed complete resolution after two weeks of topical timolol treatment, resulting in post-inflammatory hyperpigmentation [Table/Fig-1b]. The patient did not experience any adverse effects. At the three-month follow-up, the patient remained lesion-free.

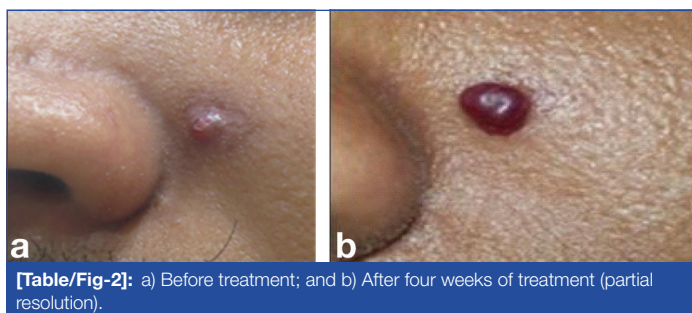


[Table/Fig-1]: Lesion on neck showing complete response: a) Before treatment; and b) After two weeks of treatment.

Case 2

A 23-year-old male patient presented in the Department of Dermatology with an asymptomatic red raised lesion on the left

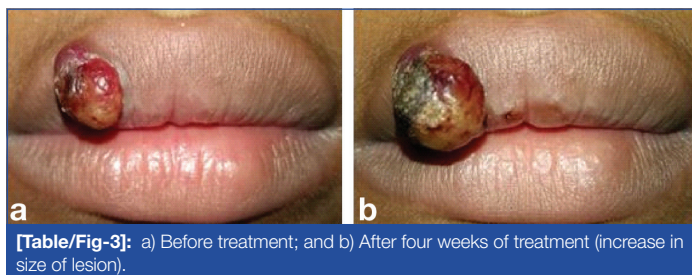
cheek for the past four weeks. There was no history of medical or surgical illness. Cutaneous examination revealed an erythematous papule with a diameter of 5 mm on the left cheek near the nose [Table/Fig-2a]. The patient showed partial resolution after four weeks of topical timolol treatment [Table/Fig-2b]. There was a decrease in the size of the lesion and bleeding. The patient did not experience any adverse effects. The lesion was subsequently electrocauterised after four weeks of treatment.



[Table/Fig-2]: a) Before treatment; and b) After four weeks of treatment (partial resolution).

Case 3

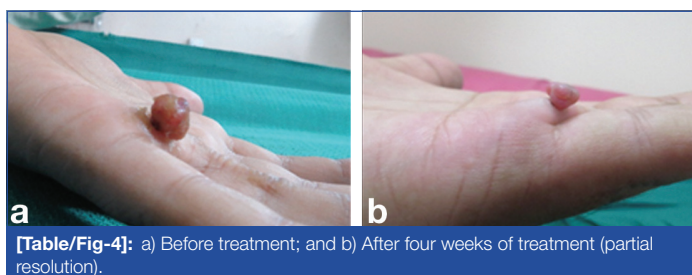A 15-year-old male patient presented in the Department of Dermatology with an asymptomatic red raised lesion with a history of bleeding on the right side of the upper lip for the past three weeks. There was no history of medical or surgical illness. Cutaneous examination revealed an erythematous nodule with a diameter of 8 mm and crusting on the upper lip [Table/Fig-3a]. The patient showed no response after four weeks of treatment. In fact, the lesion increased in size and became secondarily infected [Table/Fig-3b]. The patient was given a course of oral antibiotics, and the lesion was surgically excised.



[Table/Fig-3]: a) Before treatment; and b) After four weeks of treatment (increase in size of lesion).

Case 4

A 32-year-old male patient presented in the Department of Dermatology with an asymptomatic red raised lesion with occasional bleeding on the left palm for seven days. There was no history of medical or surgical illness. Cutaneous examination revealed an erythematous papule with a diameter of 8 mm on the left palm [Table/Fig-4a]. The patient showed partial resolution after four weeks of topical timolol treatment [Table/Fig-4b]. There was a decrease in the size of the lesion as well as bleeding. The patient did not experience any adverse effects. The lesion was subsequently electrocauterised after four weeks of treatment.

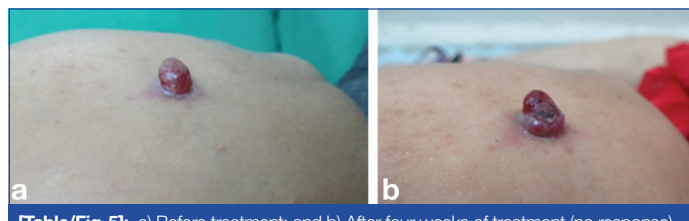


[Table/Fig-4]: a) Before treatment; and b) After four weeks of treatment (partial resolution).

Case 5

A 32-year-old female presented in the Department of Dermatology with an asymptomatic red raised lesion that would bleed upon manipulation over the right mandibular area for the past four weeks. There was no history of medical or surgical illness.

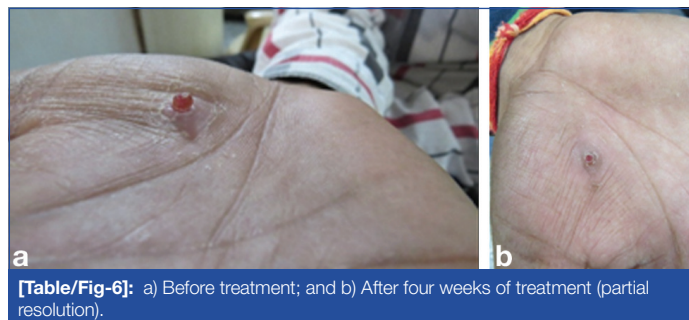
Cutaneous examination revealed an erythematous papule with a diameter of 6 mm on the right mandibular area [Table/Fig-5a]. The patient showed no resolution, but there was a decrease in bleeding after four weeks of topical timolol treatment [Table/Fig-5b]. She did not experience any adverse effects. The lesion was subsequently electrocauterised after four weeks of treatment.



[Table/Fig-5]: a) Before treatment; and b) After four weeks of treatment (no response).

Case 6

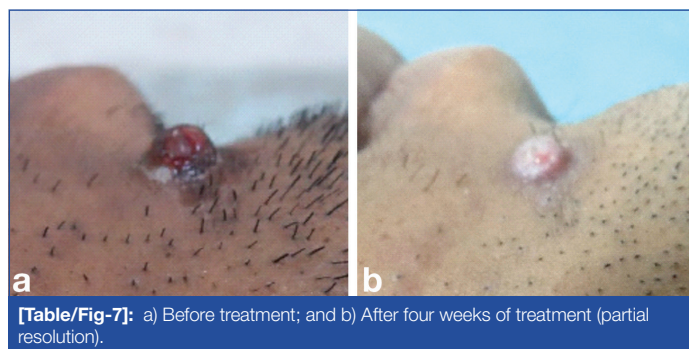
A 19-year-old male presented in the Department of Dermatology with an asymptomatic red raised lesion with a history of bleeding on the right palm for the past four weeks. There was no history of medical or surgical illness. Cutaneous examination revealed an erythematous papule with a diameter of 4 mm on the right palm [Table/Fig-6a]. The patient showed partial resolution with a decrease in the size of the lesion and bleeding after four weeks of topical timolol treatment [Table/Fig-6b]. The patient did not experience any adverse effects. The lesion was subsequently electrocauterised after four weeks of treatment.



[Table/Fig-6]: a) Before treatment; and b) After four weeks of treatment (partial resolution).

Case 7

A 23-year-old male patient presented in the Department of Dermatology with an asymptomatic red raised lesion on the right side of the chin for the past nine months. There was no history of medical or surgical illness. Cutaneous examination revealed an erythematous papule with a diameter of 5 mm on the right side of the chin [Table/Fig-7a]. The patient showed partial resolution with a decrease in the size of the lesion after four weeks of topical timolol treatment [Table/Fig-7b]. The patient did not experience any adverse effects. The lesion was subsequently electrocauterised after four weeks of treatment.

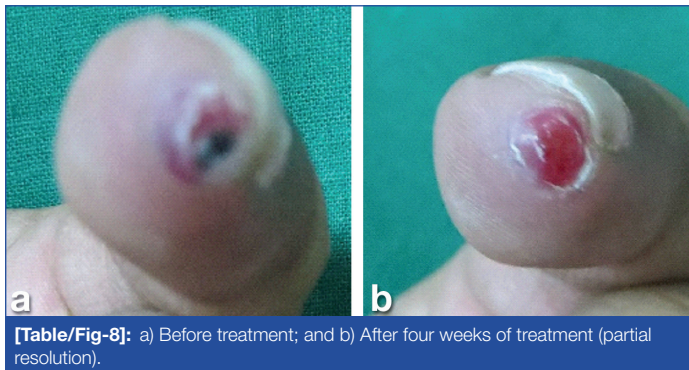


[Table/Fig-7]: a) Before treatment; and b) After four weeks of treatment (partial resolution).

Case 8

A 22-year-old male patient presented in the Department of Dermatology with an asymptomatic red raised lesion with occasional bleeding on the right little finger for the past two months. There was no history of medical or surgical illness. Cutaneous examination

revealed an erythematous papule with a diameter of 5 mm on the right little finger [Table/Fig-8a]. The patient showed partial resolution with a decrease in the size of the lesion and bleeding after four weeks of topical timolol treatment [Table/Fig-8b]. He did not experience any adverse effects. The lesion was subsequently electrocauterised after four weeks of treatment.



[Table/Fig-8]: a) Before treatment; and b) After four weeks of treatment (partial resolution).

Case 9

A seven-year-old female patient presented in the Department of Dermatology with an asymptomatic red raised lesion with a history of occasional bleeding on the back area for the past two weeks. There was no history of medical or surgical illness. Cutaneous examination revealed an erythematous papule with a diameter of 3 mm present on the left scapular area. The lesion showed complete resolution after four weeks. The patient did not experience any adverse effects, except for post-inflammatory hyperpigmentation.

Case 10

A 27-year-old male presented in the Department of Dermatology with an asymptomatic red raised lesion with a history of occasional bleeding on the right temporal area for the past four weeks. There was no history of medical or surgical illness. Cutaneous examination revealed an erythematous papule with a diameter of 6 mm present on the right temporal area. He showed

no resolution, only a decrease in bleeding after four weeks of topical timolol treatment. The patient did not experience any adverse effects. The lesion was later electrocauterised after four weeks of treatment.

Case 11

A 50-year-old male patient presented in the Department of Dermatology with an asymptomatic red raised lesion with occasional bleeding on the right index finger for the past four weeks. There was no history of medical or surgical illness. Cutaneous examination revealed an erythematous papule with a diameter of 6 mm. The patient did not experience any adverse effects from topical timolol. The lesion was subsequently electrocauterised after four weeks of topical Timolol.

Case 12

A 26-year-old male patient presented with asymptomatic red raised lesion which used to bleed over left temporal area since six weeks. There was no history of medical or surgical illness. Cutaneous examination revealed an erythematous papule of 3 mm diameter with crusting present on temporo-occipital area. The patient showed no resolution after four weeks of topical timolol treatment. The patient did not have any adverse effects. The lesion was electrocauterised after four weeks of treatment. The details of all the patients included in the present study shown in [Table/Fig-9].

DISCUSSION

The management of PG is mostly surgical but owing to the adverse effect of scar formation, topical therapies like topical corticosteroid [3], topical imiquimod [6] and topical beta blocker [13] have been used. The overall response of topical timolol in PG in the present case series was satisfactory with no adverse effects. Millsop JW et al., first used topical timolol in a 39-year-old male with recalcitrant PG with complete resolution but it was combined with aggressive laser therapy and intralesional triamcinolone acetonide injections [3]. Later many case reports and case series have been published [Table/Fig-10] [3,4,11-23]. Most of the studies were done in children

Case no.	Age/Sex	Site	Duration	Diameter (in mm)	Result	Recurrence	Further intervention
1	24/M	Neck	7 months	4	CR (2 weeks)	None at 3 months	-
2	23/M	Left cheek	1 month	5	PR		Electrocauterised
3	15/M	Upper lip	3 weeks	8	NR		Surgically excised
4	32/M	Left palm	7 days	8	PR		Electrocauterised
5	32/F	Right mandibular area	1 month	6	NR		Electrocauterised
6	19/M	right palm	1 month	4	PR		Electrocauterised
7	23/M	Right side of chin	9 months	5	PR		Electrocauterised
8	22/M	Right little finger	2 month	5	PR		Electrocauterised
9	7/F	Back	2 weeks	3	CR	None at 3 months	-
10	27/M	Right temporal area	1 month	6	NR		Electrocauterised
11	50/M	Right index finger	1 month	6	NR		Electrocauterised
12	26/M	Left temporal area	6 weeks	3	NR		Electrocauterised

[Table/Fig-9]: Details all the patients included in the study.

CR: Complete response; PR: Partial response; NR: No response

Authors and year of the study	Timolol (%)	n	Age	Rx duration	Result	Side-effects	Recurrence	Remarks
MillsopJ et al., 2014 [3]	0.5	1	39 years	3 months	CR after 3 months	No	No (after 6 months)	Topical timolol was combined with intralesional steroid and laser
Chiriac A et al., 2016 [4]	0.1	2	13 months-two years	2 weeks	CR	No	No (after long-term f/u)	Combined Rx with TCA children
Gupta D et al., 2016 [11]	0.5	10	15-50 years	-	4-CR (3 days-3 weeks)	No	No (after 3 months)	Adults variable results
Okel et al., 2017 [12]	0.5	4	3-10 years	3 weeks	CR after 3 months	No	No (after 3 months)	Eye children

Khorsand K et al., 2015 [13]	0.5	1	5 months	4 weeks	CR	No	No (after 7 month)	Child
Knöpfel N et al., 2016 [14]	0.5	1	2 years	4 weeks	CR after 4 weeks	No	Not reported	Child
Del Pozzo-Magaña B et al., 2014 [15]	0.5	1	3 years	6 months	CR after 6 months	No	No (after 3 months)	Child
Lee L et al., 2014 [16]	0.5-2	6	2-8 years	6 weeks-6 months	4-CR 2-PR	No	Not reported	Study done on children
Malik M and Murphy R, 2014 [17]	0.5	1	14 years	3 weeks	CR	No	No (after 7 months)	Child
McGinness A et al., 2018 [18]	0.5	3	7 months-12 years	3 months-52 months	1-CR after 3 months	No	Recurred which self resolved	Not uniform results in all the three children
Sollena P et al., 2019 [19]	0.5	9 (25 lesions)	58-83 years	Not mentioned	13-C after one month	No	No (after 7.1 month)	-
El Taweel AEI et al., 2020 [20]	0.5	10	28.1 years	2 months	2-CR after 2 months	No	No (after 3 months)	-
Luca P et al, 2020 [21]	0.5	1	10 years	3 months	CR after 3 months	No	No (after 3 months)	Child
Williams N and Morrison B 2020 [22]	0.5	1	62 years	10 weeks	CR after 10 weeks	No	Not mentioned	Other topical like topical steroid and topical antifungal were used
Patra AC et al., 2022 [23]	0.5	22	Mean 30.2 years	6 weeks	2-CR after six weeks	No	No follow-up	-
Present case series	0.5	13	7-51 years	4 weeks	2-CR (after 2 weeks)	No	No (after 3 months)	

[Table/Fig-10]: Details of case reports and series [3,4,11-23].
TCA: Tricyclic antidepressant

[12-23]. It was found that effect of topical timolol is not uniform in every patient in the present series. This is consistent with a similar study done by Gupta D et al., where they have concluded that the response of PGs to beta-blockers seems to be variable [11]. This can be attributed to expression of only 50% β -adrenergic receptor in PG [24]. However, most of the lesions showed decrease in size and vascularity in present study.

The usual dose of topical timolol 0.5% drops twice daily has been used with no side-effect in the study. However, dosage higher than twice daily that is four times a day has been used by Gupta D et al., without any side-effects [11]. Topical timolol have been used in combination with intralesional steroid, laser therapy and trichloroacetic acid resulting in complete resolution [3,4]. Thus, it can be used in combination other modalities with better response as the various key mechanisms that are implicated in the pathogenesis of PG can be targeted. It is safe, easy to use and has better cosmetic results without any adverse effects. It may be used as an alternative and non invasive therapeutic option for small, uncomplicated typical PG. It can be used when other treatment modalities are challenging or could lead to significant scarring.

Limitation(s)

There is still a need for adequate protocol for dosing (once, twice, thrice or four times) and treatment duration as there is no uniform protocol for the same in previous reported case series and studies and so multicentric randomised controlled trials with long-term follow-up are required. The limitation of the present case series is lack of long-term follow-up.

CONCLUSION(S)

Topical timolol appeared to provide symptomatic improvement in the form of no bleeding and reduction in the size of lesion. This is an effective therapy option for PGs, and may also be considered as a regular treatment for smaller lesions in children and adults.

REFERENCES

- Wollina U, Langner D, França K, Gianfaldoni S, Lotti T, Tchernev G. Pyogenic granuloma— a common benign vascular tumor with variable. *Open Access Maced J Med Sci.* 2017;5(4):423-26.
- Marla V, Shrestha A, Goel K, Shrestha S. The histopathological spectrum of pyogenic granuloma. *Case Rep Dent.* 2016;2016:1323798.
- Millsop JW, Trinh N, Winterfield L, Berrios R, Hutchens K, Tung R. Resolution of recalcitrant pyogenic granuloma with laser, corticosteroid, and timolol therapy. *Dermatology Online Journal.* 2014;20(3):doj_21726.
- Chiriac A, Birsan C, Podoleanu C, Moldovan C, Brzezinski P, Stolnicu S. Noninvasive treatment of pyogenic granulomas in young children with topical Timolol and trichloroacetic acid. *J Pediatr.* 2016;169:322.
- Rai S, Kaur M, Bhatnagar P. Laser: A powerful tool for treatment of pyogenic granuloma. *J Cutan Aesthet Surg.* 2011;4(2):144-47.
- Tritton S, Smith S, Wong L, Zagarella S, Fischer G. Pyogenic granuloma in ten children treated with topical imiquimod. *Pediatric Dermatology.* 2009;26(3):269-72.
- Pope E, Chakkittakandiyil A. Topical Timolol gel for infantile hemangiomas: A pilot study. *Arch Dermatol.* 2010;146(5):564-65.
- Weissenstein A, Straeter A, Villalon G, Bittmann S. Topical timolol for small infantile hemangioma: A new therapy option. *Türk J Pediatr.* 2012;54(2):156-58.
- Storch C, Hoeger P. Propranolol for infantile haemangiomas: Insights into the molecular mechanisms of action. *British Journal of Dermatology.* 2010;163(2):269-74.
- Pullar C, Rizzo A, Isseroff R. β -Adrenergic receptor antagonists accelerate skin wound healing. *Journal of Biological Chemistry.* 2006;281(30):21225-35.
- Gupta D, Nidhi Singh N, Thappa D. Is timolol an effective treatment for pyogenic granuloma. *International Journal of Dermatology.* 2016;55(5):592-95.
- Oke I, Alkharashi M, Petersen R, Ashenberg A, Shah A. Treatment of ocular pyogenic granuloma with topical timolol. *JAMA Ophthalmol.* 2017;135(4):383-85.
- Khorsand K, Maier M, Brandling-Bennett HA. Pyogenic granuloma in a 5-month-old treated with topical timolol. *Pediatr Dermatol.* 2015;32(1):150-51.
- Knöpfel N, Góngora M, Bauzà A, Santiago A. Timolol for the treatment of pyogenic granuloma (PG) in children. *J Am Acad Dermatol.* 2016;75(3):e105-06.
- Del Pozzo-Magaña B, Lara-Corrales I. Topical timolol for pyogenic granuloma in a child: A case report and literature review. *Adv Pediatr Res.* 2014;1:01-03.
- Lee L, Goff K, Lam J, Low D, Albert C, Yan A, Castelo-Soccio L. Treatment of pediatric pyogenic granulomas using β adrenergic receptor antagonists. *Pediatr Dermatol.* 2014;31(2):203-07.
- Malik M, Murphy R. A pyogenic granuloma treated with topical Timolol. *Br J Dermatol.* 2014;171(6):1537-38.
- McGinness A, Gillam A, Yeh I, Mathes EF. Topical timolol: An effective treatment option for agminated pyogenic granuloma. *Pediatr Dermatol.* 2018;35(5):e300-e303.
- Sollena P, Mannino M, Tassone F, Calegari MA, D'Argento E, Peris K. Efficacy of topical beta-blockers in the management of EGFR-inhibitor induced paronychia and pyogenic granulomalike lesions: Case series and review of the literature. *Drugs in Context.* 2019;8:212613.
- El-Taweel AEI, Al-Refaie AAA, Salem KHA, Salem RM. Topical β -blockers for pyogenic granulomas: A promising option for younger patients. *J Cosmet Dermatol.* 2021;20(6):1801-06.
- Luca P, Filomena R, Paolo T, Pietro R. Treatment of childhood pyogenic granuloma of the nail bed with topical Timolol. *Dermatol Ther.* 2020;33(4):e13710.
- Williams N, Morrison B. Treatment of chemotherapy-induced subungual pyogenic granuloma with topical timolol solution. *Skin Appendage Disord.* 2021;7(1):62-65.

- [23] Patra AC, Sil A, Ahmed SKS, Rahaman S, Mondal N, Roy S, et al. Effectiveness and safety of 0.5% Timolol solution in the treatment of pyogenic granuloma: A randomized, double-blind and placebo-controlled study. *Indian J Dermatol Venereol Leprol.* 2022;88(4):500-08.
- [24] Chisholm K, Chang K, Truong M, Kwok S, West R, Heerema-McKenney A. Betaadrenergic expression in vascular tumors. *Mod Pathol.* 2012;25:1446-51.

PARTICULARS OF CONTRIBUTORS:

1. Associate Professor, Department of Dermatology, Venereology and Leprosy, Grant Government Medical College, Mumbai, Maharashtra, India.
2. Associate Professor, Department of Dermatology, Venereology and Leprosy, Grant Government Medical College, Mumbai, Maharashtra, India.

NAME, ADDRESS, E-MAIL ID OF THE CORRESPONDING AUTHOR:

Dr. Manjeet Naresh Ramteke,
Associate Professor, Department of Dermatology, OPD No. 42, Skin OPD,
2nd Floor, JJ Hospital Campus, Byculla, Mumbai-400008, Maharashtra, India.
E-mail: manjeetramteke@gmail.com

PLAGIARISM CHECKING METHODS: [\[Jain H et al.\]](#)

- Plagiarism X-checker: Sep 12, 2022
- Manual Googling: Dec 16, 2022
- iThenticate Software: Sep 14, 2023 (8%)

ETYMOLOGY: Author Origin**EMENDATIONS:** 7**AUTHOR DECLARATION:**

- Financial or Other Competing Interests: None
- Was informed consent obtained from the subjects involved in the study? Yes
- For any images presented appropriate consent has been obtained from the subjects. Yes

Date of Submission: **Sep 02, 2022**Date of Peer Review: **Nov 07, 2022**Date of Acceptance: **Sep 15, 2023**Date of Publishing: **Oct 01, 2023**