

Rhodotorula Meningitis in a HIV-2 Seropositive Patient: A Case Report

ASHISH KHANNA, MENKA KHANNA, ARUNA AGGARWAL

ABSTRACT

Rhodotorula, a common saprophyte has recently emerged as an opportunistic pathogen in immunocompromised patients. Meningitis caused by Rhodotorula species in HIV-1 infected patients have been reported rarely but Rhodotorula infection in HIV-2 infected patient has not been reported till date. We present a case of meningitis caused by Rhodotorula rubra in a patient

infected with HIV-2 virus. The diagnosis of the patient was confirmed by cell cytology, gram staining and culture of the CSF. Contamination was ruled out by repeated culturing from different samples from the same patient. Therapy with Amphotericin B showed good results and the patient was discharged after recovery.

Key Words: Opportunistic infections, Human immunodeficiency virus, *Rhodotorula* species, Meningitis

INTRODUCTION

Improvement in the therapeutic and diagnostic capabilities with the advent of invasive surgical procedures and immunosuppression predispose to a number of opportunistic pathogens. Most of the fungal infections are caused by the common fungal pathogens such as the *Candida* species, the *Aspergillus* species, *Histoplasma capsulatum*, *Blastomyces dermatitidis*, *Coccidioides immitis* and *Cryptococcus neoformans*. The *Rhodotorula* species, although they were common saprophytes until now, recently have been reported to cause opportunistic infections [1]. Rare cases of fungaemia which are associated with catheters, endocarditis, peritonitis, meningitis and endophthalmitis have been reported in the literature, as being caused by this yeast [2]. We are presenting here a case of human immunodeficiency virus (HIV-2) infection in a patient who presented to the emergency with a history of fever of one week's duration, with an altered sensorium. The diagnosis of meningitis is confirmed by cell cytology, India ink preparation, gram staining and the culture of cerebrospinal fluid, which grew *Rhodotorula* species. The patient was successfully treated with Amphotericin B. Meningitis, which is caused by the *Rhodotorula* species, is very rare, with only 2-3 cases being reported in the literature, that too, in the patients who were suffering from HIV-1 [1-5].

CASE REPORT

A 45-year old female was admitted with high grade fever of one week's duration. The fever was associated with rigors and chills. The patient also complained of neck pain, headache and vomiting since one day. On examination, the patient was found to be febrile (102F) with an altered sensorium. The neck rigidity and Kernig's sign were positive. Investigations revealed the haemoglobin level to be 11 gm%, TLC to be 14300/cmm, blood glucose to be 86mg/dl, urea to be 21mg/dl and creatine to be 1.1mg/dl.

The X-ray of the chest was normal and the blood culture was sterile after 48 hour of incubation at 37°C. Lumbar puncture was performed after doing the fundoscopy. CSF was collected under

aseptic conditions in a sterile container and it was sent for cytological, biochemical and microbiological examinations. The cell cytology showed a WBC count of 60 cells / cmm, with a mixture of neutrophils and lymphocytes. The CSF protein level was 82mg/dl and the sugar level was 45mg/dl.

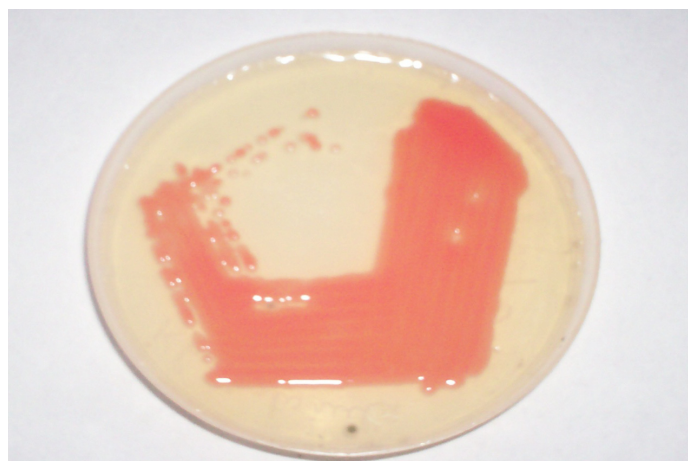
In the Microbiology laboratory, bacteriological and fungal cultures were put up. Various staining methods like ZN staining, gram staining and India ink staining were performed. ZN staining revealed no acid fast bacilli. Gram staining showed inflammatory cells along with budding yeast cells of size, 4-8 micron metres. India ink preparation showed encapsulated budding yeast cells with a clear halo around them. The latex agglutination test for the cryptococcal antigen was negative. The patient was found to be reactive to HIV-2 antibodies with Coombs AIDS RS (Span Diagnostics), Bidot (J Mitra) and Retroquick (Qualpro diagnostics). On the 2nd day the bacteriological culture was found to be sterile. On the 3rd day, the fungal culture yielded a mucoid red growth on SDA at 37°C and at 20°C. The gram staining of the the growth revealed budding yeast cells. LCB was made from the growth, which showed budding yeast cells. One more tube of SDA in which another sample of the same patient was inoculated on the 3rd day before starting the anti-fungal treatment, again revealed the same findings. Further, the nitrate assimilation test and inositol assimilation were carried out, which were negative with the test strain. The CD4 count was 396cells/dl. CT was not carried out as the as the patient was very poor. These findings, along with the biochemical tests, helped us to diagnose the pathogen as *Rhodotorula rubra*. Repeated isolation from a different sample from the same patient helped us to rule out contamination.

The patient was started on Amphotericin B (1mg/kg/day), she showed improvement in her condition within 3-4 days and she recovered fully within 7-10 days. After 10 days of Amphotericin therapy, the patient was put on a maintenance dose of Itraconazole 400 mg, once a day for three months. ART was not given as her CD4 count was adequate according to the NACO guidelines. After the therapy, the patient recovered fully within two weeks and so, no


repeat sample was taken. She was followed up to six months and showed no recurrence.

DISCUSSION


The advent of the AIDS syndrome and the widespread use of broad spectrum antibiotics and immunosuppressive drugs have led to the increased incidence of fungal infections in humans. The genus, *Rhodotorula* includes 38 species which are mostly found in environmental sources like shower curtains, bath tubs and tooth brushes. Members of the *Rhodotorula* genus, which were generally considered to be non pathogens, are nowadays being recovered from humans from the skin, lungs, conjunctiva, urine and CSF [2].



[Table/Fig-1]: Red mucoid colonies of *Rhodotorula rubra* on SDA after 48 hours of incubation obtained from CSF of a patient with meningitis



[Table/Fig-2]: Showing seropositivity to HIV-2



[Table/Fig-3]: Lactophenol cotton blue (LCB) smear of *Rhodotorula rubra* isolated from CSF of a patient with meningitis. (40x)

However the *Rhodotorula* species have been implicated as a cause of meningitis, endocarditis, ventriculitis, peritonitis, central venous catheter infection and keratitis. The genus, *Rhodotorula* is an encapsulated pigmented yeast. Microscopically, the unicellular cells are spherical in shape, their size varies from 4-6 μm and they are surrounded by capsules. Ascospores are absent in this fungus. *Rhodotorula rubra* is the most common species which is isolated from clinical samples, followed by *Rhodotorula glutinis*. The red colonies which are formed are due to the presence of the carotenoid pigment, torularhodin. The *Rhodotorula* species can be easily confused with the *Cryptococcus* species, but the carotenoid pigment and the biochemical tests help in differentiating them. The *Rhodotorula* species have low virulence and low mortality. Fatal cases have been documented on autopsy. They are common saprophytes of the skin, urine and faeces, but they are rarely isolated from blood and CSF [6].

HIV-2 is mostly confined to western Africa and a prevalence of 10% has been reported from some settings in Africa [7]. The incidence of HIV-2 is very low in the Indian sub-continent. The first case of HIV-2 in India was reported in 1991 by Rubsamen- Waigmann [8,9]. It is less pathogenic than HIV-1 and rates of disease development in the HIV-2 infection are much lower than those of HIV-1. There is a long term disease non-progression in HIV-2 [10]. In an autopsy study which was conducted in Cote d'Ivoire, which comprised 154 people who were infected with HIV-1 and 40 people who were infected with HIV-2, severe CMV encephalitis was observed, which was more common in people who were infected with HIV-2 [11]. Similarly, in our case also, opportunistic fungal infections were seen with a higher CD-4 count than was the case normally with the HIV-1 infection. As the CD-4 count was more than 350 cells/dl, ART was not started as per the NACO guidelines. Moreover, more clinical data is needed to determine the more effective treatment and the optimal timing of ART in HIV-2 infection, as studies on HIV-2 are comparatively less in number.

Relapse with *Rhodotorula* meningitis was reported by Gyaurgieva et al, which was treated with itraconazole therapy [4]. The infection with this rare yeast could be underreported due to its similarity with *Cryptococcus neoformans*. In our case, the possibility of contamination was ruled out as CSF is a sterile fluid and growth was obtained twice on SDA medium which contained antibiotics, from different samples from the same patient. Thus, the *Rhodotorula* species was considered to have a pathogenic role in causing meningitis in the present case.

REFERENCES

- [1] Thakur K, Singh G, Agrawal S, Rani L. Meningitis which was caused by *Rhodotorula rubra* in an human immunodeficiency virus infected patient. *Indian J Med Microbiol* 2007; 25: 166-68.
- [2] Felipe FT, Silva FC. *Rhodotorula* infection; A systemic review of 128 cases from the literature. *Rev Iberoam Micol* 2008;25 :135-40.
- [3] Shinde RS, Mantus BC, Patil G, Parande MV, Parande AM. Meningitis due to *Rhodotorula glutinis* in an HIV infected patient. *Indian J Med Microbiol* 2008;26(4): 375-97.
- [4] Gyaurgieva OH, Bogomolova TS, Peacock C, Beaumel A, Djomand G, Ngbichi JM et al. The mortality and the pathology of an HIV- infected patient. *J Med Vet Mycol* 1996; 34:357-59.
- [5] Lanzafame M, De Checchi G, Parinello A, Trevenzoli M, Cattelan AM. *Rhodotorula glutinis* related meningitis. *J Clin Microbiol* 2001; 39: 410.
- [6] Lo Re V III, Fishman NO, Nachamkin I. Recurrent catheter related *Rhodotorula rubra* infection. *Clin Microbiol Infect* 2003 (9) : 897-900.
- [7] Schim van der loeff MF, Aaby P. Towards a better understanding of the epidemiology of HIV-2. *AIDS* 1993;13 Suppl A : S 69-84.
- [8] Murugan S, Anburajan R. Prevalence of the HIV-2 infection in southern Tamil Nadu. *Indian J Sex Transm Dis* 2007; 28: 113.

- [9] Rubsamen- Waigmann H, Briesen HV, Maniar JK, Rao PK, Scholz C, Pftzner A. The spread of HIV-2 in India. *Lancet* 1991; 337:550-1.
- [10] Marlink R, Kanki P, Thior I, Travers K, Eisen G, Siby T et al. The reduced rate of disease development after the HIV-2 infection as compared to HIV-1. *Science* 1994;265:1587-90.
- [11] Lucas SB, Honnou A, Peacock C, Beaumel A, Djomand G, Ngbichi JM et al. The mortality and the pathology of the HIV infection in a west African city. *AIDS* 1993; 7: 1569-79.

AUTHOR(S):

1. Dr. Ashish Khanna
2. Dr. Menka Khanna
3. Dr. Aruna Aggarwal

PARTICULARS OF CONTRIBUTORS:

1. MD, Assistant Professor, Department of Microbiology , SGRDIMSR, Amritsar (Punjab),India.
2. MD, Associate Professor, Department of Pathology , SGRDIMSR, Amritsar (Punjab),India.
3. MD, Professor and Head of Department (Dean Academics), (I/C ICTC–Integerated Testing and Councilling Centre Set Up by NACO) Department of Microbiology, SGRDIMSR (Punjab),India.

NAME, ADDRESS, TELEPHONE, E-MAIL ID OF THE CORRESPONDING AUTHOR:

Dr. Ashish khanna
538, Basant Avenue
Amritsar-143001, Punjab (India).
Phone: 9465128936; 091-0183-2562919
E-mail: ashish_538@yahoo.co.in

FINANCIAL OR OTHER COMPETING INTERESTS:

None.

Date of Submission: **Jul 10, 2011**
Date of Peer Review: **Nov 26, 2011**
Date of Acceptance: **Dec 20, 2011**
Date of Publishing: **Feb 15, 2012**