


Agnesis of the Corpus Callosum, Cardiac, Ocular, and Genital Syndrome with Interhemispheric Cyst in an Infant: A Case Report

AASHITA MALIK¹, LAVANYA RAMAKRISHNAN IYER², REVAT MESHAM³, AMAR TAKSANDE⁴, SHANTANU GOMASE⁵



ABSTRACT

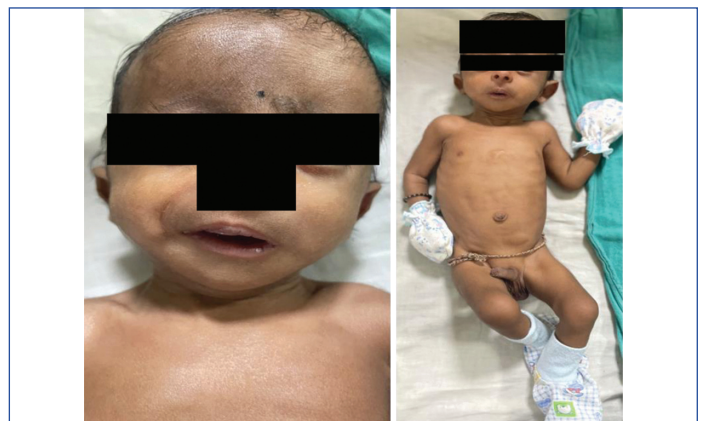In rural India, it is fairly common for infants to be brought in with symptoms such as failure to gain weight and a history of recurrent respiratory tract infections. Congenital Heart Disease (CHD) is often associated with various syndromes, including Down syndrome, Turner syndrome, Holt-oram, and others. It is widely understood and practiced to investigate for other systemic and congenital anomalies when a child is suspected or diagnosed with CHD or any other congenital condition. On the other hand, one of the most prevalent malformations of the cerebral cortex involves the corpus callosum. The corpus callosum consists of white matter tracts that connect the left and right cerebral hemispheres. Agnesis of the Corpus Callosum (ACC), which can be partial or complete, may occur alone or in combination with other cerebral abnormalities. It can manifest as hypoplasia or complete absence of the corpus callosum. In the present case report, the authors present a three-month-old infant who presented with complaints of failure to gain weight and a history of convulsions despite being on anticonvulsant medication. Further evaluation revealed complete agnesis of the corpus callosum on Magnetic Resonance Imaging (MRI). Additional examination findings included microcephaly, left-sided microphthalmia, low-set ears, retrognathia, suggesting a dysmorphic facies, and a left-sided inguinal hernia. The patient was also diagnosed with Patent Ductus Arteriosus (PDA) based on a 2D echo. The presence of multiple systemic anomalies in the present case makes it a rare occurrence, with only a few similar cases reported.

Keywords: Arachnoid cyst, Congenital anomaly, Congenital heart disease, Convulsions, Multiple systemic anomalies

CASE REPORT

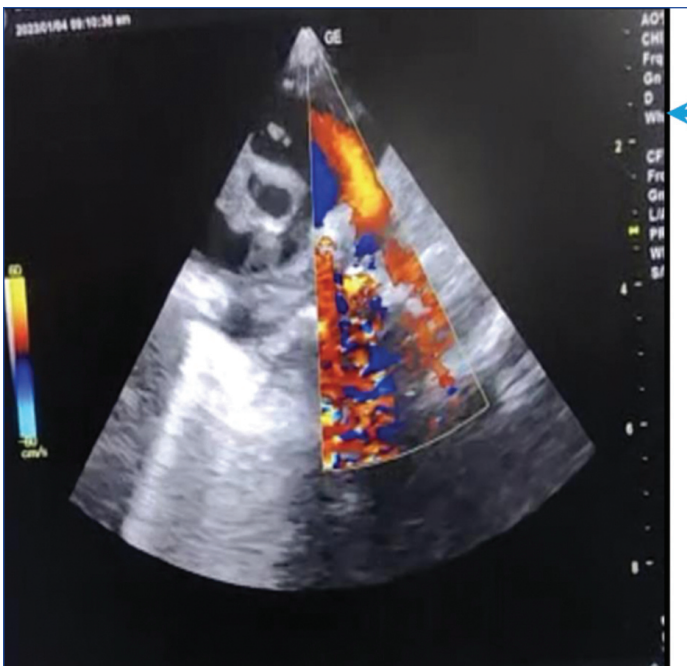
A three-month-old male child was brought to the Paediatrics Department with a complaint of inability to gain weight and multiple episodes of abnormal movements since birth. He was a 2.2 kg weighing male infant, born out of a non consanguineous marriage to a 24-year-old multiparous mother, with no significant medical or antenatal history and normal antenatal scans, at term gestation via caesarean section. There was no history of similar complaints in the elder siblings. A history of delayed crying requiring Neonatal Intensive Care Unit (NICU) admission due to perinatal asphyxia was present. During his 4-day NICU stay, the patient also experienced three episodes of neonatal seizures. An Electroencephalogram (EEG) was performed and ruled out abnormal ictogenic discharges. The patient was discharged on an oral anti-epileptic drug but continued to have multiple spasm-like convulsions that lasted for a split second, showing poor control. The patient failed to gain weight over the next couple of months, weighing 2.2 kg at three months of age.

During anthropometric examination, the patient had a length of 54 cm and a head circumference of 34 cm, suggesting failure to thrive. At the time of admission, the patient had not achieved any developmental milestones appropriate for his age. Upon general physical examination, the patient was vitally stable. The patient exhibited visible microcephaly, left-sided microphthalmia, low-set ears, and retrognathia, suggesting a dysmorphic facies, along with a left-sided inguinal hernia when crying. No other significant external genital malformation was noted [Table/Fig-1]. The Central Nervous System (CNS) examination revealed a depressed anterior fontanelle and right-sided facial deviation when crying. The CNS examination was otherwise normal. A cardiovascular system examination revealed a pansystolic murmur with a loud P2, best heard in the tricuspid area, along with signs of congestive heart failure.

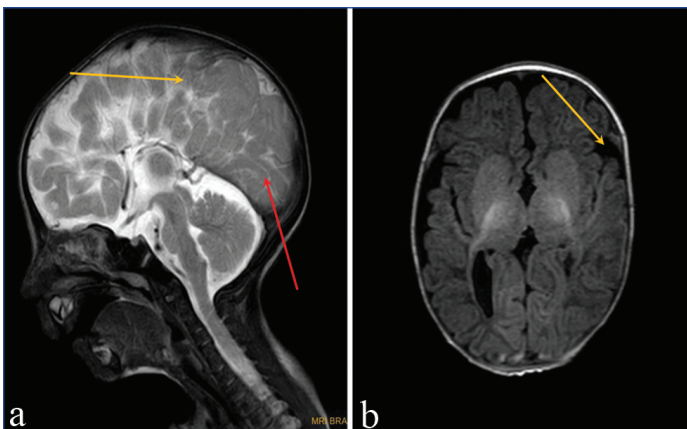


[Table/Fig-1]: Child showing visible dysmorphic facies with left-sided microphthalmia, right-sided facial deviation, and retrognathia.

An abdominal examination revealed a left-sided inguinal hernia, with the spleen and liver palpable just below the costal margin and 3 cm below it, respectively. The respiratory system examination revealed no significant findings. The patient underwent routine evaluation, which did not reveal any significant findings. However, further evaluation, including a 2D echo, showed a large 4 mm Patent Ductus Arteriosus (PDA) [Table/Fig-2] with a left-to-right shunt, mildly dilated left atrium and ventricle, and severe Pulmonary Artery Hypertension (PAH) of 75 mmHg with normal biventricular function. Abdominal and pelvic ultrasonography revealed multiple gallbladder calculi collectively measuring 1 cm, mild splenomegaly, and evidence of cystitis. Magnetic Resonance Imaging (MRI) of the brain [Table/Fig-3] detected colpocephaly, complete corpus callosum agnesis, and a 3x4 cm arachnoid cyst in the right retrocerebellar region. A comprehensive ophthalmic evaluation revealed microphthalmia of the left eye with a normal fundus. Based on the MRI findings



[Table/Fig-2]: A Parasternal Short Axis (PSAX) view on 2D echo showing a large PDA (blue arrow) with a left to right shunt.



[Table/Fig-3]: a) T2WI MRI, coronal section imaging reveals a hyperintense mass lesion in the right retrocerebellar region (red arrow) with absence of corpus callosum (yellow arrow). b) T2 axial section reveals non-visualization of corpus callosum with disproportionate prominence of occipital horn of lateral ventricle on right-side (yellow arrow).

and after ruling out other differentials like Chiari malformation and Dandy-Walker malformation, the diagnosis of agenesis of the corpus callosum, cardiac, ocular, and genital syndrome was made. However, a thorough genetic analysis to confirm CDH2 gene mutation was not conducted due to financial constraints.

The patient was managed symptomatically. Levetiracetam was initiated at 30 mg/kg/day for seizure control, and Lasix was started at 2 mg/kg/day as an antifailure drug in view of the haemodynamically significant PDA. Milk fortification and supplementation were done to promote adequate weight gain. The patient is scheduled for PDA ligation surgery after achieving sufficient weight gain. Subsequently, neurosurgical intervention in the form of craniotomy or shunt surgery will be planned once haemodynamic stability is achieved. Due to the limited number of reported cases and lack of extensive research, the outcome cannot be predicted accurately.

DISCUSSION

Major congenital abnormalities affect 2%-5% of newborns, and these conditions are frequently accompanied by Neurodevelopmental Disorders (NDDs) of varying severity [1]. Several syndromes that include ACC as an associated feature are Arnold-Chiari malformation, Dandy-Walker syndrome, holoprosencephaly, schizencephaly, foetal alcohol syndrome, Apert syndrome, basal cell nevus syndrome, Joubert syndrome, Lyon syndrome, Aicardi syndrome, certain

chromosomal rearrangements, several trisomies, and gene mutations [2].

A rare syndromic disorder, Agenesis of Corpus callosum, Cardiac, Ocular, and Genital Syndrome (ACOGS), is characterised by global developmental delay, intellectual disability, ACC, craniofacial dysmorphisms, and ocular, cardiac, and genital anomalies. ACOGS is a result of mutations in the CDH2 gene, which codes for cadherin and is a member of the cadherin superfamily. The gene is located on chromosome 18q12.1 [2].

Accogli et al., reported a case involving nine individuals with mutations in the CDH2 gene who presented with similar clinical and radiological features, including developmental delay/intellectual disability, malformation of the corpus callosum, cardiac and ocular abnormalities, and characteristic facial dysmorphisms [3]. Among these nine individuals, seven patients had corpus callosum agenesis, one had callosal hypoplasia, and neuroimaging was not performed on the remaining candidate. Neuroimaging in two of these patients also showed an interhemispheric cyst communicating with the third ventricle. The study population also exhibited a wide range of Congenital Heart Disease (CHD), including atrioventricular canal defects, coarctation of the aorta, right pulmonary artery hypoplasia with dextrocardia, and tricuspid regurgitation. Seizures, in the form of focal or infantile spasms, were also reported in the patient population. In addition, 50% of the study population had congenital eye defects such as Peters anomaly (congenital corneal opacity with associated corneo-lenticular attachments), unilateral ptosis with Duane anomaly (congenital, progressive horizontal strabismus), congenital cataracts, and strabismus. Four out of five male patients had genital anomalies, including micropenis and cryptorchidism.

In another study by Kanjee M et al., a patient with a nonsense mutation in the CDH2 gene leading to ACOGS had a renal malformation, whereas the syndrome is classically associated with genital malformations [4]. Similarly, in this particular case, the patient had no evident genital malformation apart from a right-sided reducible inguinal hernia, depicting the variation seen in the genital abnormalities associated with this syndrome. Most patients with ACC and interhemispheric cysts have a moderate clinical phenotype after ruling out Aicardi syndrome, which is characterised by borderline/normal cognition and minor neurological symptoms. Epilepsy in these individuals is uncommon and typically responds to antiepileptic medications, despite the high prevalence of EEG epileptic abnormalities [5].

The Barkovich classification of 2001 was developed as a design system to classify cases of callosal agenesis, interhemispheric cysts, and cortical development malformations based on postnatal imaging techniques and excluding pathologic or histologic diagnosis. It divides cases into types 1 and 2. Type 1 cysts communicate with the ventricles. Type 1a Immunohistochemistry (IHC) has no other documented cerebral malformations, while type 1b presents with hydrocephalus secondary to hindrance in the outflow of cerebrospinal fluid from the third ventricle into the aqueduct of Sylvius. Type 1c IHC is characterised by cerebral hemisphere hypoplasia and a small head. These cysts are seen as diverticula of the lateral or third ventricles. Type 2 cysts differ from type 1 cysts as they have no communication with the ventricles.

Type 2 is further classified into three subtypes. Type 2a occurs when there are no other abnormalities but ACC. Type 2b and 2c are associated with Aicardi syndrome and subcortical heterotopia, respectively. The patient in the present study, a male child, had a neonatal presentation with seizures and microcephaly, and neuroimaging revealed an arachnoid cyst that is unilocular and isointense with CSF with communication with the ventricles, falling into type 1c [6].

Hettis SW et al., discovered that the frequency of interhemispheric cysts was comparable in malformations of the corpus callosum in their study of 142 patients with ACC and Hypoplasia of Corpus Callosum (HCC). Interhemispheric cysts were seen in 20 patients out of the entire study population, with 11 cysts showing communication with the ventricles (Type I of the Barkovich classification) and nine cysts showing no communication with the ventricular system (Type II) [7].

The occurrence of Type I cysts is higher in male patients. A more thorough examination of the male-to-female ratio leads to the conclusion that some specific anomalies are more frequently seen in males than in females. Aicardi syndrome, for example, was ruled out in the present case because it is only seen in females and is always associated with chorioretinal lacunae. This emphasises once again that ACC with an interhemispheric cyst is a group of heterogeneous disorders rather than a single malformation [8].

The IHC associated with ACC has various clinical manifestations, ranging from being asymptomatic or showing spontaneous regression to significant neurological disabilities such as hydrocephalus leading to macrocrania, seizures, hemiparesis, elevated Intracranial Pressure (ICP), and psychomotor delays. No established surgical protocol or treatment has been established for the treatment of symptomatic or large, asymptomatic IHC. The procedures employed have included craniotomy, shunt placement, and neuroendoscopic surgery [9].

Revanna K et al., described two cases of corpus callosum agenesis with IHC, demonstrating its clinical implications and outcome. Both cases required a multidisciplinary approach and routine follow-up, and showed delays in developmental milestones, with the second case succumbing to aspiration pneumonitis at 22 months of age [10].

In the present case, IHC is complicated by the presence of ACOGS syndrome. This requires careful planning of medical and surgical management across different systems to improve the patient's quality of life and reduce associated morbidity and neurological deficits. The patient is currently scheduled for PDA ligation to promote adequate growth and weight gain, and routine follow-up is warranted.

The limited number of reported cases of ACOGS syndrome highlights the need for awareness of this association and further research into related risk factors and complications associated with this syndrome.

CONCLUSION(S)

Patients diagnosed with this syndrome, as in the current scenario, can only be managed symptomatically. ACOGS is a rare condition, and its association with an interhemispheric cyst is not commonly seen, with just a handful of cases reported worldwide to date. The concurrence of an interhemispheric cyst in a suspected case of ACOGS has been reported for the first time, according to a thorough review of the literature. This highlights the variability of presentation in syndromes with multisystem involvement and their associations with each other. Patients presenting in a similar manner require a complete evaluation of associated anomalies with timely neuroimaging for an appropriate diagnosis and prognosis of the condition.

REFERENCES

- [1] Dulovic-Mahlow M, Trinh J, Kandaswamy KK, Braathen GJ, Di Donato N, Rahikkala E, et al. De Novo variants in TAOX1 cause neurodevelopmental disorders. *Am J Hum Genet* [Internet]. 2019 [cited 2023 Apr 9];105(1):213-20. Available from: <https://pubmed.ncbi.nlm.nih.gov/31230721/>.
- [2] Das JM, Geetha R. Corpus Callosum Agenesis. [Internet]. [cited 2023 Apr]. Available from: <https://www.ncbi.nlm.nih.gov/books/NBK540986/>.
- [3] Accogli A, Calabretta S, St-Onge J, Boudrahem-Addour N, Dionne-Laporte A, Joset P, et al. De novo pathogenic variants in n-cadherin cause a syndromic neurodevelopmental disorder with corpus callosum, axon, cardiac, ocular, and genital defects. *Am J Hum Genet*. 2019;105(4):854-68. Doi: 10.1016/j.ajhg.2019.09.005.
- [4] Kanjee M, Yuze Kahraman C, Erooskun P, Tatar A, Kahraman M. A Novel nonsense variant in the CDH2 gene associated with ACOGS: A case report. *Am J Med Genet A* [Internet]. 2022;188(9):2815-18. Available from: <http://dx.doi.org/10.1002/ajmg.a.62861>.
- [5] Uccella S, Accogli A, Tortora D, Mancardi MM, Nobili L, Berloco B, et al. Dissecting the neurological phenotype in children with callosal agenesis, interhemispheric cysts and malformations of cortical development. *J Neurol* [Internet]. 2019;266(5):1167-81. Available from: <http://dx.doi.org/10.1007/s00415-019-09247-7>.
- [6] Barkovich AJ, Simon EM, Walsh CA. Callosal agenesis with cyst: A better understanding and new classification. *Neurology* [Internet]. 2001;56(2):220-27. Available from: <http://dx.doi.org/10.1212/wnl.56.2.220>.
- [7] Hettis SW, Sherr EH, Chao S, Gobuty S, Barkovich AJ. Anomalies of the corpus callosum: An MR analysis of the phenotypic spectrum of associated malformations. *AJR Am J Roentgenol* [Internet]. 2006;187(5):1343-48. Available from: <http://dx.doi.org/10.2214/AJR.05.0146>.
- [8] Das A, Das A, Chakrabarty D. Corpus callosum hypogenesis with interhemispheric cyst: A case report. *Int J Res Med Sci* [Internet]. 2015 [cited 2023 Apr 9];3(4):1032. Available from: <https://www.msjonline.org/index.php/ijrms/article/view/1437>.
- [9] Caldarelli M, Di Rocco C. Surgical options in the treatment of interhemispheric arachnoid cysts. *Surg Neurol* [Internet]. 1996 [cited 2023 Apr 9];46(3):212-21. Available from: <https://pubmed.ncbi.nlm.nih.gov/8781589/>.
- [10] Revanna KG, Rajadurai VS, Chandran S. Agenesis of the corpus callosum with interhemispheric cyst: Clinical implications and outcome. *BMJ Case Rep* [Internet]. 2018;11(1):bcr-2018-227366. Available from: <http://dx.doi.org/10.1136/bcr-2018-227366>.

PARTICULARS OF CONTRIBUTORS:

1. Resident, Department of Paediatrics, Datta Meghe Institute of Higher Education and Research, Wardha, Maharashtra, India.
2. Resident, Department of Paediatrics, Datta Meghe Institute of Higher Education and Research, Wardha, Maharashtra, India.
3. Associate Professor, Department of Paediatrics, Datta Meghe Institute of Higher Education and Research, Wardha, Maharashtra, India.
4. Professor and Head, Department of Paediatrics, Datta Meghe Institute of Higher Education and Research, Wardha, Maharashtra, India.
5. Assistant Professor, Department of Paediatrics, Datta Meghe Institute of Higher Education and Research, Wardha, Maharashtra, India.

NAME, ADDRESS, E-MAIL ID OF THE CORRESPONDING AUTHOR:

Aashita Malik,
G-6, Radhikabai Hostel, JNMC, Sawangi Meghe, Wardha-442005, Maharashtra, India.
E-mail: aashitamalik04@gmail.com.

AUTHOR DECLARATION:

- Financial or Other Competing Interests: None
- Was informed consent obtained from the subjects involved in the study? Yes
- For any images presented appropriate consent has been obtained from the subjects. Yes

PLAGIARISM CHECKING METHODS: [Jain H et al.]

- Plagiarism X-checker: Apr 12, 2023
- Manual Googling: Aug 17, 2023
- iThenticate Software: Sep 18, 2023 (14%)

ETYMOLOGY: Author Origin

EMENDATIONS: 6

Date of Submission: **Apr 09, 2023**
Date of Peer Review: **Jul 18, 2023**
Date of Acceptance: **Sep 20, 2023**
Date of Publishing: **Nov 01, 2023**