

Rhino-Orbital-Cerebral Zygomycosis in a Young Boy: Case Report

RAGINI TILAK, VIKAS KUMAR, VIJAI TILAK, VIVEK SHARMA

ABSTRACT

Rhino-orbital-cerebral zygomycosis is a rare opportunistic infection of sinuses, orbit and brain which is caused by saprophytic fungi which belongs to the order of Mucorales. It is one of the fulminant and fatal mycotic infections known to human beings with a high mortality rate. An increased incidence of zygomycosis has been observed in immuno-compromised patients such as poorly controlled diabetes mellitus, blood dyscrasias, malnutrition, neutropenia, iron overload, organ

transplant and immuno-suppressive therapy but they can also occur in normal hosts rarely. We report here a case of 21-year old diabetic young boy presented with a history of non-specific headache, pain abdomen, vomiting and progressive swelling of left eye and altered sensorium. On the basis of MRI findings and microbiological investigations, he was diagnosed as a case of rhino-orbital-cerebral zygomycosis. He was treated successfully with a combination of surgical debridement and systemic amphotericin B administration.

Key Words: Rhino-orbital-cerebral zygomycosis, Zygomycetes, Amphotericin- B and Diabetes mellitus (DM)

INTRODUCTION

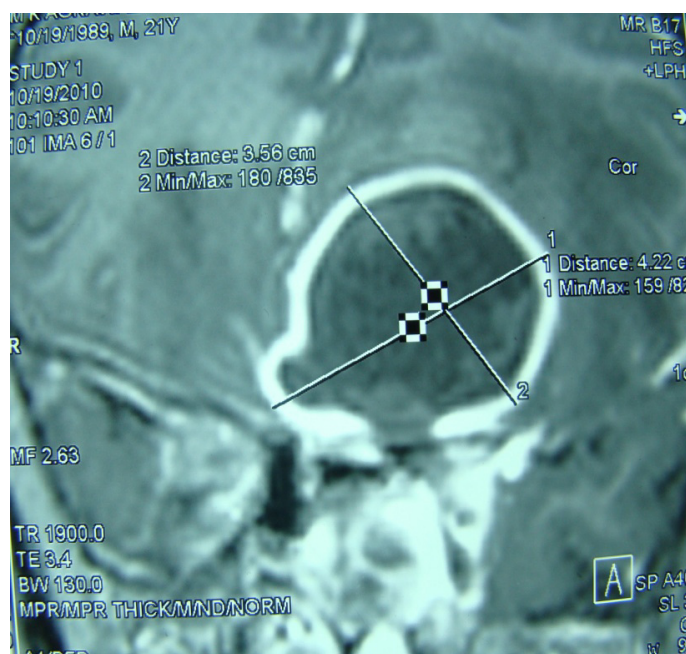
Zygomycosis (Mucormycosis) is a rare, opportunistic fungal infection of the order mucorales in the class of zygomycetes. It is capable of becoming fatal in immuno-compromised patients. Infections due to zygomycetes are usually divided into six clinical syndromes: rhinocerebral, pulmonary, disseminated, gastrointestinal, cutaneous and miscellaneous [1]. Patients with diabetes mellitus usually have the rhinocerebral and pulmonary form of disease [2]. Rhinocerebral zygomycosis is the most common syndrome which is classically described as an acute, rapidly progressive infection and is characterized by vascular invasion and extensive tissue necrosis [3]. Early diagnosis and treatment of zygomycosis is extremely important due to the aggressive course of the disease. Control of underlying disease must be established, metabolic abnormalities corrected and anti-fungal therapy should be combined with surgical debridement of all necrotic tissues [4].

Here, we report a case of rhino-orbital-cerebral zygomycosis in a young male patient who was previously unaware that he was suffering from diabetes mellitus (DM). It is particularly CNS disease and is associated with substantial mortality rate in uncontrolled diabetes mellitus.

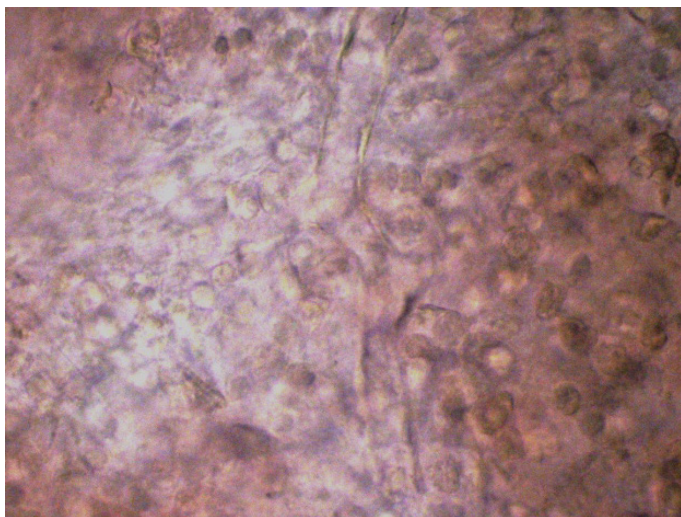
CASE REPORT

A 21-year old young previously healthy boy presented to our hospital with non-specific symptoms such as pain abdomen, vomiting, headache and progressive swelling of left eye. The swelling in the eye gradually progressed and lead to orbital proptosis. He developed altered sensorium. All these symptoms developed during a 30-days period MRI showed ring enhancing space occupying lesion in left frontal lobe measuring 3.6 × 2.6 × 2.0 cm [Table/Fig-1]. His laboratory investigation were done and the findings were: Hb-10.8gm%, total leukocyte count 8900/cubic mm, differential leukocyte count – Neutrophils 67%, Lymphocytes 23%, Monocytes 9%, Eosinophils 1%, Red blood cell count-5.6 million/mm³, ESR-52/cubic mm, Platelet count 3,12000/

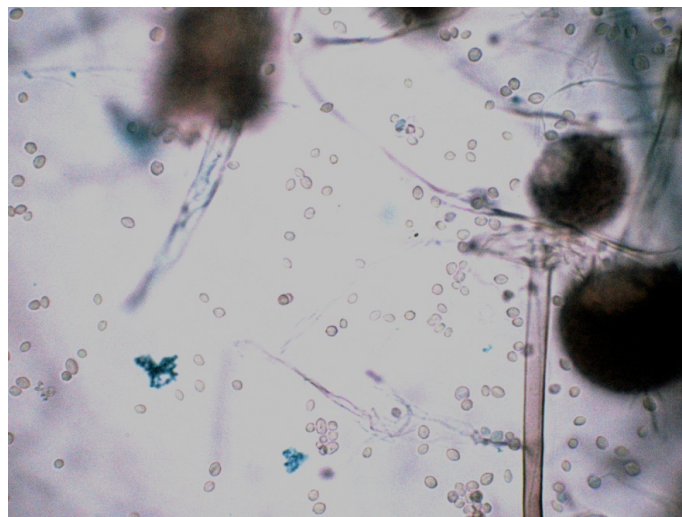
mm³ of blood, post-prandial blood sugar 360 mg/dl and in urine ketone bodies were present. Repeat MRI showed increasing ring enhancing lesion measuring 3.8× 3.1cm. With clinical diagnosis of cerebral abscess along with underlying diabetes ketoacidosis, patient underwent radical debridement by neurosurgeon. Pus was sent for microbiological examination. Routine microbiological work up for bacterial and fungal culture was done. Microscopical examination of KOH preparation showed aseptate hyphae [Table/Fig-2]. Fungal culture showed white fluffy growth which was identified as *Rhizopus arrhizus* [Table/Fig-3]. In this case, parenteral amphotericin B was started immediately after direct microscopy. He responded to the anti-fungal drug and was discharged.



[Table/Fig-1]: MRI picture-Suspected zygomycosis showing ring enhancing space occupying lesion in left frontal lobe.



[Table/Fig-2]: KOH mount showing aseptate hyphae (400 x magnifications)



[Table/Fig-3]: Rhizopus arrhizus in LCB mount ((400 x magnifications)

DISCUSSION

Among the member species of zygomycetes, *Rhizopus arrhizus* (*R.oryzae*) is by far the most common cause of zygomycosis [5-6]. These are widespread in nature subsisting on decaying vegetation and diverse organic material. The most common route of transmission is inhalation of spores from the environment. For this reason, rhinocerebral and pulmonary zygomycosis are the usual types of infections in immuno-compromised patients followed by gastro-intestinal, cutaneous and disseminated infection.

Rhino-orbital-cerebral zygomycosis is a rare but potentially aggressive and fatal fungal infection. It should be considered in all patients with chronic sinusitis, especially in immuno-compromised patients. Other factors predisposing to invasive zygomycosis include poorly controlled diabetes mellitus, prolonged corticosteroids treatment, haematological malignancies, severe burns/ trauma, chronic kidney disease, AIDS, immuno-suppressant use following solid organ transplant and intravenous drug abuse. Clinically they frequently present as fever, sinusitis, headache, peri-orbital pain or facial swelling. Similar clinical presentation was seen in present case.

The diagnosis was confirmed by direct microscopy, fungal culture and histopathology. The patient was treated with conventional

amphotericin-B as soon as fungal culture revealed zygomycosis. Invasive mould infection such as those caused by zygomycosis is extremely difficult to cure. The usual approach to treatment of these infections is correction of the predisposing disorder, aggressive surgical and antifungal therapy.

REFERENCES

- [1] Tilak R, Raina P, Gupta S, Tilak V, Prakash P, Gulati AK. Cutaneous zygomycosis: A possible post-operative complication in immunocompetent individuals. *JDVL* 2009;75 (6):596-99
- [2] Kontoyannis DP, Wessel WC, Bodey GP, Rolston KV. Zygomycosis in the 1990s in a tertiary care centre. *Clin infect dis*. 2000;30:851-56.
- [3] Gonzalez CE, Rinaldi MG, Sugar AM. Zygomycosis. *Infectious Disease Clinics of North America* 2002;16:895-914
- [4] Yohai RA, Bullock JD, Aziz AA, Markert RJ. Survival factors in Rhino-orbital-cerebral mucormycosis. *Surv Ophthalmol*.1994;39:3-22
- [5] Diwakar A, Dewan RK, Chowdhary A, Randhawa HS, Khanna G, Gaur SN. Zygomycosis- a case report and overview of the disease in India. *Mycoses* 2007 Jul; 50(4):247-54
- [6] Chakrabarti A, Chatterjee SS, Das A, Panda N, Shivaprakash MR, Kaur A, et al. Invasive zygomycosis in India. An experience in a tertiary care hospital. *Postgraduate Medical Journal* 2009; 85(1009):573-81.

AUTHOR(S):

1. Dr. Ragini Tilak
2. Dr. Vikas Kumar
3. Dr. Vijai Tilak
4. Prof. Vivek Sharma

PARTICULARS OF CONTRIBUTORS:

1. Associate Professor,
Department of Microbiology
IMS, BHU, Varanasi, India.
Email: raginijain29@rediffmail.com
2. Senior Resident,
Department of Microbiology
IMS, BHU, Varanasi, India.
Email: drg.vikas@gmail.com
3. Associate Professor,
Department of Pathology
IMS, BHU, Varanasi, India.
Email: vijaitilak@rediffmail.com

4. Head, Department of Neurosurgery
IMS, BHU, Varanasi, India.
Email: luckin2010@ssgmail.com

NAME, ADDRESS, TELEPHONE, E-MAIL ID OF THE CORRESPONDING AUTHOR:

Ragini Tilak, Associate Professor,
Department of Microbiology
Institute of Medical Sciences, Banaras Hindu University
Varanasi-221005, India.
E-mail: raginijain29@rediffmail.com
Phone: +91 - 9415812317

FINANCIAL OR OTHER COMPETING INTERESTS:

None.

Date of Submission: **Sep 15, 2011**
Date of Peer Review: **Nov 03, 2011**
Date of Acceptance: **Dec 28, 2011**
Date of Publishing: **Feb 15, 2012**