


Unilateral Carotid Body Tumour: A Case Report

SHAKTI SAGAR¹, PRAVIN RAMCHANDRA GADKARI², SAMARTH SHUKLA³, SUNITA VAGHA⁴, KISHOR HIWALE⁵

ABSTRACT

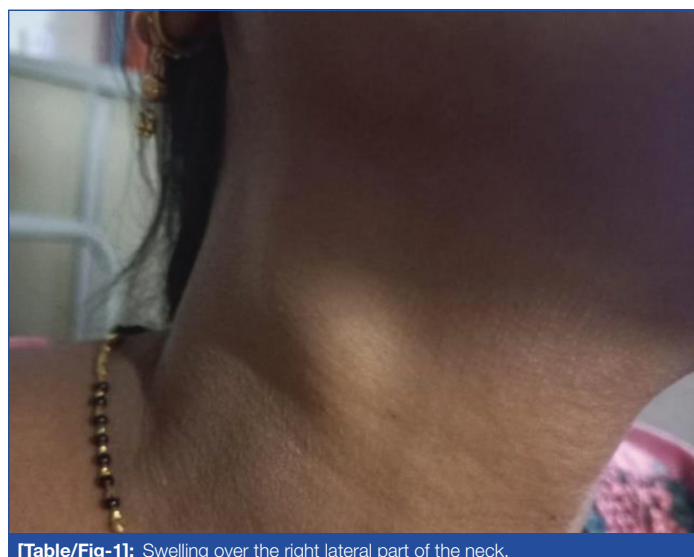
The carotid body, which is located bilaterally on the medial side of the carotid bifurcation, is the largest group of paraganglia in the head and neck. Chemoreceptor cells in the carotid bulb give rise to uncommon tumours known as Carotid Body Tumours (CBTs). The authors describe a case of a CBT in a 40-year-old woman who had a painful, pulsatile, lateral neck enlargement on the right side that had been developing over time. Due to the numerous difficulties and problems brought on by their high vascularity and close proximity to cranial nerves in the neck near the carotid bifurcation, they pose a surgical challenge. Based on the patient's medical history, the results of clinical and radiological examinations, and the successful surgical removal of the tumour, the diagnosis was suspected. The results of histological analysis supported the diagnosis of a CBT.

Keywords: Carotid space, Chemodectoma, Paraganglioma, Surgical excision

CASE REPORT

A 40-year-old female patient with otolaryngology symptoms arrived at the clinic with a right-sided neck swelling that has persisted for 20 years and pain over the swelling for 2-3 months. The swelling over the right side of the neck started gradually, has been progressing, and has reached its current size. The patient also complains of right-sided pain over the swelling that started gradually, is not getting worse, occurs intermittently, is of mild to moderate intensity, and radiates to the right-side of the neck and shoulder. Additionally, the patient experiences brief episodes of dizziness once every 1-2 days, lasting 2-3 seconds.

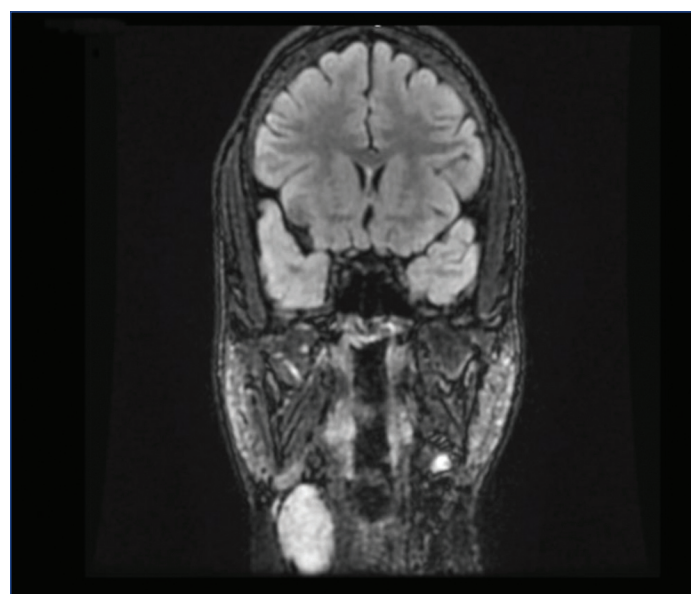
On physical examination, there is a single ovoid swelling measuring 4x2 cm over the right lateral part of the neck, just below the right side of the angle of the mandible. It extends from the posterior border of the right sternocleidomastoid muscle, 1 cm lateral to the right lateral border of the trachea. Superiorly, it extends from the level of the hyoid to 3 cm above the level of the thyroid prominence inferiorly. The margins are regular with well-defined borders, and the skin over the swelling appears normal. The swelling does not move during swallowing or protrusion of the tongue. Pulsation can be felt over the swelling. This patient has visible and prominent carotid pulsation in the neck, which is caused by the abrupt distention and quick collapse of the carotid arteries, known as "Dancing Carotids" [Table/Fig-1].



[Table/Fig-1]: Swelling over the right lateral part of the neck.

No aberrant catecholamine levels were found during the hormonal evaluation. To prevent the onset of a catecholamine crisis, it is important to perform a hormonal check-up to determine if the tumour is secreting catecholamines before considering surgery. It is crucial to establish the diagnosis of paraganglioma and determine if the lesion is secreting catecholamines before proceeding with surgery.

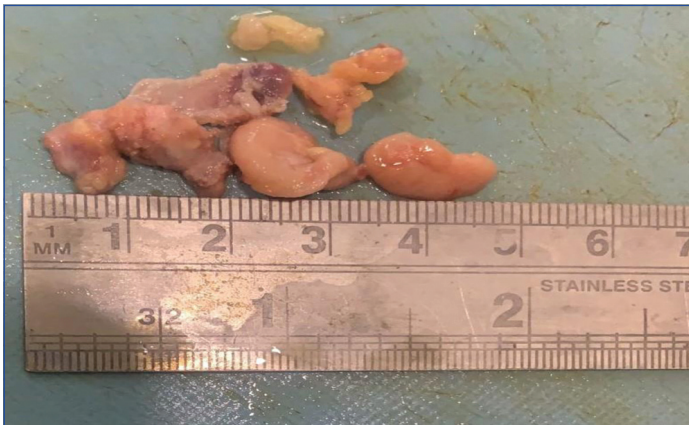Magnetic Resonance Imaging (MRI) of the neck (plain and contrast) revealed an altered signal intensity lesion at the carotid bifurcation on the right side, measuring 3.6x2.6x2.5 cm. This lesion caused splaying of the external and internal carotid arteries. On T1-weighted images, the lesion appeared isointense compared to muscles, while on T2-weighted images, it appeared hyperintense compared to muscles with flow voids, giving it a salt and pepper appearance. Postcontrast imaging showed intense enhancement [Table/Fig-2].



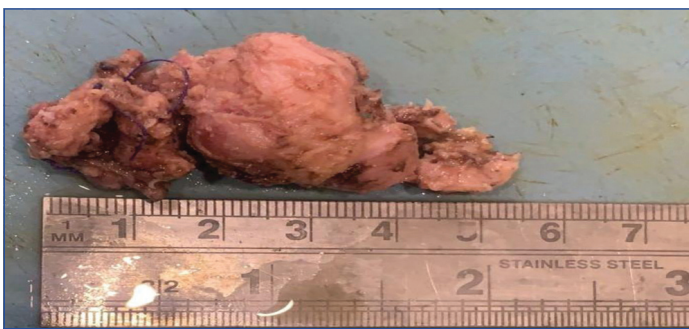[Table/Fig-2]: Magnetic Resonance Imaging (MRI) of neck: Hyperintense compared to muscles with flow voids giving salt and pepper appearance.

Furthermore, mild luminal narrowing of the osteoproximal Internal and External Carotid Arteries (ICA and ECA) was observed, along with a well-defined space-occupying lesion in the right carotid space, leading to splaying of the carotid bifurcation. MRI angiography of the neck supported the diagnosis of a CBT.

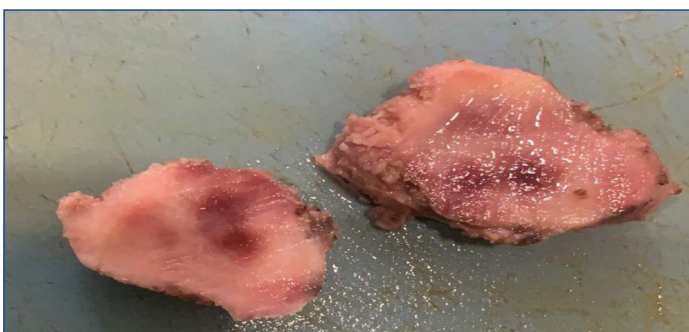After completing all necessary investigations and preanaesthetic check-ups, the patient underwent surgery. Bipolar coagulation was used to remove the heavily vascularised tumour. Complete removal was achieved, and a sample was sent for histopathological examination. The mass removed from the right neck was rubbery-dense and flexible, with whitish-red to brown tumour tissue [Table/Fig-3-5].



[Table/Fig-3]: The gross image of Carotid Body Tumour (CBT): The mass that was removed from the right neck in its entirety had a rubbery feel.



[Table/Fig-4]: The gross image of Carotid Body Tumour (CBT): Smooth, dense and the tumour tissue is greyish white to brown.

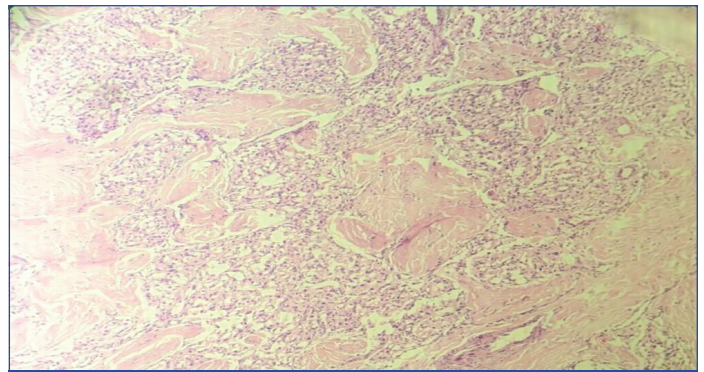


[Table/Fig-5]: Cut section of Carotid Body Tumour (CBT).

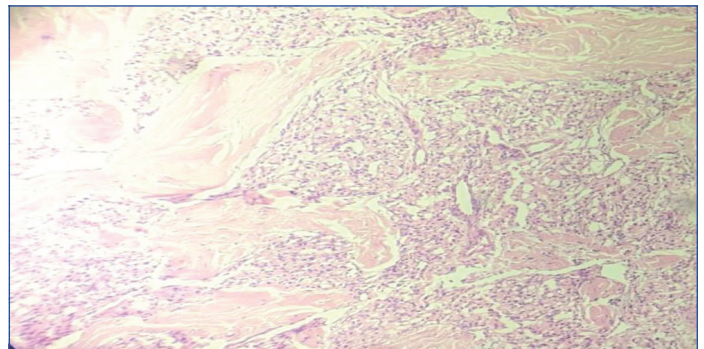
Histopathological examination revealed nests of round to oval main cells of neuroectodermal origin, surrounded by fine vascular septae forming the tumour's Zellballen pattern. The tumour cells had homogeneous, round to ovoid, vesicular nuclei, and abundant transparent or granular, eosinophilic cytoplasm. Cellular pleomorphism was minimal, and mitoses were scarce [Table/Fig-6a,b,7a,b]. These histopathological features suggested a CBT.

To confirm the diagnosis, Immunohistochemistry (IHC) staining {Haematoxylin and Eosin (H&E)} for synaptophysin and chromogranin was performed, which showed positive immune staining for both markers [Table/Fig-8,9].

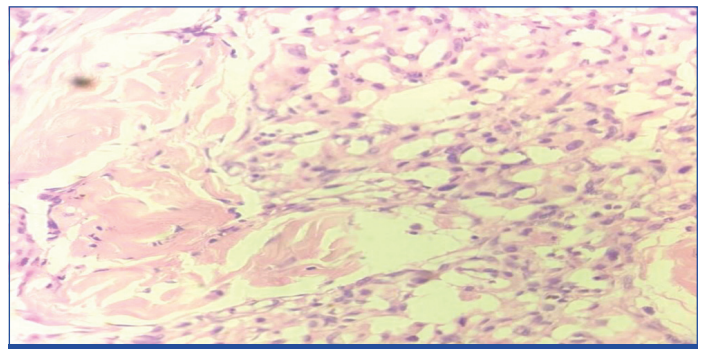
The patient's recovery phase proceeded smoothly, and they were discharged without any neurological abnormalities, except for minor symptoms of hypoesthesia on the right side of the neck. The patient stayed in the hospital for seven days and was released in good clinical condition. The surgical recovery was uncomplicated. After a month, the patient had a follow-up visit at the otolaryngology clinic and expressed satisfaction with the successful surgical resection.



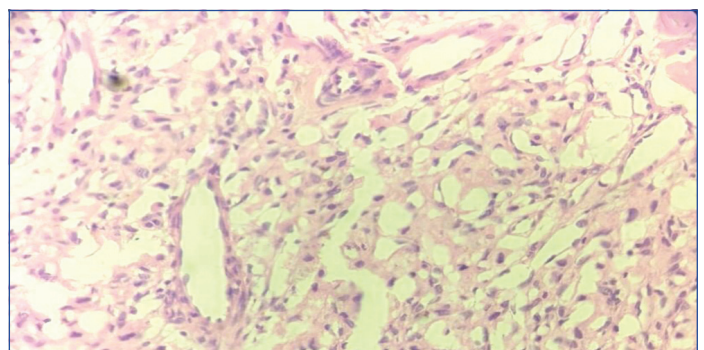
[Table/Fig-6a]: Tumour was composed of nests ("Zellballen pattern") surrounded by delicate vascular septae 10x, H&E.



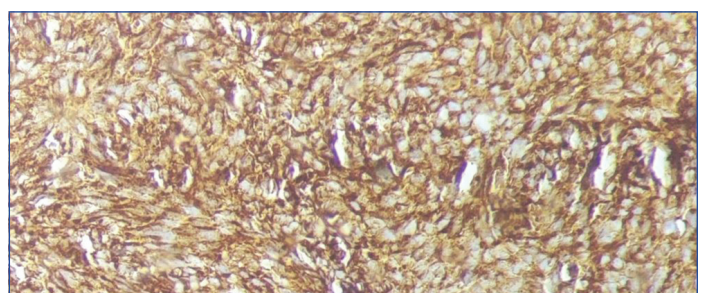
[Table/Fig-6b]: Tumour was composed of nests ("Zellballen pattern") surrounded by delicate vascular septae (10x, H&E).



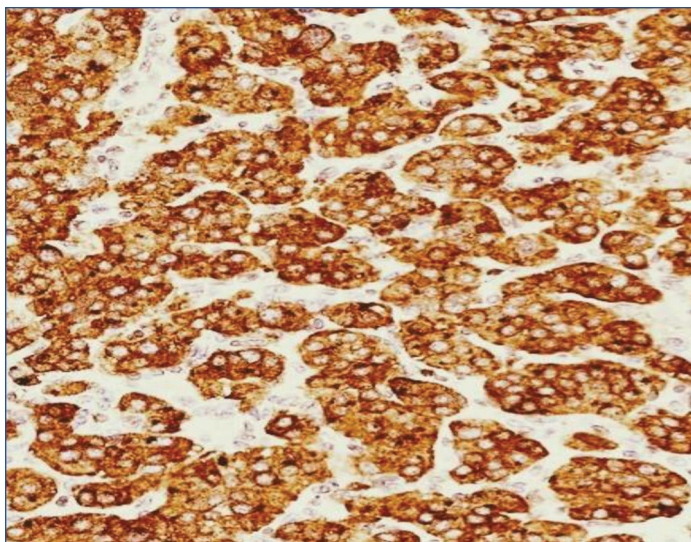
[Table/Fig-7a]: Tumour was composed of nests (Zellballen pattern) (40x, H&E).



[Table/Fig-7b): Tumour was composed of nests (Zellballen pattern) (40x, H&E).



[Table/Fig-8): High power view x40- Immunohistochemistry technique showing strong reactivity with synaptophysin staining (40x, H&E).



[Table/Fig-9]: Strong reactivity with chromogranin staining (40x, H&E).

DISCUSSION

Differentiating between secreting and non secreting tumours is crucial to prevent starting a catecholamine crisis. A hormonal check-up should be done to determine the hormone levels. Prior to using ionic contrast compounds from a previous era for a Computed Tomography (CT) scan, all patients should either undergo alpha blockade or have negative results from a biochemical catecholamine hypersecretion test [1].

The carotid body, the largest collection of paraganglia in the head and neck, is situated in the carotid area. Von Haller published the earliest account of the carotid body in 1743 [2]. It is located in the adventitia of the carotid bifurcation and is innervated by the glossopharyngeal and vagus nerves. Normal carotid body sizes range from 2 to 6 mm, but people living at higher altitudes may have larger carotid bodies. Peripheral chemoreceptors, also known as arterial chemoreceptors, are found along the aorta, its major branches, and at the point where the common carotid arteries split (carotid bodies). Activation of peripheral chemoreceptors stimulates medullary centres, leading to sympathoexcitation and hyperventilation [3,4]. These components are also thought to influence the feeling of dyspnoea [5]. Deactivating carotid bodies has shown promising outcomes in animal models and is being explored as a potential treatment method [6-8]. Carotid Body Tumours (CBTs) are hypervascular, slow-growing tumours that account for about 0.03% of all neoplasms [9]. Rightside tumours are more common (57%) compared to left-side tumours (25%), bilateral tumours (17%), and malignant tumours (10%) [10,11]. Carotid bodies have been shown to be the main structures involved in the reflex ventilatory response to hypoxia.

The traditional method for treating CBTs has been surgical excision. However, radiotherapy is an alternative treatment option that has the potential to slow or stop tumour growth, especially for patients who are unable to undergo surgery due to severe involvement, multiple tumours, or high operating and anaesthetic risks.

In the past, Digital Subtraction Angiography (DSA) was considered the gold standard for diagnosing CBTs. However, with the development of MRI and high-resolution Computed Tomography for Angiography (CTA), DSA is no longer the preferred imaging technique. Nonetheless, preoperative angiography can provide valuable information about the tumour's vascular architecture and collateral circulation [12].

Ultrasound is frequently the initial imaging modality used in patients referred for unusual neck swelling.

A key hint is the displacement of the ICA and ECA, which should warrant further imaging analysis [13]. The parasympathetic paraganglioma precursor was the CBT, which typically has a diameter of 6 cm and develops around or envelops the common carotid artery bifurcation. Tumour tissue ranged in colour from red-pink to

brown. When examined grossly, the tumours are often well-defined and may have a pseudocapsule. Although there may be occasional regions of hemorrhage, the sliced surface was normally solid and had a smooth, rubbery feel. Tumour sizes might vary substantially in reality. Histopathologically, it was common to refer to the distinctive growth pattern of CBTs and paragangliomas as a "Zellballen" growth pattern. This term describes a tumour's well-developed nested or organoid growth pattern, with a stromal component of fragile fibrovascular tissue in between. The majority of the tumour cells are chief cells, which have spherical, hyperchromatic nuclei, scattered chromatin, and copious granular cytoplasm that can range in colour from eosinophil to basophil. There are three different types of CBTs: sporadic, familial, and hyperplastic. Approximately 85% of CBTs are of the sporadic variety, making it the most prevalent kind. According to reports, the onset typically occurs around age 45 years on average. The familial form can occur in 10% to 50% of cases, and in this group, the average age of onset is lower, between the second and fourth decade. Bilateral CBTs are also associated with the familial type, being found in 30-40% of the cases compared to 3-4% of the sporadic type [14].

The hyperplastic type is related to patients with chronic hypoxia, including patients who have Chronic Obstructive Pulmonary Disease (COPD) or cyanotic heart disease. Patients living at a high altitude are also associated with the hyperplastic type [15]. Neuroendocrine markers such as chromogranin, synaptophysin, neuron-specific enolase, and CD56 are heavily stained by the main cells. A network of spindle-shaped stromal cells that are positive for the S-100 protein and collectively known as sustentacular cells also supports the tissue. The precise site of the lesion is a key factor in determining the differential diagnosis of head and neck paragangliomas. Possible differential diagnoses for a tumour developing in the jugulotympanic region include middle ear adenoma, meningioma, and schwannoma. The histological characteristics of CBTs are easier to identify, and other neuroendocrine tumours, including pheochromocytoma and neuroendocrine carcinoma, are included in the differential diagnosis. The overall outlook is quite favourable after a full surgical resection. Nevertheless, ongoing monitoring is required, since metastasis and recurrence may occur in the future.

CONCLUSION(S)

Rare, hypervascular, and slowly growing neuroendocrine tumours are called CBTs. A tentative diagnosis can be formed based on the patient's medical history, physical examination, and radiography. When imaging, CBTs typically displace the ICA and ECA. Surgical resection is the recommended method of treating CBTs. For these uncommon tumours, a multidisciplinary approach involving professionals from different medical specialties enables accurate preoperative assessment, surgical planning, and safe excision, as demonstrated in the present case.

Authors contribution: SS drafted the case report and provided an overview of patient management, while SS reported on the excised specimen sent for histopathological investigation and provided the appropriate diagnosis. All authors have read and approved the final version of the present manuscript.

REFERENCES

- [1] Burnichon N, Brière JJ, Libé R, Vescovo L, Rivière J, Tissier F, et al. SDHA is a tumour suppressor gene causing paraganglioma. *Hum Mol Genet.* 2010;19(15):3011-20.
- [2] Gratiot JH. Carotid body tumours: A collective review. *In Internat Abstr Surg.* 1943;77:177-86.
- [3] Marshall JM. Peripheral chemoreceptors and cardiovascular regulation. *Physiol Rev.* 1994;74(3):543-94.
- [4] O'regan RG, Majcherczyk S. Role of peripheral chemoreceptors and central chemosensitivity in the regulation of respiration and circulation. *J Exp Biol.* 1982;100(1):23-40.
- [5] Buchanan GF, Richerson GB. Role of chemoreceptors in mediating dyspnea. *Respir Physiol Neurobiol.* 2009;167(1):09-19.
- [6] McBryde FD, Abdala AP, Hendy EB, Pijacka W, Marvar P, Moraes DJ, et al. The carotid body as a putative therapeutic target for the treatment of neurogenic hypertension. *Nat Commun.* 2013;4(1):2395.

- [7] Del Rio R, Marcus NJ, Schultz HD. Carotid chemoreceptor ablation improves survival in heart failure: Rescuing autonomic control of cardiorespiratory function. *J Am Coll Cardiol.* 2013;62(25):2422-30.
- [8] Schultz HD, Marcus NJ, Del Rio R. Role of the carotid body in the pathophysiology of heart failure. *Curr Hypertens Rep.* 2013;15(4):356-62.
- [9] Muduroglu A, Yuksel A. Carotid body tumours: A report of three cases and current literature review. *Vascul Dis Ther.* 2017;2(5):01-03.
- [10] Albsoul NM, Alsmady MM, Al-Aardah MI, Altaher RN. Carotid body paraganglioma management and outcome. *Eur J Sci Res.* 2009;37(4):567-74.
- [11] Davis FM, Obi A, Osborne N. Carotid body tumors. Extracranial carotid and vertebral artery disease. Springer, Cham. 2018;253-60.
- [12] Rao AB, Koeller KK, Adair CF. From the archives of the AFIP: Paragangliomas of the head and neck: Radiologic-pathologic correlation. *Radiographics.* 1999;19(6):1605-32.
- [13] Sajid MS, Hamilton G, Baker DM; Joint Vascular Research Group. A multicenter review of carotid body tumour management. *Eur J Vasc Endovasc Surg.* 2007;34(2):127-30.
- [14] Demir T, Uyar I, Demir HB, Sahin M, Gundogdu G. Five-year follow-up of a patient with bilateral carotid body tumours after unilateral surgical resection. *Am J Case Rep.* 2014;15:426.

PARTICULARS OF CONTRIBUTORS:

1. Junior Resident, Department of Pathology, DMIHER, Wardha, Maharashtra, India.
2. Professor, Department of Pathology, DMIHER, Wardha, Maharashtra, India.
3. Professor, Department of Pathology, DMIHER, Wardha, Maharashtra, India.
4. Professor, Department of Pathology, DMIHER, Wardha, Maharashtra, India.
5. Professor, Department of Pathology, DMIHER, Wardha, Maharashtra, India.

NAME, ADDRESS, E-MAIL ID OF THE CORRESPONDING AUTHOR:

Shakti Sagar,
Junior Resident, Department of Pathology, Jawaharlal Nehru Medical College,
Sawangi, Wardha-442005, Maharashtra, India.
E-mail: chiku.shakti@gmail.com

AUTHOR DECLARATION:

- Financial or Other Competing Interests: None
- Was informed consent obtained from the subjects involved in the study? Yes
- For any images presented appropriate consent has been obtained from the subjects. Yes

PLAGIARISM CHECKING METHODS: [Jain H et al.]

- Plagiarism X-checker: Jul 19, 2023
- Manual Googling: Aug 22, 2023
- iThenticate Software: Sep 01, 2023 (11%)

ETYMOLOGY: Author Origin**EMENDATIONS:** 7

Date of Submission: **Jul 18, 2023**
Date of Peer Review: **Aug 17, 2023**
Date of Acceptance: **Sep 06, 2023**
Date of Publishing: **Dec 01, 2023**