

Bacillary Angiomatosis of Lymph Nodes: Unusual Case Presentation in an Immunocompetent Adolescent

DEEPIKA GURUMURTHY¹, VANI KRISHNAMURTHY², SUCHITHA SATISH³,
SUDHAMSHU KALASAPURA CHANDRASHEKAR⁴, SUSHMA HULIKERE MALLARADHYA⁵



ABSTRACT

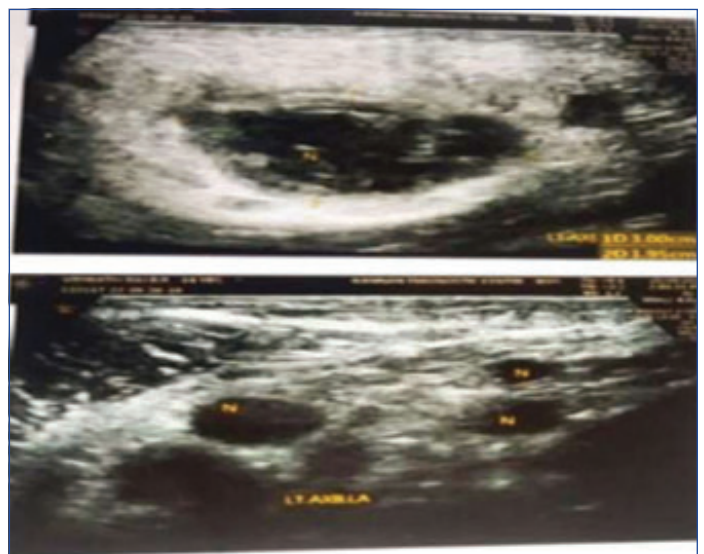
Bacillary angiomatosis is a neovascular proliferative condition caused by the Bartonella group of opportunistic bacteria, commonly occurring in patients with advanced Human Immunodeficiency Virus (HIV) and other immunocompromised conditions. However, cases have also been reported to occur rarely in immunocompetent individuals. Skin lesions such as nodules and papules are the most common manifestations, although cases have been rarely reported in other sites such as the oral cavity, respiratory tract, gastrointestinal tract, and bones. Isolated lymph node involvement or systemic manifestations such as fever, chills, anorexia, and weight loss are very rare. Since Bartonella is a fastidious Gram-negative bacterium that is difficult to grow and isolate in culture, diagnosis relies on histological examination of the affected organ/tissue and demonstration of the causative bacteria using special stains such as Warthin-Starry, Giemsa, Gram's, and silver stains. Herein, the authors presented a case of bacillary angiomatosis in a 14-year-old immunocompetent adolescent male who presented with recurrent fever and painful enlargement of the axillary lymph nodes. The case is notable for its unusual clinical manifestations of systemic symptoms, specifically anorexia and significant weight loss, leading to suspicion of malignancy. Following the establishment of the diagnosis, the boy experienced complete recovery, with regained appetite and weight, following treatment with a long duration of antibiotics.

Keywords: Bartonella, Epithelioid angiomatosis, Immunocompetent

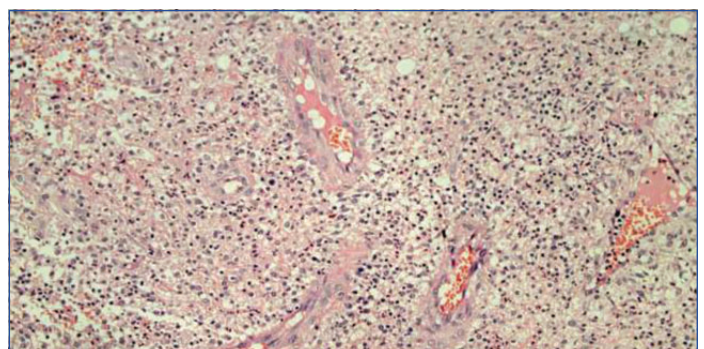
CASE REPORT

A 14-year-old male presented with a history of recurrent fever (seven episodes over a period of three months), loss of appetite, and significant weight loss of around 20 kilograms. According to the mother, the boy weighed 69 kilograms previously and was only 49 kilograms when the patient was admitted. Clinical examination revealed tender lymphadenopathy in the left axilla. Apart from this, the rest of the examination was unremarkable. The patient was studying in a residential school, and neither the family nor anyone in the residential school had any similar complaints. The patient had no history of recurrent infections or chronic illnesses like tuberculosis or malignancy. He was not on any medications like steroids or immunosuppressive drugs. Ultrasound evaluation of the left axilla revealed a lymph node measuring 3×3 cm displaying a necrotic center and preserved hilum [Table/Fig-1]. Fine Needle Aspiration Cytology (FNAC) was performed earlier at a previous clinic and was reported as acute lymphadenitis. The complete blood count showed neutrophilic leukocytosis. Urine analysis, erythrocyte sedimentation rate, and biochemical tests were within normal limits. The screening tests for hepatitis B and hepatitis C were negative. Serological tests for HIV were negative.

Considering the pathology to be inflammatory in nature, the lesion was surgically excised in fragments, purulent exudate was drained, and the tissue fragments were subjected to histological examination. Pus culture yielded no growth, and the Cartridge Based Nucleic Acid Amplification Test (CBNAAT) for tuberculosis was negative. Histological examination revealed sheets of histiocytes, foamy macrophages, multinucleated giant cells, and a polymorphic population of inflammatory cells consisting of plasma cells, lymphocytes, neutrophils, and eosinophils [Table/Fig-2]. Myriads of vascular channels lined by plump endothelial cells were also seen. Given the significant weight loss and the presence of sheets of histiocytes, histiocytic neoplasm was considered as one of the primary differential diagnoses.

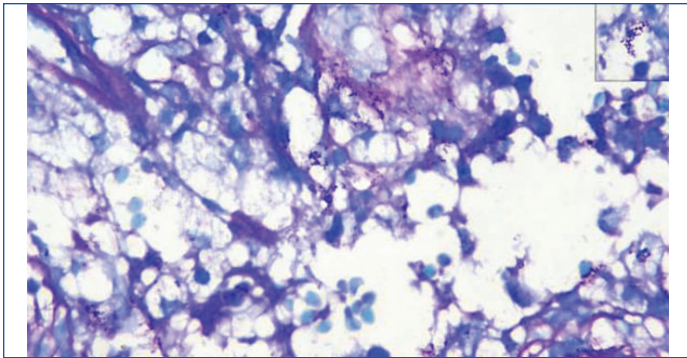


[Table/Fig-1]: Ultrasonographic image of axillary lymph node showing central necrosis (N) with preserved hilum.



[Table/Fig-2]: The histopathological section shows proliferating small blood vessels lined by prominent endothelial cells and mixed inflammatory cells consisting of histiocytes, macrophages, neutrophils, eosinophils, and lymphocytes (H&E, 200X).

Immunohistochemistry was performed to rule out histiocytic neoplasm, and immunohistochemical staining with Cluster of Differentiation 38 (CD38) highlighted histiocytes. CD1a and langerin suggested that the lesion was inflammatory by observing the polyclonal nature of inflammatory cells, as well as histiocytes. Special staining with Gram's, Giemsa, and silver stains was conducted to look for any organisms. Gram-negative coccobacillary forms of bacteria were observed within the macrophages as well as in extracellular locations in sheets, clusters, and singles. The bacteria appeared dark blue, silver, purple with Giemsa [Table/Fig-3] and black (silver positive) with silver staining. The diagnosis of bacillary angiomatosis was made based on the histology of the lesion and the morphology of the detected organisms on tissue sections with special stains.



[Table/Fig-3]: The section stained with Giemsa stain shows groups and clusters of purplish coccobacilli in intracellular and extracellular locations. Inset: showing an intracellular cluster of coccobacilli (Giemsa, 1000X).

The patient was managed by the paediatrician with long-term antibiotics (100 mg doxycycline, twice daily, for six weeks). Clinical resolution of fever and improvement in general condition, along with an improvement in appetite and weight gain, was observed shortly after commencing appropriate antibiotics. During the last follow-up, the patient's weight had improved to 57 kilograms.

DISCUSSION

Immunocompetent humans host many microorganisms, either in a symbiotic or inconsequential relationship. If a subject becomes immunocompromised for any reason, this balance gets altered, and the previously considered "innocuous microorganisms" can become pathogenic, resulting in disease. Bacillary angiomatosis, also known as epithelioid angiomatosis, is an angioproliferative condition that typically occurs as an opportunistic infection. It was first diagnosed in a patient with Acquired Immune Deficiency Syndrome (AIDS) in 1983 [1]. Since then, many cases of bacillary angiomatosis have been reported mainly in HIV-infected individuals with severe CD4 depletion and also in immunocompromised hosts [2,3].

Human infection has rarely been reported in immunocompetent individuals [4-6]. The patient in the present case was immunocompetent with negative HIV, Hepatitis B surface Antigen (HBsAg), and Hepatitis C Virus (HCV) tests, and there was no history of recurrent infections, chronic illnesses, or medication use. Bacillary angiomatosis is known to be caused by direct spread or transmission through vectors. The source of infection may remain undetected in a few cases. Cats are considered the major reservoir of the organism, with fleas being the vectors of disease transmission. In immunocompetent subjects, the infection is known as cat scratch disease [4]. Among the 19 species of *Bartonella* described so far, *B. bacilliformis*, *B. quintana*, and *B. henselae* are the most commonly described pathogens affecting immunocompromised human hosts. Clinically, skin lesions such as papules, warts, hyperkeratotic plaques, subcutaneous nodules, and pedunculated lesions that can sometimes ulcerate and bleed are common presentations [7,8]. Bacillary angiomatosis presenting as isolated lymphadenopathy is very rare [9]. Systemic symptoms such as fever, chills, anorexia, and weight loss are also rarely observed [9].

In the present case, the subject was otherwise a healthy immunocompetent adolescent with systemic manifestations such as fever, loss of appetite, and significant weight loss mimicking malignancy. Left axillary swelling noticed on examination was a group of enlarged necrotic lymph nodes, which were drained by surgical incision, and the remaining tissue was excised in fragments. Microscopic examination revealed sheets of histiocytes mixed with other inflammatory cells. The history of significant weight loss and recurrent fever raised suspicion of malignancy, specifically histiocytic neoplasm. However, immunohistochemistry confirmed the inflammatory nature of the lesion. Special staining of the tissue sections with Giemsa and silver stains demonstrated clusters and groups of coccobacilli, both intracellularly and extracellularly, morphologically resembling *Bartonella* species. The final diagnosis of bacillary angiomatosis was made based on the typical histological features and identification of the organism. A similar systemic presentation with fever, weight loss, respiratory distress, lymphadenopathy, oedema, and widespread angiomatous papules has been reported in a 49-year-old HIV positive male by Rueda M et al., [10]. Balaban M et al., also reported a case of bacillary angiomatosis with facial lesions sustained following a road traffic accident in a healthy, immunocompetent Caucasian male aged 42 years [4]. Cases of bacillary angiomatosis in immunocompetent subjects triggered by trauma have been described in the literature [6,11,12].

In a case literature review, Psarros G et al., discussed 29 cases of *Bartonella* infection in solid organ transplant recipients [3]. Eight of them had localised forms of cat scratch disease, while the rest had disseminated forms of the disease. The majority of patients (90%) had a history of cat exposure. However, in the index case, there was no history of cat or any other feline animal exposure prior to the onset of illness. Another case of bacillary angiomatosis was reported in a 59-year-old immunocompetent woman who had no previous exposure to cats. She presented with fever and a subcutaneous nodule with ulceration on the left ankle [5]. Cases of bacillary angiomatosis have also been reported following burn injuries in otherwise healthy and immunocompetent individuals, as well as in HIV negative patients with chronic hepatitis B infection [6].

Since *Bartonella* are fastidious Gram-negative bacteria, they are extremely difficult to isolate in culture. Diagnostic modalities other than tissue culture include serological tests (indirect immunofluorescent antibody test) and detection of the organisms' Deoxyribonucleic Acid (DNA) by Polymerase Chain Reaction (PCR), in addition to clinical and histopathological examination. Staining tissue sections with Warthin-Starry, Giemsa, and silver stains has enabled the identification of these organisms. Long-term treatment with macrolide antibiotics such as erythromycin, clarithromycin, and tetracycline/doxycycline is effective in resolving the disease and preventing recurrence [13].

CONCLUSION(S)

Bacillary angiomatosis is caused by *Bartonella* species and is commonly seen in immunocompromised individuals. It is very rare in immunocompetent individuals. The unusual presentation of isolated lymph node involvement with systemic manifestations such as recurrent fever, anorexia, and significant weight loss qualifies the present case for scientific reporting and discussion. The index case also highlights the importance of using special stains on tissue sections to demonstrate the presence of the organisms and confirm the diagnosis.

REFERENCES

- [1] Stoler MH, Bonfiglio TA, Steigbigel RT, Pereira M. An atypical subcutaneous infection associated with acquired immune deficiency syndrome. *Am J Clin Pathol.* 1983;80(5):714-18.
- [2] Schwartz RA, Gallardo MA, Kapila R, Gascón P, Herscu J, Siegel I, et al. Bacillary angiomatosis in an HIV seronegative patient on systemic steroid therapy. *Br J Dermatol.* 1996;135(6):982-87.

- [3] Psarros G, Riddell J, Gandhi T, Kauffman CA, Cinti SK. Bartonella henselae infections in solid organ transplant recipients: Report of 5 cases and review of the literature. *Medicine (Baltimore)*. 2012;91(2):111-21.
- [4] Balaban M, Ioana Nedelcu R, Balmes G, Adela Todorovic T, Brinzea A, Nichita L, et al. Bacillary angiomatosis triggered by severe trauma in a healthy Caucasian patient: A case report. *Exp Ther Med*. 2020;20(1):56-60.
- [5] Bernabeu-Wittel J, Luque R, Corbí R, Mantrana-Bermejo M, Navarrete M, Vallejo A, et al. Bacillary angiomatosis with atypical clinical presentation in an immunocompetent patient. *Indian J Dermatol Venereol Leprol*. 2010;76(6):682-85.
- [6] Karakaş M, Baba M, Aksungur VL, Homan S, Memisoğlu HR, Uğuz A. Bacillary angiomatosis on a region of burned skin in a immunocompetent patient. *Br J Dermatol*. 2000;143(3):609-11.
- [7] Spach DH, Koehler JE. Bartonella-associated infections. *Infect Dis Clin North Am*. 1998;12(1):137-55.
- [8] Maguiña C, Gotuzzo E. Bartonellosis. New and old. *Infect Dis Clin North Am*. 2000;14(1):01-22.
- [9] Akram SM, Anwar MY, Thandra KC, Rawla P. Bacillary Angiomatosis. In: *StatPearls* [Internet]. Treasure Island (FL): StatPearls Publishing; 2022 [cited 2023 Mar 7]. Available from: <http://www.ncbi.nlm.nih.gov/books/NBK448092/>.
- [10] Rueda M, Torres N, Ventura A. Bacillary angiomatosis compatible with systemic manifestations: A case report. *HIV & AIDS Review*. 2019;18(1):74-77.
- [11] Kaçar N, Taşlı L, Demirkan N, Ergin C, Ergin S. HIV-negative case of bacillary angiomatosis with chronic hepatitis B. *J Dermatol*. 2010;37(8):722-25.
- [12] Turgut M, Alabaz D, Karakaş M, Kavak M, Aksaray N, Alhan E, et al. Bacillary angiomatosis in an immunocompetent child with a grafted traumatic wound. *J Dermatol*. 2004;31(10):844-47.
- [13] Agrawal S, Singal A, Arora VK. Bacillary Angiomatosis in an immunocompetent patient: An unusual occurrence. *Indian Dermatol Online J*. 2022;13(4):527-29.

PARTICULARS OF CONTRIBUTORS:

1. Senior Resident, Department of Pathology, JSSAHER, Mysuru, Karnataka, India.
2. Associate Professor, Department of Pathology, JSSAHER, Mysuru, Karnataka, India.
3. Professor, Department of Pathology, JSSAHER, Mysuru, Karnataka, India.
4. Assistant Professor, Department of Paediatric Surgery, JSSAHER, Mysuru, Karnataka, India.
5. Senior Resident, Department of Pathology, JSSAHER, Mysuru, Karnataka, India.

NAME, ADDRESS, E-MAIL ID OF THE CORRESPONDING AUTHOR:

Dr. Sushma Hulikere Mallaradhya,
Senior Resident, Department of Pathology, JSS Medical College, JSSAHER,
Mysuru-570004, Karnataka, India.
E-mail: sushgiri2010@gmail.com

PLAGIARISM CHECKING METHODS: [Jain H et al.]

- Plagiarism X-checker: Jun 20, 2023
- Manual Googling: Aug 11, 2023
- iThenticate Software: Oct 24, 2023 (10%)

ETYMOLOGY: Author Origin**EMENDATIONS:** 6**AUTHOR DECLARATION:**

- Financial or Other Competing Interests: None
- Was informed consent obtained from the subjects involved in the study? Yes
- For any images presented appropriate consent has been obtained from the subjects. Yes

Date of Submission: **Jun 24, 2023**Date of Peer Review: **Jul 25, 2023**Date of Acceptance: **Oct 26, 2023**Date of Publishing: **Nov 01, 2023**