

# Thyroid Abscess in Immuno Compromised Patient: A Case Report

YAMANUR P. LAMANI, S.I. BASARKOD, S.R. TELKAR, B.V. GOUDAR, UDAY AMBI

## ABSTRACT

Thyroid abscess is a rare condition of the thyroid gland. The ability of thyroid gland is to resist infection which is well known and the infection in thyroid gland is rare, particularly so with the

advent of widespread usage of antibiotics. Thyroid abscess represents only 0.1 to 0.7% of surgically treated thyroid pathologies. We report here a case of adult female with HIV infection who presented with thyroid abscess.

**Key Words:** Abscess, Staphylococcal aureus, Thyroiditis

## INTRODUCTION

Acute suppurative thyroiditis (AST) leading to thyroid abscess is a rare clinical entity. AST affects specially patients with pre-existing thyroid gland pathology and in childhood it is associated with local anatomic defects. Because of its rarity and unusual clinical features, the diagnosis of thyroid abscess is often delayed. Thyroid abscess is infrequently encountered condition with a rarity that is attributed to anatomic and physiologic characteristics of the gland that imparts a unique quality of infection of resistance. When discovered a thyroid abscess, it presents as acutely as a painful swelling. The differential diagnosis for a painful thyroid is limited, with sub-acute and chronic thyroiditis being the most often encountered process.

## CASE REPORT

A 28-year old female presented with an enlarging painful neck swelling of one month duration. There was a history of mild to moderate degree fever and odonophagia since the onset of the swelling. Pain was described as constant and radiating to the occipital region. On admission patient was febrile, tachycardia but no evidence of respiratory distress. Examination of the neck revealed a swelling occupying in the region of thyroid more prominent on the right than on the left. The swelling was tender and fluctuant, movement with deglutition was present and there was no movement with protrusion of tongue. No cervical lymphadenopathy was found.

Laboratory investigations revealed leucocyte count of more than 15000 with 80% of polymorphs; haemoglobin of 9% with HIV infection. USG neck demonstrated a cystic swelling in the right lobe of the thyroid suggestive of thyroid abscess. Needle aspiration of the swelling obtained thick yellow pus and culture yielded *Staphylococcal aureus*, thyroid function test was normal. Patient underwent ultrasound guided by aspiration with wide bore needle, and given intravenous antibiotics according to the culture sensitivity report. Patient was followed up after one month there was gross regression in the size of the swelling and pain.

## DISCUSSION

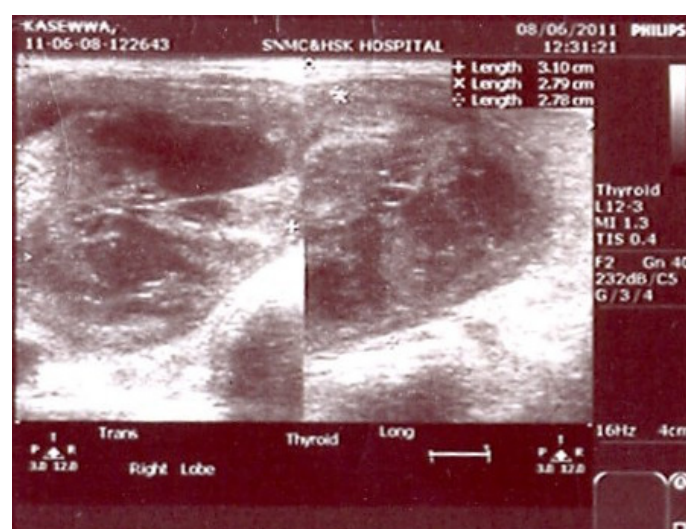
Thyroid abscess is an infrequently encountered condition, with a rarity that is attributable to the anatomic and physiologic

characteristics of the gland that imparts a unique quality of infection resistance [1].

The remarkable resistance of the thyroid gland to infection is attributable to many factors. A prosperous lymphatic and vascular supply, well developed capsule, high iodine content of the gland have various mechanisms suggested to account for this relative resistance to infection [2].

Abscess formation of thyroid most commonly arises in pediatric population in the setting of anatomic anomalies of the hypopharyngeal region, leading to the development of a pyriform sinus fistula. In the adult population, multiple etiologies have been proposed. Abscess development secondary to direct trauma from foreign bodies, such as fine needle aspiration, fish bone and chicken bone penetration have been described, as well as extension from neighboring anatomic structures [3-5]. However hematogenous spreading from a distant site is considered to be the most common cause of infection, even though the exact infectious source or pathology is frequently unknown [6].

The most common causative organisms have historically been Staphylococci and Streptococci species and cultures are more



**[Table/Fig-1]:** USG neck showing abscess in the right lobe of the thyroid gland

often polymicrobials, other organisms isolated such as Acinetobacter, Mycobacterium, Coccidioides, Pseudomonas, Salmonella, Eikenella, Clostridium, Nocardia, Pneumocystis carinii, Hemophilus and Candida species have been identified, although they are most commonly associated with immunosuppressed patients [6], [8-16]. Acute suppurative thyroiditis has also been associated with immunosuppression, especially human immune-deficiency virus [15]. Patients infected with HIV, however still develop Mycobacterial and fungal thyroid infection with some regularity. AST has been associated with transient hyperthyroidism and was caused by Pasteurella multocida [7].

Because of its rarity the incidence of thyroid abscess formation is difficult to identify. That data are equivocal regarding whether thyroid abscesses occur more frequently in men or women. Hazard et al [3] observed a more common occurrence in the women in the age range of 20-40 years, whereas large reviews by Yu et al [17] and Burger et al [18] both revealed a more uniformed distribution among the sexes.

Acute suppurative thyroiditis responds well to antibiotics (Intravenous) with or without incision drainage of the abscesses and rarely causes external fistula. Our patient was a female aged 28 years with immunocompromised state presented with painful swelling in the region of thyroid, underwent USG guided aspiration of the pus and culture showed Staphylococcal aureus and she was managed with intravenous antibiotics for 7 days. Follow up done after one month there was complete regression of the swelling and pain.

## REFERENCES

- [1] Herdon, Mark D, Christie, et al. Thyroid abscess: Case report and review of literature. *Am Surg* 2007; 73:725-28.
- [2] Schweitzer VG, Olson NR. *Thyroid abscess Otolaryngol Head Neck Surg* 1981; Mar-Apr, 89(2):226-29.
- [3] Hazard JB. Thyroiditis: A review – Part I. *Am J Clin Pathol* 1995; 25: 289-98.
- [4] Coret A, Heyman Z, Bendet E, et al. Thyroid abscess resulting from transoesophageal migration of a fish bone: Ultrasound appearance. *J Clin Ultrasound* 1993; 21:152-54.
- [5] Yung BC, Loke TK, Fan WC, et al. Acute suppurative thyroiditis due to foreign body induced retropharyngeal presented as thyrotoxicosis. *Clin Nucl Med* 2000; 35:249-52.
- [6] Jacobs A, Gros DC, Gradon JD. Thyroid abscess due to Acinetobacter calcoaceticus: Case report and review of the causes of and current management strategies of thyroid abscesses. *South Med J* 2003; 96: 300-07.
- [7] McLaughlin SA, Smith SL, Meek SE. 2006 Acute suppurative thyroiditis caused by Pasteurella multocida and associated with thyrotoxicosis. *Thyroid* 16: 307-10.
- [8] Pandita D, Carson PJ. Thyroid abscess caused by Mycobacterium chelonae. *Clin Infect Dis* 1999; 28:1183-84.
- [9] Smilack JD, Argueta R. Coccidial infection of the thyroid. *Lntern Med* 1998; 158: 89-92.
- [10] Ameh EA, Sabo SY, Nmadu PT. The risk of infective thyroiditis in nodular goiter. *East Afr Med J* 1998; 75: 425-27.
- [11] Gudipati S, Westblom TU. Salmonellosis initially seen as thyroid abscess. *Head Neck* 1991; 13:153-55.
- [12] Vichyanoud P, Howard CP, Olson LC. Eikenella corrodens as a cause of thyroid abscess. *Am J Dis Child* 1983; 137:971-3.
- [13] Michel RG, Hall DM, Woodard BH. Gas forming suppurative thyroiditis. *Ear Nose Throat J* 1981; 60:127-30.
- [14] Vandome A, Pageaux GP, Bismuth M et al. Nocardiosis revealed by thyroid abscess in a liver-kidney transplant recipient. *Transplant Int* 2001; 14:202-04.
- [15] Golshan MM, MacHenry CR, DeVente J et al. Acute suppurative thyroiditis and necrosis of the thyroid gland: A rare endocrine manifestation of acquired immunodeficiency syndrome. *Surg* 1997; 121:593-96.
- [16] Diez O, Anorbe E, Asia P, et al. Acute suppurative thyroiditis secondary to pyriform sinus fistula: A case report. *Eur J Radiol* 1998; 29:25-7.
- [17] Yu EH, Ko WC, Chuang YC, et al. Suppurative Acinetobacter baumannii thyroiditis with bacteremic pneumonia: A case report and review. *Clin Infect Dis* 1998; 27: 1286-90.
- [18] Berger SA, Zonszein J, Villamena P. Infectious diseases of thyroid gland. *Rev Infect Dis* 1983; 5: 108-22.

### AUTHOR(S):

1. Dr. Yamanur P. Lamani
2. Dr. S.I. Basarkod
3. Dr. S.R. Telkar
4. Dr. B.V. Goudar
5. Dr. Uday Ambi

### PARTICULARS OF CONTRIBUTORS:

1. Assistant Professor, Dept of Surgery, SN Medical College, Navanagar, Bagalkot, India.
2. Associate Professor, Dept of Surgery, SN Medical College, Navanagar, Bagalkot, India.
3. Assistant Professor, Dept of Surgery, SN Medical College, Navanagar, Bagalkot, India.
4. Associate Professor, Dept of Surgery, SN Medical College, Navanagar, Bagalkot, India.

5. Assistant Professor, Dept of Anaesthesiology, SN Medical College, Navanagar, Bagalkot, India.

### NAME, ADDRESS, TELEPHONE, E-MAIL ID OF THE CORRESPONDING AUTHOR:

Dr. Y.P. Lamani  
Department of Surgery  
SN Medical College, Navanagar, Bagalkot, India.  
Phone: 9986293013  
E-mail: dryplamani@gmail.com

### FINANCIAL OR OTHER COMPETING INTERESTS:

None.

Date of Submission: **Nov 02, 2011**  
Date of Peer Review: **Dec 11, 2011**  
Date of Acceptance: **Dec 22, 2011**  
Date of Publishing: **Feb 15, 2012**