

Secondary Healing of Palatal Fistula by Simple Palatal Plate Obturator after Excision of Pleomorphic Adenoma- A Case Report

A SENTHIL KUMAR¹, YASEER ARAFAT², Y NAREN KUMAR³, UNAIZ EJAZ KALSEKAR⁴



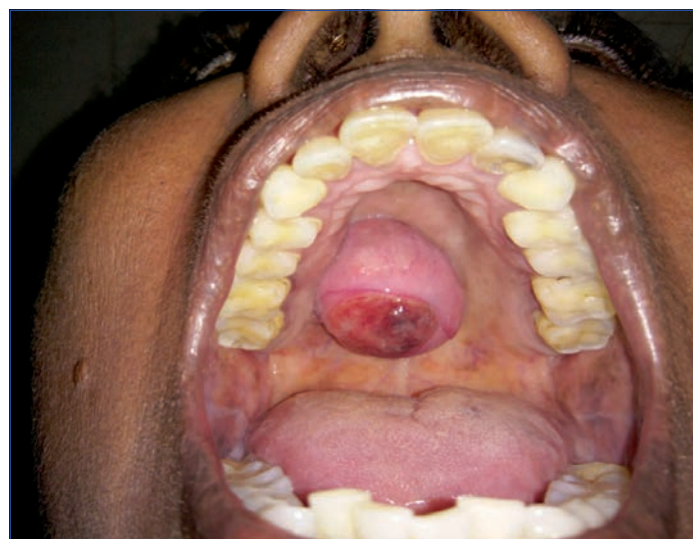ABSTRACT

Pleomorphic adenomas are the most common benign mixed tumours of the salivary glands. They typically occur at the junction between the hard and soft palate, but can also be found in the upper lip, buccal mucosa, floor of the mouth, tonsils, pharynx, and retromolar trigone. The present case of a 55-year-old woman focuses on the use of a palatal plate obturator to treat a soft palatal fistula that developed after the removal of a pleomorphic adenoma from the palate. By applying a self-cure resin to the posterior border of the palatal plate obturator, the postoperative issue of a palatal fistula was successfully managed. To aid in the healing of the palatal tissue and provide a scaffold for the regeneration of the surrounding palatal tissue, relief was applied to the intaglio surface of the palatal plate.

Keywords: Hard palate, Regeneration, Salivary glands, Self-cure resin

CASE REPORT

A 55-year-old woman presented with a complaint of swelling above her palate for the past six months. The swelling initially started as a pea-sized lump and gradually increased in size. She experienced occasional pinching pain of moderate intensity, occurring four or five times a week. Additionally, she had difficulties with swallowing, but there were no symptoms of halitosis or pus discharge from the site. Intraoral examination revealed a roughly 2x2 cm pedunculated swelling on the palate, which felt smooth to touch. Ulcerations were observed on the mucosa surrounding the swelling [Table/Fig-1]. Palpation revealed that the swelling was firm and attached to the underlying bone. No palpable cervical lymph nodes were detected, and a needle aspiration performed on the swelling yielded negative results.

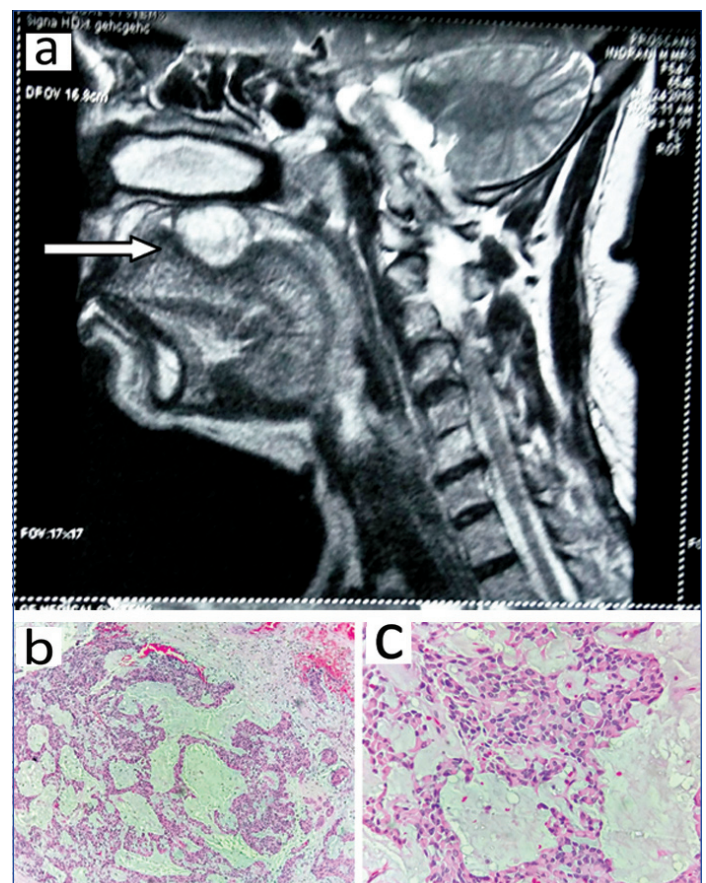


[Table/Fig-1]: Pre-op photo showing tumour-like mass over the hard palate region.

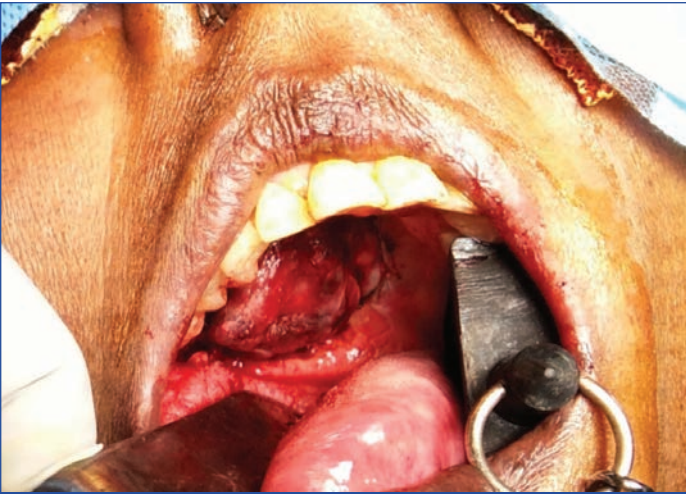To assess the involvement of cervical lymph nodes and the hard palate, a Magnetic Resonance Imaging (MRI) of the neck was conducted [Table/Fig-2]. The MRI revealed scalloped erosion on the hard palate and a lobulated swelling on the inferior part of the hard palate.

An incisional biopsy was performed, which indicated the presence of myoepithelial cells with eosinophilic cytoplasm, suggestive of

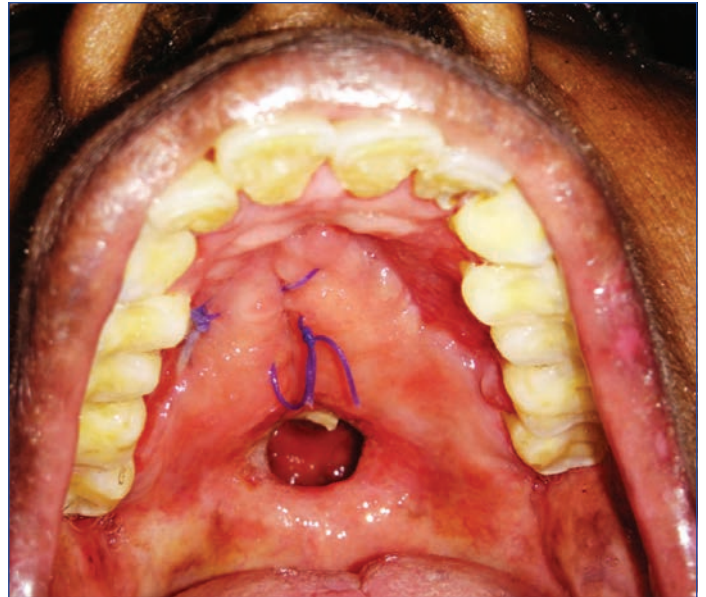
pleomorphic adenoma. The histopathological findings confirmed the presence of myoepithelial cells [Table/Fig-2a-c]. These findings were compared with the MRI results, which showed a well-lobulated mass on the hard palate, and the clinical examination, leading to a diagnosis of pleomorphic adenoma of the palate. A large local excision with a 1 cm clearance around the tumour was planned due to the MRI indicating scalloped bone erosion on the hard palate [Table/Fig-3].



[Table/Fig-2]: a) Preoperative MRI showing the presence of a well-defined lobulated T2 hyperintense lesion over the hard palate (by arrow below); b) Low resolution histopathological image showing myoepithelial cells; c) High resolution histopathological image showing eosinophilic cytoplasm and mesenchymal cells.



[Table/Fig-3]: Intraoperative images showing the excision of the lesion.



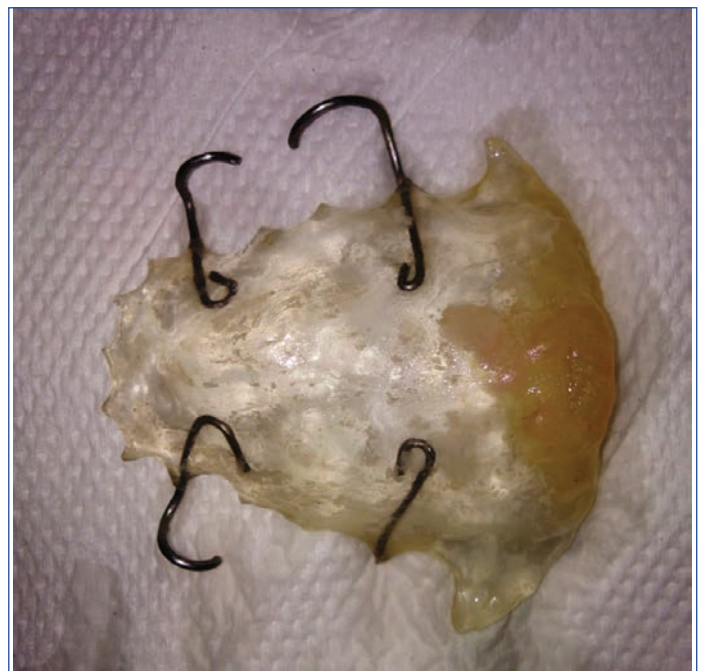[Table/Fig-5]: Postoperative wound dehiscence.

Surgical Procedure

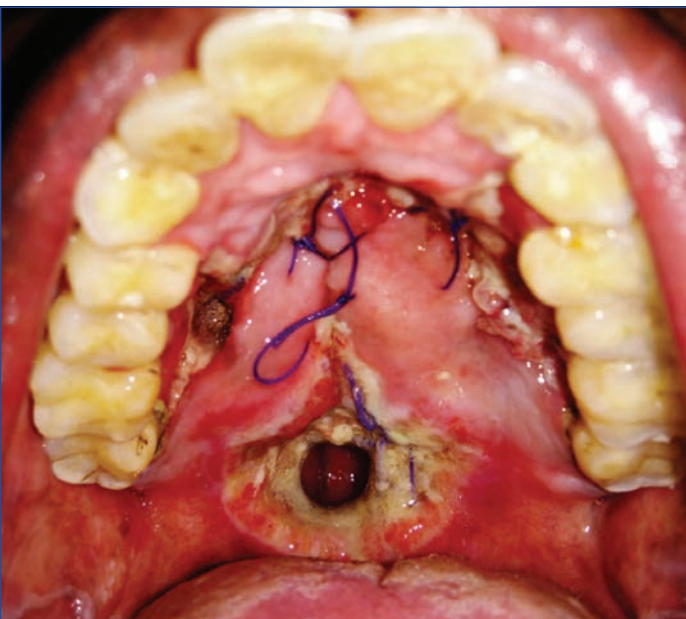
Nasoendotracheal intubation was used to induce and maintain general anaesthesia in a completely aseptic environment. A palate incision with 1 cm wide margins was made around the palatal tumour. A full-thickness flap was elevated, and a wide local excision was performed around the lesion on the hard palate using a 703 TC bur, leaving a 1cm clearance on the palate.

After the tumour was excised, a 3 cm surgical palatal defect remained. A primary repair for this defect was planned using the double palatoplasty method with 3-0 Vicryl suture material [Table/Fig-4]. The patient was extubated once the suturing was completed, and postoperative follow-up was conducted [Table/Fig-4]. However, after two months, a postoperative complication in the form of a palatal fistula was observed [Table/Fig-5].

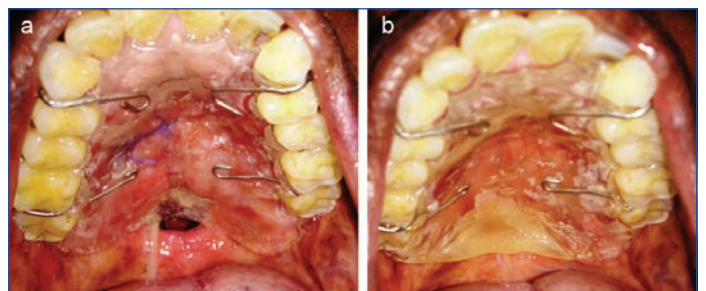
To avoid the need for a second surgical intervention to repair the palatal defect, a simple palatal plate obturator was considered. In order to prevent the rubber-based impression material from entering the nasal cavity during the impression-taking process, a gauze was placed on top of the rubber-based impression material with a custom tray before fabricating the palatal plate [Table/Fig-6]. The palatal plate was fabricated from this impression, with two clasps on the first premolar and first molar bilaterally [Table/Fig-6]. Initially, the palatal plate's extension was short and did not cover the palatal defect. However, it was extended using self-cure acrylic material on the posterior border of the palatal plate to cover the entire defect [Table/Fig-7a,b]. The extended self-cure acrylic resin acted as



[Table/Fig-6]: Fabrication of a palatal plate.



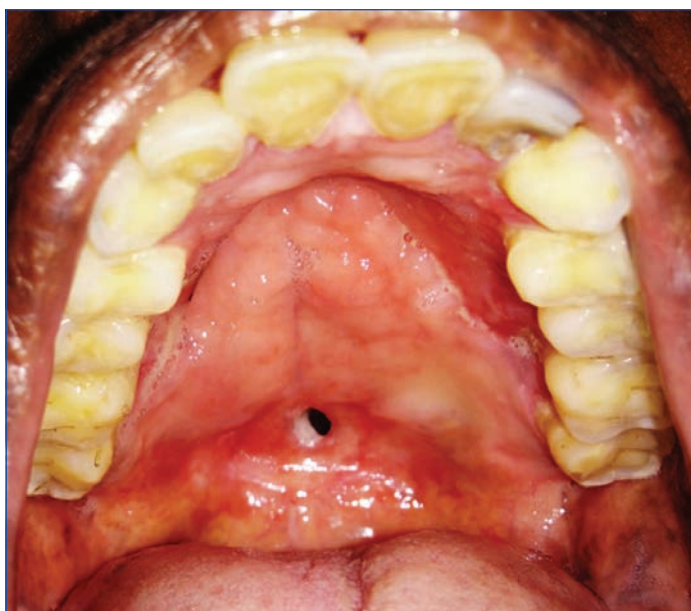
[Table/Fig-4]: After re-approximation of the flap and presence of exposed bare bone over excision site.



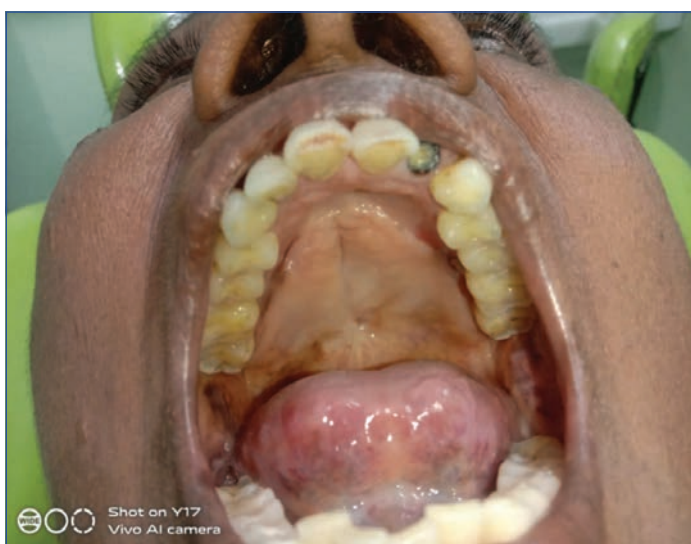[Table/Fig-7]: a) Initial extension of palatal plate and presence of a dehiscenced wound; b) Final extensions of the palatal plate.

a scaffold for palatal tissue growth. The palatal plate served as a supporting scaffold for the surrounding palatal tissue to grow.

During regular two-week follow-up appointments, the tissue surrounding the palatal fistula was de-epithelialised using a no. 11 blade, and the interior surface of the palatal plate (contacting the tissue) was adjusted and appropriately trimmed to provide 1 mm relief from the palatal tissue surface. This was done to avoid excessive pressure from the plate during the secondary healing of the palatal tissue [Table/Fig-8]. The palatal tissues were fully healed during subsequent follow-up visits after six months [Table/Fig-9].



[Table/Fig-8]: Postoperative follow-up after 6 months.



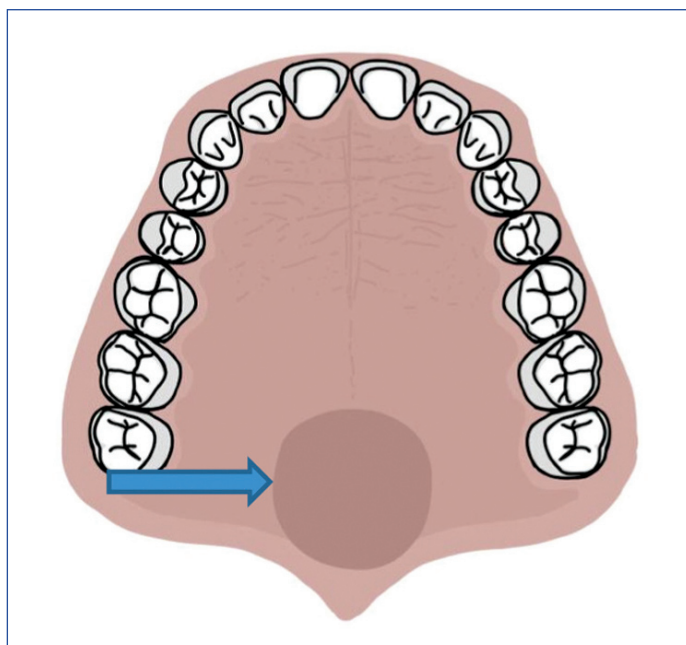
[Table/Fig-9]: Post-op image after complete healing of the palatal defect.

DISCUSSION

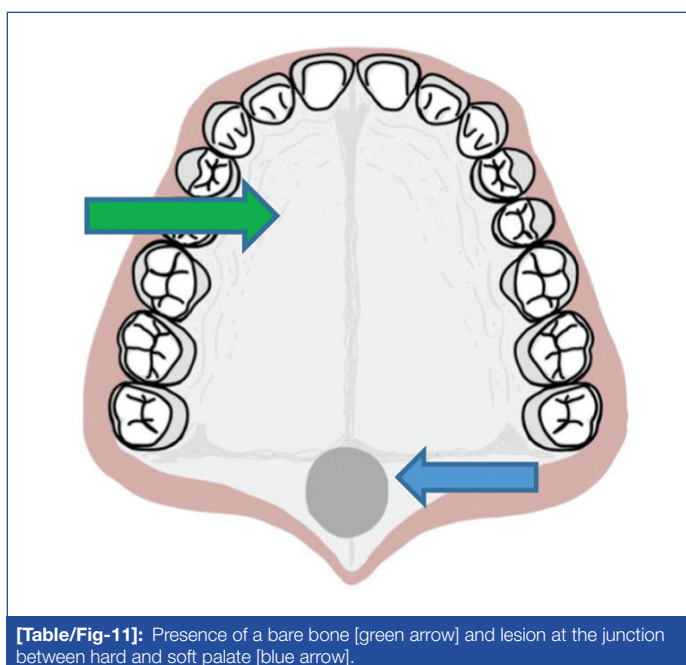
Pleomorphic adenoma is one of the most common salivary neoplasms in the oral cavity. It primarily occurs in the palate, particularly at the junction of the soft and hard palate. It can also be found in other locations such as the upper lip, buccal mucosa, floor of the mouth, tongue, tonsil, and pharynx [1]. Pleomorphic adenomas usually present as hard, painless masses that grow slowly and may be accompanied by mucosal ulcers. Since the minor salivary glands are more concentrated in the palate, lesions originating from these glands often affect the soft and hard palate. These masses are typically solid or rubbery submucosal masses without ulceration, although occasional cases may exhibit surrounding ulceration [2].

The hard palate mucosa is tightly bound, giving the impression that it is fixed in nature. Pleomorphic adenoma tumours in the lips and buccal mucosa, on the other hand, are freely movable [3]. Diagnosis of pleomorphic adenoma is typically made through physical examination, histology, and cytology tests. These findings are often supported by radiographic results from Computed Tomography (CT) scans and MRI [Table/Fig-10,11] [2,4].

The median age is between 43 and 46, with a slight preference for women. The incidence is roughly 2-3.5 cases per 100,000 people in a given year. Physical examination, histology, and cytology tests are typically used to make the diagnosis of pleomorphic adenoma. Resorption pattern in the bone resulting from the lesion may appear cupped out. Pleomorphic adenomas typically do not invade the



[Table/Fig-10]: Dig representation of the presence of pleomorphic mass over hard palate [arrow].



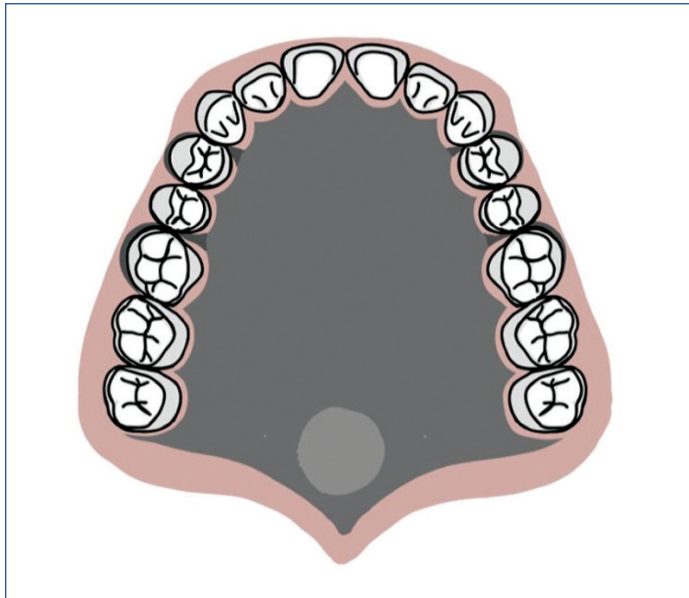
[Table/Fig-11]: Presence of a bare bone [green arrow] and lesion at the junction between hard and soft palate [blue arrow].

underlying bone [4]. From a histopathological standpoint, pleomorphic adenomas have mixed histology and consist of three components: epithelial, myoepithelial, and mesenchymal. There are three histologic types of pleomorphic adenomas: myxoid (80% stroma), cellular (myoepithelial predominance), and mixed (classic type).

According to Krolls SO and Boyers RC, tumours with a prominent myxoid component tend to recur more frequently. Myoepithelial cells were identified as plasmacytoid cells, and there was also a significant amount of squamous metaplasia in the form of keratin pearls [5]. If the overlying mucosa has ulcers that are not caused by trauma or a biopsy, malignancy should be suspected [1]. The case report mentioned an ulcerated site over the lesion, which was due to a local irritant causing trauma. The biopsy confirmed the absence of malignant cells.

The best course of treatment for palatal pleomorphic adenomas is wide surgical excision, which involves the periosteum, mucosa, and surrounding capsule. To prevent recurrence, curettage of the underlying bone is recommended following wide local excision [6]. Therefore, as part of the treatment strategy, curettage is always recommended after wide local excision.

Due to features like absence of encapsulation, mixing with normal tissue, and pseudopodia, a clear margin of 1 cm is preferred in such cases. Reconstruction of the palate can be challenging. In cases of cleft palate or when there is inadequate tissue for primary closure, a double flap palatoplasty is usually performed [7]. Considering the functional and aesthetic goals of reconstruction will help determine the most appropriate strategy for the patient. Since the hard palate can be allowed to granulate, soft-tissue abnormalities of the hard palate are not a concern [8]. In the case described above, the plan to close the fistula using a palatal plate obturator [Table/Fig-12] was chosen because it firmly adhere the palatal mucosa to the palatal surface and also serves as a scaffold for the posterior palatal surface.



[Table/Fig-12]: Dig representation of the palatal plate with two clasps over the premolar and molar.

Excision of a tumour from the palate often results in exposed denuded bone, and fabrication of a splint in such cases helps cover this denuded bone and acts as a scaffold for tissue growth [9]. The posterior palatal surface was de-epithelialised every two

weeks using a no. 11 blade to provide proper soft-tissue surface contact over the anterior region and a scaffold for the closure of the palatal fistula. Based on this, the palatal obturator was adjusted. At each appointment, the distal extension of the palatal obturator was checked to remove the pre-existing palatal defect [Table/Fig-12]. The patient was instructed to keep this plate on until the next appointment, after which it was modified again to offer sufficient tissue relief. This helped prevent the need for a second surgery, which would have had its own negative cost and physical impacts on the patient.

CONCLUSION(S)

It is challenging for a maxillofacial surgeon to surgically repair a palatal fistula that occurs after the surgical excision of a pleomorphic adenoma or any other tumour from the palate. The use of a simple palatal plate obturator not only addresses the healing of the uneven palatal soft-tissue surface but also assists in the closure of the palatal fistula, eliminating the need for a second surgical procedure following palatal tumour excision.

REFERENCES

- [1] Vuletić M, Kuna T, Bušić NJ, Gabrić D. Pleomorphic adenoma of the hard palate: Case report. *J Cancer Res Forecast*. 2018;1(1):1010.
- [2] Panda S, Nml M, Panda K. Pleomorphic adenoma of the soft palate: A case report with literature review. *Oncol J India*. 2018;2(1):13-15.
- [3] Arumugam P, Christopher PJ, Kumar S, Kengasubbiah S, Shenoy V. Pleomorphic adenoma of the palate: A case report. *Cureus*. 2019;11(3):e4308. Doi: 10.7759/cureus.4308.
- [4] Rahnema M, Orzędała-Kosze IU, Czupkało Ł, Łobacz M. Pleomorphic adenoma of the palate: A case report and review of the literature. *Contemp Oncol (Pozn)*. 2013;17(1):103-06. Doi: 10.5114/wo.2013.33438.
- [5] Rajan ST, Vandana S, Malathi N, Ravindran C, Thamizhchelvan H. Pleomorphic adenoma of a minor salivary gland- Report of a case. *Sri Ramachandra J Med*. 2015;8(2):20-22.
- [6] Lageju N. Pleomorphic adenoma presented as hard palatal mass: A case report. *Glob J Otolaryngol*. 2019;19(1):556004. Doi: 10.19080/GJO.2019.19.556004.
- [7] Koudounakis E, Vlastos IM, Parpounas K, Houlakis M. Two flap palatoplasty: Description of the surgical technique and reporting of results at a single center. *Ear Nose Throat J*. 2012;91(3):E33-37.
- [8] Rawson K, Kallalli BN, Gokul K, Singh A. Pleomorphic adenoma of the palate: A case report and review of a rare entity. *J Indian Acad Oral Med Radiol*. 2016;28(3):329-33.
- [9] Garde JB, Raikwar K, Kulkarni A. Pleomorphic adenoma of the hard palate. *J Int Clin Dent Res Organ*. 2010;2(2):92-94.

PARTICULARS OF CONTRIBUTORS:

1. Senior Assistant Professor, Department of Oral and Maxillofacial Surgery, Government Dental College, Chennai, Tamil Nadu, India.
2. Assistant Professor, Department of Surgical Oncology, Government Dental College, Chennai, Tamil Nadu, India.
3. Senior Consultant, Department of Oral and Maxillofacial Surgery, Apollo Dental Care, Chennai, Tamil Nadu, India.
4. Postgraduate Student, Department of Oral and Maxillofacial Surgery, Government Dental College, Chennai, Tamil Nadu, India.

NAME, ADDRESS, E-MAIL ID OF THE CORRESPONDING AUTHOR:

Senthil Kumar,
Dr. Senthil's Dental and Maxillofacial Care, No: 15/1, 15/2, Sannathi Street,
Villivakkam, Chennai-600049, Tamil Nadu, India.
E-mail: drsenthilkumaromfs@gmail.com

PLAGIARISM CHECKING METHODS: [Lain H et al.]

- Plagiarism X-checker: Aug 17, 2023
- Manual Googling: Oct 18, 2023
- iThenticate Software: Nov 11, 2023 (10%)

ETYMOLOGY: Author Origin

EMENDATIONS: 6

AUTHOR DECLARATION:

- Financial or Other Competing Interests: None
- Was informed consent obtained from the subjects involved in the study? Yes
- For any images presented appropriate consent has been obtained from the subjects. Yes

Date of Submission: **Aug 16, 2023**

Date of Peer Review: **Oct 09, 2023**

Date of Acceptance: **Nov 14, 2023**

Date of Publishing: **Jan 01, 2024**